




LETTER TO EDITOR

Role of a schematic figure of echocardiography in congenital heart diseases surgery: which method of reporting do you prefer?

Shiva Salehi¹ , Mahmood Hosseinzadeh Maleki² , Forod Salehi³ ✉

¹Medical Student, Birjand University of Medical Sciences, Faculty of Medical Sciences, Birjand, Iran

²MD, Associate Professor, Cardiovascular Diseases Research Center, Department of Cardiovascular Surgery, Mashhad University of Medical Sciences, Imam Reza Hospital, Mashhad, Iran

³Associate Professor, Department of Pediatric Cardiology, Birjand University of Medical Sciences, Vali-e-Asr Hospital, Birjand, Iran

Received: August 31, 2019

Revised: September 01, 2019

Accepted: September 25, 2019

Dear Editor

Congenital structural heart diseases are the most commonly reported fatal anomalies in children. These anatomical disorders can often be corrected surgically (1). Today, echocardiography is the best and most important diagnostic technique for anatomical abnormalities in the heart (2). In this method, anatomical details and hemodynamic examination of the heart can be determined using the ultrasound waves (sonography) (2).

Most pediatric cardiologists provide echocardiographic reports in the form of handwriting or typed text. This method of reporting is sometimes unable to understand the structural anomalies precisely and accurately for the final decision.

Nowadays, 2-dimensional echocardiography is acceptable for the accurate diagnosis of some structural heart abnormalities, even when there is no need to angiography for surgical planning (2). However, there is sometimes a dearth of matching echocardiographic finding with surgical reports. It

seems that adding a schematic figure based on echocardiography findings from viewpoint of pediatric cardiologist will help the congenital cardiac surgeon [Figure 1].

This proposed method of reporting will lead to the promotion of surgical treatment in congenital heart diseases.

The history of the use of schematic pictures for the better understanding of the subjects and diseases has been shown previously in the anatomical textbooks by famous painters, such as Leonardo da Vinci (3).

This suggestion shows that mapping can be viewed as a common language for better understanding of echocardiographic reports and more adaptation between comments of a pediatric cardiologist with designing congenital cardiac surgeon for more precise and complete treatment.

Conflicts of Interest

The authors declare that they have no conflict of interest.

©2020 Journal of Surgery and Trauma

Tel: +985632381203

Fax: +985632440488

Po Bax 97175-379

Email: jsurgery@bums.ac.ir

✉ Correspondence to:

Forod Salehi, Cardiovascular Diseases Research Center, Department of Pediatric Cardiology, Assistant Professor, Birjand University of Medical Sciences, Birjand, Iran;

Telephone Number: +989151630556

Email Address: hamidsalehi500@yahoo.com

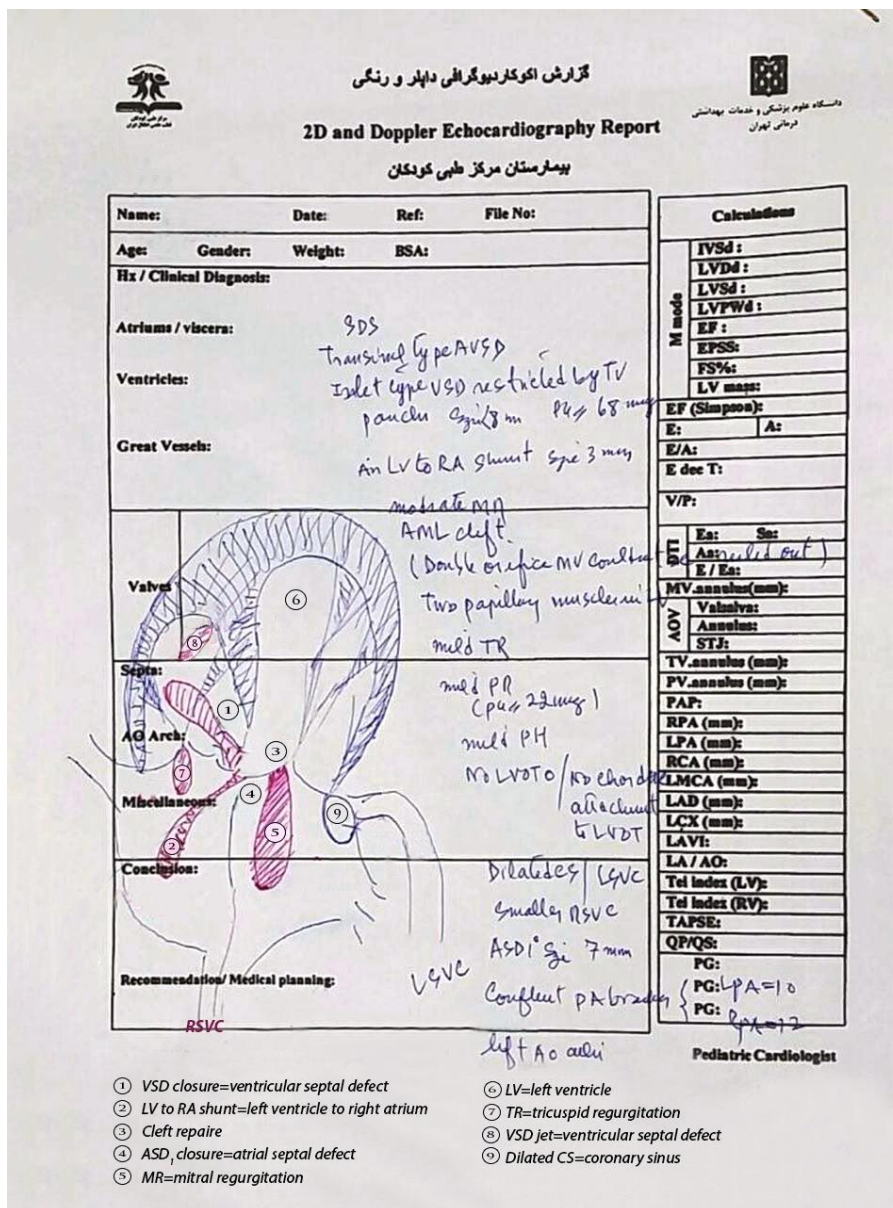


Figure 1: Echocardiographic report handwriting together with a schematic figure

References

- Jomefourjan S, Akbari A, Khosravi Bizhaem S, Salehi F. Comparison of quality of life of mothers with healthy children and mothers of children with congenital heart disease after open heart surgery. J Surg Trauma. 2017; 5(1):31-5.
- Kliegman RM, Behrman RE, Jenson HB, Stanton BM. Nelson textbook of pediatrics e-book. 20th ed. New York: Elsevier Health Sciences; 2016.
- Ike JD, Parker RM, Logan RA. Health literacy and the arts: exploring the intersection. Stud Health Technol Inform. 2017; 240:81-95. PMID: 28972511

[Downloaded from jsurgery.bums.ac.ir on 2024-04-24]

[DOI: 10.32592/jsurgery.2020.8.2.100]