



Case Report

A rare case report of Cushing's syndrome with concomitant papillary thyroid carcinoma and renal cysts in a 40-year-old woman

Maryam Rezaei¹ , Mahtab Abedi² 

¹ Assistant Professor of Endocrinology & Metabolism, Department of Internal Medicine, School of Medicine, Medical Toxicology & Drug Abuse Research Center, Birjand University of Medical Sciences, Birjand, Iran

² Medical Student, Student Research Committee, Birjand University of Medical Sciences, Birjand, Iran

Corresponding author:

Tel: +989151946123

Email: Dr.rezaei.maryam@gmail.com

Abstract

High levels of hormones secreted by the adrenal cortex lead to hypercortisolism, among whose complications is Cushing's syndrome. Thyroid carcinoma is one of the malignant neoplasms of the thyroid gland, the most common type of which is Papillary thyroid carcinoma (PTC), which is more common in women in the age group of 30-50 years. The course of the patient's symptoms ranges from asymptomatic to foreign body sensation, dysphagia, neck swelling, and voice change. The prognosis of patients with surgical procedures is good, and the five-year survival of patients is 90%. The concurrent incidence of several diseases in one person is a rare phenomenon. The reported article is the first very rare case of Cushing's syndrome, papillary thyroid carcinoma, and renal cysts.

Keywords: Cushing's Syndrome, Adrenal Adenoma, Papillary Thyroid Carcinoma

Citation: Rezaei M, Abedi M. A rare case report of Cushing's syndrome with concomitant papillary thyroid carcinoma and renal cysts in a 40-year-old woman. *J Surg Trauma*.2021; 9(1):37-40

Received: April 21, 2020

Revised: February 15, 2021

Accepted: February 15, 2021

Introduction

The adrenal glands are located on the kidneys. These glands have two parts: the cortex and the medulla. Benign tumors of the cortex are called adrenocortical adenomas, while medullary tumors lead to pheochromocytomas. An adrenal adenoma is a benign tumor that begins, in cases, to secrete more hormones than its basal amount when activated (1). High levels of hormones secreted from the adrenal cortex lead to hypercortisolism, including Cushing's syndrome. Common symptoms of this syndrome include central obesity, severe fatigue, muscle weakness, hypertension, hyperglycemia, bruising of various parts of the body following superficial trauma, and

purple striae. The rapid growth of body and facial hair is also reported in women with this syndrome. Surgery is the therapy considered for cortisol-secreting adenoma (2). Thyroid carcinoma is one of the malignant neoplasms of the thyroid gland, the most common type of which is papillary thyroid carcinoma (PTC). Malignant neoplasms originate from thyroid follicular cells and are more common in women aged 30-50 years.

The patient's symptoms can range from asymptomatic to foreign body sensation, dysphagia, swelling of the neck, and voice changes. Most patients have a good prognosis with surgery. The five-year survival rate of patients is reported as 90% (3).

Simple renal cysts are benign cysts containing fluid. The only indication is surgery, and the removal is associated with pain due to the pressure resulting from the size of the cyst and the presentation of symptoms such as hypertension. In an article by Chang et al., the prevalence of simple renal cysts was 10.7%. These cysts are often acquired and are associated with factors such as age, sex, race, and a history of smoking (4). In this article, we introduce the rare comorbidity of Cushing's syndrome, papillary thyroid microcarcinoma, and cysts of both kidneys.

Case

The patient is a middle-aged housewife, who presented with a complaint of progressive weight gain within six months after right kidney cyst surgery. The patient had gained so much weight that her ring was broken. The patient complained of functional shortness of breath, muscle weakness, and menstrual disorders. The patient's history mentioned pain in the flank because of which she had to walk in the ward to relieve it. The patient also complained of scaling lesions on her head and face.

The examination of the patient showed an obvious puffy face, proximal myopathy, hirsutism, trunk obesity, and mood disorders. During the examination, the patient complained of pain in her throat area. Her doctor examined the affected thyroid nodule and concurrently requested thyroid ultrasonography and FNA biopsy. According to the mentioned clinical signs with suspected hypocortisolism in the patient, a 24-hour urine cortisol test was performed, which was positive at 683 mcg / 24h.

A low-dose dexamethasone inhibitory test was performed again for the patient, which was positive. To find the origin of Cushing, the patient was measured for ACTH, which was smaller than 1 pg/ml and is more in favor of an adrenal origin of hypercortisolism. A CT scan of the abdomen and pelvis showed that an adrenal mass measuring 21 x 19 mm was on the right side (Figure 1).

Meanwhile, urinary metanephrine tests were performed for the patient, which was negative. The FNA results showed PTC. The patient was first nominated for right adrenalectomy, given adrenal adenoma mentioned in the reported pathology. During the examination, the patient was found to have a benign kidney cyst on the right side.

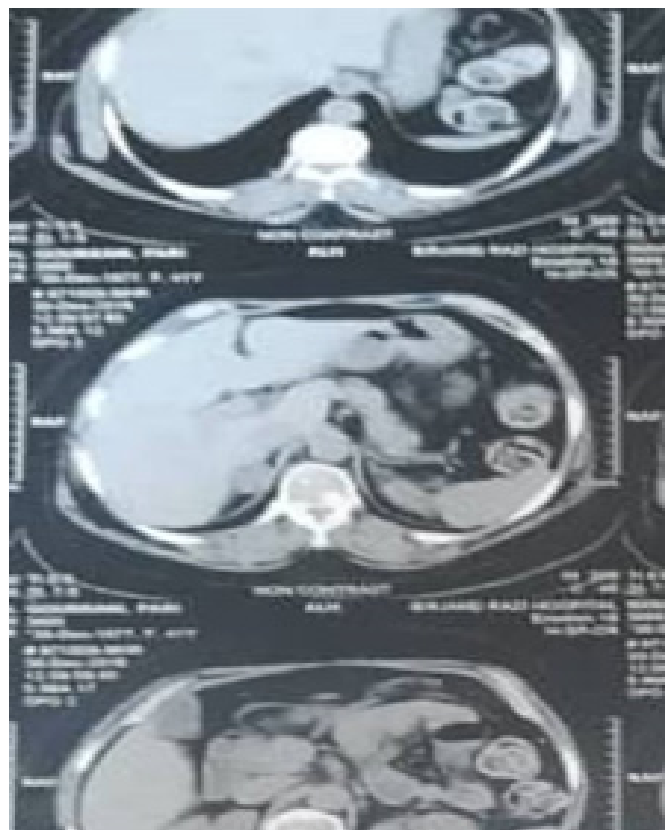


Figure 1. A mass measuring 21 x 19 mm is seen in the right adrenal position with enhancement after venous contrast.

During the follow-up, the patient's symptoms declined. The patient reported weight loss and recovery (Figure 2). She underwent subtotal thyroidectomy. Due to the small microPTC, she did not receive iodine therapy. The patient's only complaint was a sore throat that she was suffering from the onset. In the pathology report, thyroid microcarcinoma was mentioned in both papillary lobes. Patient biopsy showed well-differentiated papillary microcarcinoma measuring 0.5 x 0.3 cm without any vascular, neurological, or capsular invasion on the right thyroid lobe. On the left thyroid lobe, there was a well-differentiated

papillary microcarcinoma measuring 0.2 cm without any vascular, neurological, or capsular invasion. During the two-month follow-up, the patient's low back pain intensified. Upon request, ultrasonography reported a left kidney cyst (Figure 3). Scaling lesions on the patient's face were increased. The patient did not complain of any pain or discomfort. She was referred to a dermatologist for further treatment with a diagnosis of dermatitis.



Figure 2. Photo of the patient with Cushing's syndrome during follow-up

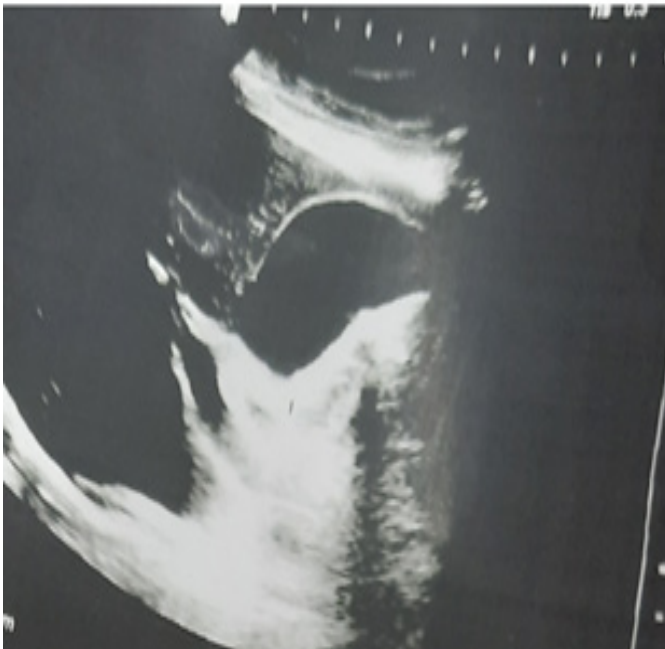

Figure 3. In the performed ultrasonography, the image of the mixed echo area containing solid and cystic areas can be seen in the upper bridge of the left kidney with dimensions of 26 x 37 mm.

Seborrheic was recommended for follow-up. The patient was referred to an oncologist for further examination of the kidney and was monitored during this period. The patient's left kidney cyst was reported to be simple; no medication was prescribed for the patient; and during this period, follow-up and outpatient referral were recommended.

Discussion

Cushing's syndrome is a rare disease with a prevalence of 15%, of which 10% is related to adrenal adenomas. Typical presentations involve diabetes, hypertension, mood disorders, and trunk obesity (2).

A 2014 study by Mezeh et al. reports the coincidence of Cushing's syndrome and follicular and medullary papillary carcinoma in a 72-year-old man who complained of nonspecific neck pain. The patient had a history of 100 pack/year smoking, diabetes, blood pressure, and COPD. The patient underwent a total thyroidectomy. After two months, he showed symptoms of Cushing's syndrome. The dexamethasone suppression test at doses of 1 mg and 8 mg in the patient showed unchanged cortisol levels, while the patient had suppressed ACTH. Urine metanephrine tests and 24-hour urinary cortisol levels were negative. CT scan showed a mass in the patient's left adrenal with dimensions of 2.5 x 2 cm, which indicated an atypical adenoma. The patient underwent adrenalectomy, and two months later, his symptoms subsided (5). Podetta et al. noted the separate and concomitant association of adrenal oncocytoma and papillary thyroid carcinoma, which did not metastasize and were marked with glucose in scans. The carcinomas were asymptomatic, and the patient had no complaints (6). However, there were no reports on the coexistence of kidney cysts in these two cases.

Conclusion

The reported case is rare and suggests an investigation of the role of genetic mutations in

the comorbidity of several diseases in a patient. The last point teaches to consider the adrenal glands in thyroid examinations.

Conflict of interest

The authors have no conflicts of interest to declare.

References

1. Mahmood E, Anastasopoulou C. Adrenal Adenoma. Treasure Island (FL): StatPearls Publishing; 2020. Available from: <https://www.ncbi.nlm.nih.gov/books/NBK539906>
2. Debono M, Newell-Price JD. Cushing's syndrome: where and how to find it. In *Cortisol Excess and Insufficiency*. Front Horm Res. Basel, Karger 2016;(46):15-27.
3. Serge G, Madhu R, Colleen V, Elin S, John A. R, Mikhail A, Alexander K, Papillary Thyroid Carcinoma Metastases Presenting as Ipsilateral Adrenal Mass and Renal Cyst. *Endocrinology and metabolism clinics of North America*. 1990;1;19(3):545-476.
4. Chang CC, Kuo JY, Chan WL, Chen KK, Chang LS. Prevalence and clinical characteristics of simple renal cyst. *J. Chin. Med. Assoc.* 2007;1;70(11):486-491.
5. Mazeh H, Orlev A, Mizrahi I, Gross DJ, Freund HR. Concurrent Medullary, Papillary, and Follicular Thyroid Carcinomas and Simultaneous Cushing's Syndrome. *Eur Thyroid J*. 2015;(4):65–68.
6. Podetta M, Pusztaszeri M, Toso C, Procopiou M, Triponez F, Sadowski SM. Oncocytic adrenocortical neoplasm with concomitant papillary thyroid cancer. *Front. Endocrinol.* 2018;8:384.