



Case Report

## Persistent ventricular dysrhythmia follow in general anesthesia for tonsillectomy

Mahmood Hosseinzadeh Maleki<sup>1</sup>, Mohsen Yaghoobi<sup>2</sup>, Feisal Rahimpour<sup>3</sup>

<sup>1</sup> Associated Professor, Department of Cardiac Surgery, Imam Reza Hospital, Mashhad University of Medical Sciences, Mashhad, Iran

<sup>2</sup> Department of Extra-Corporeal Circulation, Razavi Hospital, Imam Reza International University of Medical Sciences, Mashhad, Iran

<sup>3</sup> Pediatric Cardiologist, Imam Reza Hospital, Mashhad University of Medical Sciences, Mashhad, Iran

**Corresponding Author:**

Tel: +989133815233

Email: [rahimpourf1@mums.ac.ir](mailto:rahimpourf1@mums.ac.ir)

### Abstract

Arrhythmia is one of the most common cardiovascular complications during anesthesia. Its occurrence has been reported in 70% of patients undergoing general anesthesia for various surgical procedures. Premature ventricular complex usually follows a benign course and shows a good response to medical therapy. In this study, a case was reported that did not respond to the usual treatment of ventricular tachycardia and frequent premature ventricular complex.

**Keywords:** Ventricular Premature Complexes, Tonsillectomy, Flecainide, Arrhythmia

**Citation:** Hosseinzadeh Maleki M, Yaghoobi M, Rahimpour F. Persistent ventricular dysrhythmia follow in general anesthesia for tonsillectomy. J Surg Trauma. 2021; 9(3):131-134.

*Received: August 3, 2021*

*Revised: August 14, 2021*

*Accepted: August 15, 2021*

### Introduction

Arrhythmia is one of the most common cardiovascular complications during anesthesia. Its occurrence has been reported in 70% of patients undergoing general anesthesia for various surgical procedures(1). Patients undergoing cardiac surgeries are more vulnerable to arrhythmia. Intraoperative arrhythmia and cardiac arrhythmias are the most frequent preoperative cardiovascular abnormalities in patients undergoing both cardiac and non-cardiac surgery(1).

The incidence has been reported to vary from 16.3% to 61.7% with intermittent electrocardiographic (ECG) monitoring and 3% to 89% with continuous Holter monitoring in patients undergoing non-

cardiac surgery. However, patients undergoing cardiac surgery are more prone to develop arrhythmia with a reported incidence of more than 90% (2,3). Direct surgical manipulation and procedures related to cardiopulmonary bypass may precipitate arrhythmia. Dental surgery is often associated with arrhythmias due to profound frequent stimulation of the autonomic nervous system. Severe bradycardia commonly occurs due to the oculocardiac reflex during strabismus surgery, particularly in neonates and children.

The direct or indirect stimulation of vagal tone in surgical procedures produces bradycardia or block. Various factors associated with anesthesia influence the occurrence of arrhythmia. Anesthetic agents

themselves are arrhythmogenic. The evaluation of the influence of anesthetic agents on ventricular repolarization is important since the agents may cause malignant ventricular arrhythmias, such as torsade de pointes(6).Anesthetic agents and drug-induced arrhythmia prolonged ventricular repolarization are associated with torsade de pointes and sudden cardiac arrest(4).

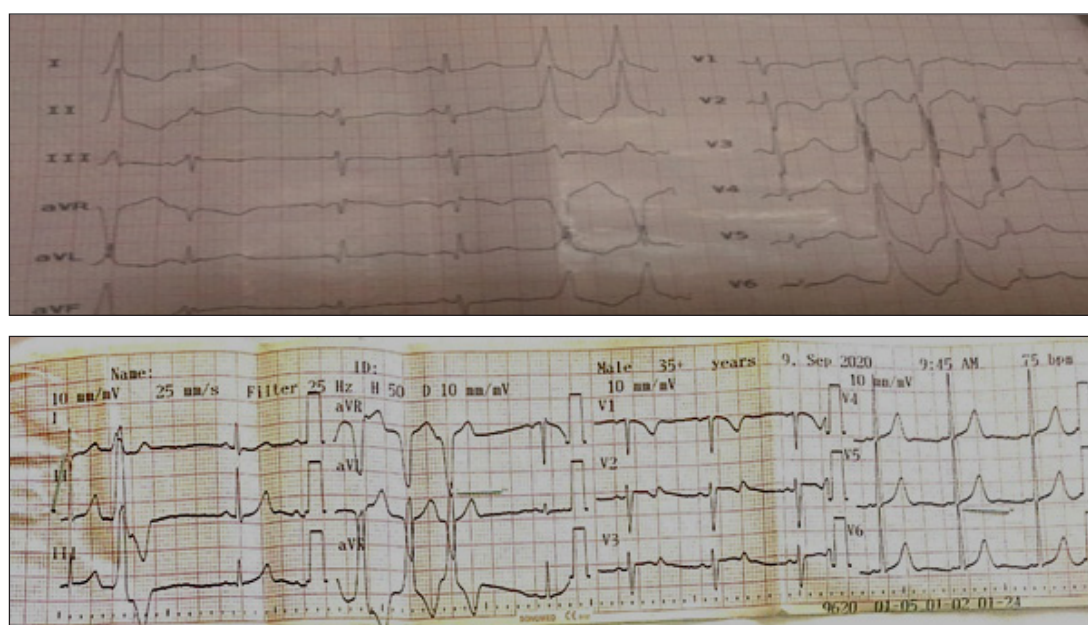
Medical treatment for premature ventricular complex (PVC) in patients with structurally normal heart is usually successful in the suppression of symptoms, and deterioration of ventricular function seldom occurs. However, the high burden of PVC might be refractory to anti-arrhythmic medications and sometimes results in progression into PVC-mediated dilated cardiomyopathy (5).

In this study, a case was reported that did not respond to the usual treatment of ventricular tachycardia (VT) and frequent PVCs.

## Case

A 10-year-old girl developed ventricular tachycardia (VT) during tonsillectomy; she had no history of palpitation, chest pain, and syncope before surgery and her VT did not respond to the infusion of lidocaine; therefore, orally propranolol was administered. After the start of propranolol, VT was stopped, however, PVC sccontinued.

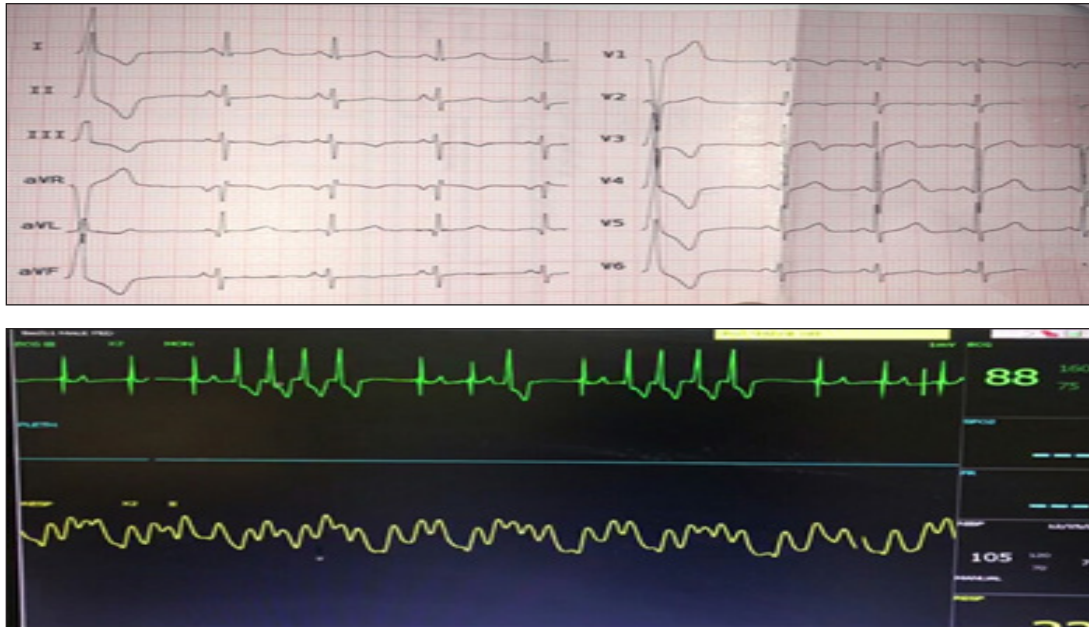She received Isoflurane (Forane), midazolam, atracurium, and propofol during anesthesia; moreover, she took dexamethasone and a drop of phenylephrine to make the bleeding reduced after tonsillectomy. After surgery, lidocaine was continued with propranolol; never the less, she had couplet PVCs and episodes of none sustained VT (Figures 1, 2, and 3). Electrocardiogram showed normal sinus rhythm and frequent isolated PVC, whose origin was suspected to be in the left ventricular outflow tract (LVOT) right coronary cusp (RCC) (Figure 1). The review of surface ECG showed PVC origin at LVOT RCC area with inferior axis, left bundle branch block QRS morphology, V3 QRS transition, earlier QRS transition at PVC than that at sinus rhythm, positive QRS vector in lead I, transition ratio at V2 as 1.2, R-wave duration index as 0.5, and R/S amplitude index as 0.7 (Figures1 and 2). Holter examination demonstrated the total PVC burden as 11%. The results of the echocardiogram revealed normal heart function and normal chamber size. However, the symptoms were not relieved and frequent PVCs were still observed on a 12-lead ECG after 1week of medication. Nonetheless, the total burden of PVC was not diminished on Holter examination. Chest discomfort gradually aggravated during medical treatment.



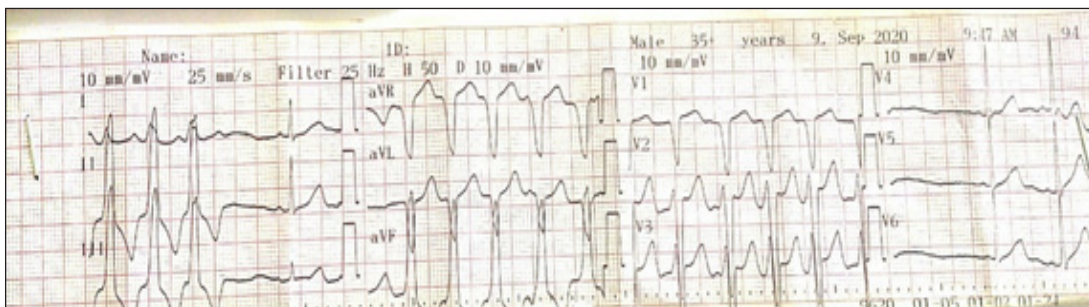
**Figure 1.** 12-Lead electrocardiogram indicating couplet premature ventricular complex originated from the left ventricular outflow tract right coronary cusp

Since PVC was refractory to first-line medical treatment, it was decided to change propranolol to flecainide 3mg/kg/day in 3 doses, which resulted in the disappearance of PVC after the start of flecainide (Figure 4). The patient was discharged with only a flecainide prescription. One week later,

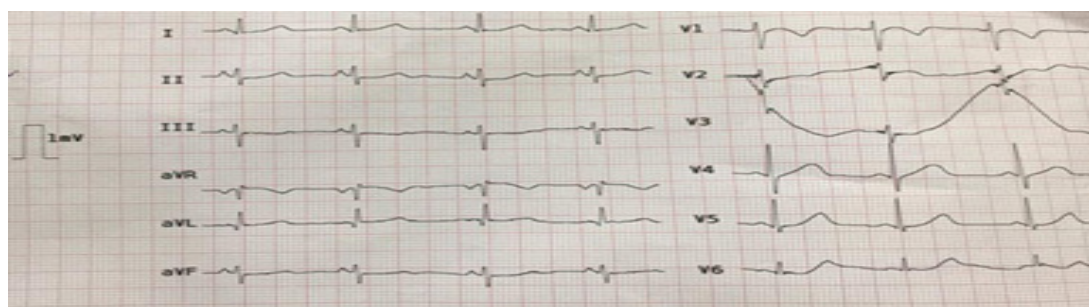
the patient recovered from disabling palpitations and chest discomfort. All medical treatments were then discontinued. Follow-up Holter examination performed 6 months post-discharge revealed no PVC, and echocardiogram demonstrated normal ventricular systolic function and dimensions.



**Figure 2.** 12-lead electrocardiogram indicating single premature ventricular complex originated from the left ventricular outflow tract right coronary cusp



**Figure 3.** Episodes of none sustained ventricular tachycardia



**Figure 4.** 12-Lead electrocardiogram showing normal sinus rhythm without and premature ventricular complex



## Discussion

The evaluation of the influence of anesthetic agents on ventricular repolarization is important due to the fact that the agents may cause malignant ventricular arrhythmias(6).

Anesthetic agents and drug-induced arrhythmia are associated with torsade de pointes and sudden cardiac arrest(4). Accelerated idioventricular rhythm is likely resulted from the administration of isoflurane to presenting hypoxemia; a condition that exacerbates the risk of arrhythmia. Proper management of this abnormal rhythm is crucial as inappropriate treatments may worsen the arrhythmia(2).

The incidence of arrhythmias following the administration of midazolam is rare; none the less, arrhythmias have been reported as a result of administering neostigmine, especially in cases of underlying conduction impairment(3). Propofol has an inhibitory effect on ventricular arrhythmias(6). Phenylephrine increases ventricular arrhythmia in humans presumably by activating the reflex of the baroreceptors decreases sympathetic and/or increases parasympathetic cardiac efferent effects(7).

In this patient, three arrhythmia-prone medications, isoflurane, neostigmine, and phenylephrine, were used simultaneously that might justify the development of persistent ventricular arrhythmia in this case, which continues even after the discontinuation of anesthesia and resistant to routine treatment.

## Conclusion

It is recommended that arrhythmogenic medications not be used simultaneously in surgical procedures requiring general anesthesia. Therefore, for arrhythmia in these conditions, it is recommended to administer the treatment of ventricular arrhythmia more severely and for a longer time.

## Conflicts of Interest

The authors declare that there is no conflict of interest.

## References:

1. Kwon CH, Kim SH. Intraoperative management of critical arrhythmia. *Korean J Anesthesiol.* 2017;70(2):120-126.
2. Peña-Cadahia C, Manso-Díaz G, Santiago-Llorente I, Villalba-Orero M. Accelerated Idioventricular rhythm associated with Isoflurane Administration in a Foal: a case report. *J Equine Vet Sci.* 2019; 80:64-68.
3. Kadoya T, Seto A, Aoyama K, Takenaka I. Development of rapid atrial fibrillation with a wide QRS complex after neostigmine in a patient with intermittent Wolff-Parkinson-White syndrome *Br J Anaesth.* 1999;83(5):815-818.
4. Staikou C, Stamelos M, Stavroulakis E. Impact of anaesthetic drugs and adjuvants on ECG markers of torsadogenicity. *Br J Anaesth.* 2014;122(2):217-230.
5. Penela D, Fernandez-Armenta J, Aguinaga L, Tercedor L, Ordonez A, Bisbal F, Acosta J, Rossi L, Borrás R, Doltra A, Ortiz-Perez JT, Bosch X, Perea RJ, Prat-Gonzalez S, Soto-Iglesias D, Tolosana JM, Vassanelli F, Cabrera M, Linhart M, Martinez M, Mont L, Berruezo A. Clinical recognition of pure premature ventricular complex-induced cardiomyopathy at presentation. *Heart Rhythm.* 2017; 14(12): 1864-1870.
6. Jessica E. Burjorjee MD, Brian Milne FRCP. Propofol for electrical storm; a case report of cardioversion and suppression of ventricular tachycardia by propofol. *CAN J ANESTH.* 2002; 49(9): 973–977.
7. Mitrani RD, Miles WM, Klein LS, Zipes DP. Phenylephrine increases T wave shock energy required to induce ventricular fibrillation. *J Cardiovasc Electrophysiol.* 1998;9(1):34-40.