

CASE REPORT

Childhood Inguinal Mass: Common Complain, Several Causes, Report of A Case And Review of Literature

Reza Shojaeian¹, Mehran Hiradfar¹✉

¹ Pediatric surgeon, Assistant Professor, Mashhad University of Medical Sciences, Sarvar Children Hospital, Mashhad, Iran.

Received: 3 October 2013 Revised: 4 February 2014 Accepted: 27 April 2014

Abstract

Inguinal mass is a common clinical finding or even symptom in childhood while the most common diagnosis is inguinal hernia that may proceed with prompt surgical but there are a vast variety of different entities that may manifest as an inguinal mass and in some instances, surgical approach is not indicated or may need further preoperative assessments to determine a correct therapeutic plan. In this article, we discuss about an example of unusual case of extrarenal Wilms tumor in inguinal region which was presented as an inguinal mass and also review differential diagnosis for childhood inguinal mass.

Key Words: Inguinal Mass; Case Report; Childhood

Introduction

As far as inguinal region mass may encountered frequently in children, the most common diagnosis is inguinal hernia. The diagnosis of inguinal hernia may make on parents' history of a typical bulging in groin and when the diagnosis made, surgical intervention always would be planned as soon as possible. Any further investigation is needed in a case of inguinal hernia. But this may not be so straight forward in some cases. There are a vast variety of different entities that may manifest as an inguinal mass and in some instances, surgical approach is not indicated or may need further preoperative assessments to determine a correct therapeutic plan [1].

Cases

A 9-years old healthy girl was visited in a general hospital with initial symptom of a right inguinal bulging which was first noticed by her mother. In the first visit, herniotomy was planned by a general surgeon according to the presence of an inguinal mass. But after exploration of inguinal region, surgeon encountered a solid mass that wasn't compatible with hernia. Intraoperative diagnosis was lymphadenitis so an excisional biopsy was performed.

Histopathological findings showed typical triphasic pattern of epithelial, blastemal and stromal elements, characteristic of Wilms'tumor.

The patient was referred to our center with primary diagnosis of Wilms tumor with inguinal node metastasis.



✉ Correspondence to:

Mehran Hiradfar, pediatric surgeon Assistant Professor Mashhad university of medical sciences - - Sarvar Children Hospital ;
Telephone Number: 0985117284448
Email Address: mhiradfar@gmail.com

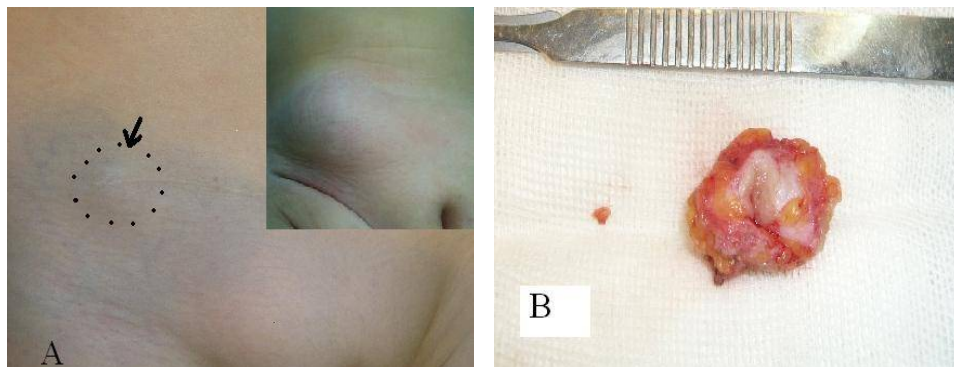


Figure 1: A- Right inguinal mass in the first visit (up) and after recurrence (down). B-Enbloc resection of recurrent inguinal mass

Final diagnosis:

Para-clinical evaluations were done but both kidneys were intact. Chest x-ray was normal and kidneys, lungs and mediastinum were also normal in CT scan. Urine analysis and blood cell and erythrocytes and liver function tests were in normal range. According to imaging and further evaluations, there wasn't any primary tumor site in kidneys so the

final diagnosis was extra renal Wilms tumor. Chemotherapy with vincristine, dactinomycin and Doxorubicin was administrated to complete the treatment course.

Hospital course:

During follow up, a persistent right superficial groin mass was detected after six month. As her mother declared a gradual outgrowing of the mass, patient was referred to our department of pediatric surgery for further investigations according to this asymptomatic recurrent inguinal mass. It was 2×2cm solid, firm, non-tender mass in physical examination [Figure 1-A]. Ultrasound studies confirmed a solid mass in right inguinal region besides normal genitourinary upper system and any other mass and lymph nodes were noticed in retroperitoneum and pelvis. All other paraclinical evaluations were normal so local recurrence of Wilms tumor was diagnosed. Inguinal exploration was planned and enbloc removal of mass with safe margins was performed [Figure 1-B].

Microscopic evaluation of the specimen revealed composition of sheets which were randomly arranged and tightly packed. Small blue cells arranged in serpiginous aggregates (blastemal component), sharply circumscribed by focal

spindling and intervening collagenous bundles apart from the surrounding stromal elements. There were also few small tubules lined by primitive cuboidal cells and small area of nephrogenic rest at periphery of the tumoral mass pathological features suggested Wilms tumor. Immunohistochemical study showed strong nuclear positivity for WT1 in blastemal cells. Final diagnosis according to above data was compatible with recurrent extra renal Wilms' tumor with favorable histology.

Discussion

Inguinal mass is a common complain in pediatrics that is mainly due to inguinal hernia. Other common diseases that may present as an inguinal mass include lymphadenitis and lymphadenopathy or ectopic gonad in cryptorchidism or entrapped ovary [1]. Several other causes are discussed for a groin mass that are summarized in Table 1 as we have searched in English published literature.

A groin mass may also encountered in a patient after a previous herniotomy. In this case, a recurrent inguinal hernia may come to mind first. Some other common probable diagnoses are reactive lymphadenopathy, lymphadenitis or local abscess and acquired cryptorchidism. Some other uncommon entities are listed at the end of table 1.

In this article, a case of extra renal Wilms tumor in inguinal region is reported which was presented as an inguinal mass.

Nephroblastoma is the most common primary malignant tumor of kidney in children [2]. Definitive diagnosis in Wilms tumor is almost

Table 1: Different diagnosis for pediatric groin mass that are reported in English literature between 2007-2011

Article	Presentation	Final diagnosis
Alsaif A et al (2011) [9]	Irreducible inguinal hernia	Mesenteric fibromatosis
Ho CC et al (2011) [10]	Inguinoscrotal mass	Complication of ventriculoperitoneal shunt
Mayor R et al (2011) [11]	Painful inguinal mass	Acute appendicitis in patent processus vaginalis
Hayes BD et al (2011) [12]	inguinal mass	Intranodal hybrid benign nerves hit tumor
Lazarus J et al (2011) [13]	Inguinal bulging	Abdominal tuberculosis
Parada Arias M. et al (2010) [14]	Inguinal mass	Dermoid cyst of spermatic cord
Arabi S et al (2010) [15]	Irreducible inguinal mass	Mesothelial cyst
Nizza D et al (2010) [16]	Subcutaneous groin mass	Blastic plasmacytoid dendritic cell neoplasm
Savas M et al (2010) [17]	Inguinal mass	Polyorchidism
Cooke A et al (2009) [18]	Left inguinal mass	Ectopic nephrogenic rest
Oh JT et al (2009) [19]	Inguinal mass	Vulvar lipoma
Hennelly K et al (2009) [20]	Inguinal mass	Entrapped ovary
Vaos G et al (2009) [21]	Inguinal mass and UDT	Mesothelial cyst of spermatic cord
Ganesan P et al (2008) [22]	Inguinal mass	Alveolar rhabdomyosarcoma
Melloni P et al (2008) [23]	Lower left groin mass	Atypical inguinal malignant peripheral nerve sheath tumor
Yurtcu M et al (2007) [24]	Inguinoscrotal mass	True hermaphroditism
Barroca H et al (2007)[25]	Inguinoscrotal mass	Testicular juvenile granulosa cell tumor

always made after surgical intervention [3]. Extra renal Wilms tumor is rare, and the occurrence of the extra renal nephroblastoma without the involvement of kidney is extremely uncommon [4]. The most common site of extra renal wilms tumor is retroperitoneal and then inguinal area [5]. Mediastinum, chest wall, colon, adrenal gland, and reproductive organs are other reported sites of extra renal willms tumor [6-8]. So this case was an unusual diagnosis for a groin mass as extra renal nephroblastoma that was misdiagnosed first. The most important factors associated with local recurrence are high tumor stage, unfavorable histology, tumor rupture during operation or inadequate resection. Unexpected situation during an operation that is assumed to be a simple herniotomy may increase the complications and inadequate or incorrect preoperative parents' informing may lead to serious problems.

Conclusions

According to broad spectrum of differential diagnoses in a child with inguinal mass that may even be a neoplastic lesion, we suggest a meticulous physical examinations and further paraclinical evaluations especially in patients with unusual presentation.

References

- Hennelly K, Shannon M. A 3-Month-Old Female with an Inguinal Mass. *The Journal of emergency medicine*. 2011; 40(1): 33-6.
- Spreafico F, Bellani FF. Wilms' tumor: past, present and (possibly) future. *Expert Review of Anticancer Therapy*. 2006; 6(2): 249-58.
- Arda IS, Tüzün M, Demirhan B, Sevmis S, Hicsönmez A. Lumbosacral extrarenal Wilms' tumour: a case report and literature review. *European Journal of Pediatrics*. 2001; 160(10): 617-9.
- Maeda T, Tateishi U, Hasegawa T, Fujimoto H, Arai Y, Sugimura K. MRI of primary prostatic Wilms' tumor in a young adult. *American Journal of Roentgenology*. 2006; 187(4): W415-7.
- Apoznanski W, Sawicz-Birkowska K, Pietras W, Dorobisz U, Syzdelko T. Extrarenal Wilms tumor. *European Journal of Pediatric Surgery*. 2005; 15(1): 53-5.
- McAlpine J, Azodi M, O'Malley D, Kelly M, Golenewsky G, Martel M, et al. Extrarenal Wilms' tumor of the uterine corpus. *Gynecologic Oncology*. 2005; 96(3): 892-6.
- Oner U U, Tokar B, Açikalin MF, İlhan H, Tel N. Wilms' tumor of the ovary: A case report *Journal of Pediatric Surgery*. 2002; 37(1): 127-9.
- Teerthanath S. Extrarenal nephroblastoma. *Journal of Laboratory Physicians*. 2011; 13(1): 59-60.
- Alsaif FA. Mesenteric fibromatosis presenting as an irreducible inguinal hernia. *Journal of Saudi Gastroenterology*. 2011; 17(5): 357-9.

10. Ho CC, Jamaludin WJ, Goh EH, Singam P, Zainuddin ZM. Scrotal mass: a rare complication of ventriculoperitoneal shunt. *Acta Medica (Hradec Kralove)*. 2011; 54(2): 81-2.
11. Mayor R, Saenz NC, Kanegaye JT. Acute appendicitis presenting with a painful inguinal mass: complication related to patent processus vaginalis and testicular maldescent. *Pediatric Emergency Care*. 2011; 27(5): 414-6.
12. Hayes BD, O'Sullivan MJ. Intranodal hybrid benign nerve sheath tumor. *Pediatric and Developmental Pathology* 2011; 14(4): 313-7.
13. Lazarus J, Pillay K. Abdominal tuberculosis presenting as an inguinal hernia in a child. *Urology*. 2011; 77(6): 1470-1.
14. Prada-Arias M, Ortiz-Rey JA, Fernández-Eire P, Montero-Sánchez M, Lema-Carril A, Segade-Andrade R. Dermoid cyst of the spermatic cord in children. *Journal of Pediatric Surgery*. 2010; 45(10): 2058-60.
15. Aarabi S, Drugas G, Avansino JR. Mesothelial cyst presenting as an irreducible inguinal mass. *Journal of Pediatric Surgery*. 2010; 45(6): e19-21.
16. Nizza D, Simoneaux SF. Blastic plasmacytoid dendritic cell neoplasm presenting as a subcutaneous mass in an 8-year-old boy. *Pediatric Radiology*. 2010; 40(11): S40-2.
17. Savas M, Yeni E, Ciftci H, Cece H, Topal U, Utangac MM. Polyorchidism: a three-case report and review of the literature. *Andrologia*. 2010; 42(1): 57-61.
18. Cooke A, Deshpande AV, La Hei ER, Kellie S, Arbuckle S, Cummins G. Ectopic nephrogenic rests in children: the clinicosurgical implications. *Journal of Pediatric Surgery*. 2009; 44(12): e13-6.
19. Oh JT, Choi SH, Ahn SG, Kim MJ, Yang WI, Han SJ. Vulvar lipomas in children: an analysis of 7 cases. *Journal of Pediatric Surgery*. 2009; 44(10): 1920-3.
20. Hennelly K, Shannon M. A 3-month-old female with an inguinal mass. *Journal of Emergency Medicine*. 2011; 40(1): 33-6.
21. Vaos G, Zavras N, Velaoras K, Ereikat K. Muesothelial cyst of the spermatic cord as a cause of acquired cryptorchidism. *Hernia*. 2009; 13(4): 439-41.
22. Ganesan P, Thulkar S, Rajan A, Bakhshi S. Solid variant of alveolar rhabdomyosarcoma mimicking non-Hodgkin lymphoma: case report and review of literature. *Journal of Pediatric Hematology/Oncology*. 2008; 30(10): 772-4.
23. Melloni P, Olsina G, Oliva E, Garcia-Continente G, Veintemillas M, Garcia-Hernandez F. Atypical inguinal malignant peripheral nerve sheath tumour with arteriovenous fistula of the left femoral nerve in a child. *Pediatric Radiology*. 2008 Jul; 38(7): 801-5.
24. Yurtcu M, Aydogdu B, Avunduk MC, Günel E. A rare presentation of true hermaphroditism: an abnormal inguinoscrotal mass. *Neuroendocrinology Letters*. 2007; 28(5): 547-8.
25. Barroca H, Gil-da-Costa MJ, Mariz C. Testicular juvenile granulosa cell tumor: a case report. *Acta cytological*. 2007; 51(4): 634-6.