



Original Article

Role of laparoscopy in the management of incisional hernia: A comparative study from a medical school

Yaqoob Hassan¹  , Ajaz Ahmad Rather² , Sanaan Ajaz Rather³ 

¹ MBBS,MS, Senior Resident, Department of General and Minimal Access Surgery, SKIMS Medical College, Srinagar, Kashmir, India

² MBBS,MS, FRCS,FICS, Professor and Head, Department of General and Minimal Access Surgery, SKIMS Medical College, Srinagar, Kashmir, India

³ MBBS, Resident, SKIMS Medical College, Srinagar, Kashmir, India

Corresponding Author:

Tel: +917006563122

Email: dryaqoobwani@gmail.com

Abstract

Introduction: The conventional open repair of incisional hernia requires extensive dissection. The applicability and superiority of the laparoscopy have been evolving over the last few years. The aim of our study was to compare the surgical outcomes of laparoscopic versus open mesh repair in the management of incisional hernia.

Methods: This prospective comparative study was carried out in the SKIMS Medical College, Hospital, over a period of 5 years. The total of 62 subjects with non-complicated primary incisional hernias between 15-65 years of age were included. Polypropylene mesh in open surgery and Proceed prosthesis (ePTFE Mesh) in laparoscopy was used for repair. After hospital discharge, the patients were attached to the Out-Patient Department for follow-up. The data was collected and analyzed.

Result: The maximum numbers of patients (41.9%) were in the age group of 36-45 years with a male to female ratio of 0.55. 32 patients were operated by conventional open mesh repair and 30 patients underwent intra-abdominal preperitoneal on-lay mesh repair. 30.6% of female patients had history of a lower abdominal caesarean section followed by hysterectomy (17.7%). The majority of males had history of exploratory laparotomy secondary to trauma (17.7%) or peptic ulcer perforation (12.9%). The difference in mean operative time of laparoscopic technique (87 ± 8.62 minutes) and open repair (96.56 ± 9.31 minutes) was statistically significant (p -value of 0.05). The difference between the mean duration of hospital stay in the open repair (5.58 ± 1.69 days) and the laparoscopy (3.36 ± 1.17 days) was statistically significant. None of our patients expired during the study period.

Conclusion: Laparoscopic management of incisional hernia is a promising alternative to conventional repair with encouraging results. In our study, it was found that laparoscopic repair is safe and resulted in lesser operative time, fewer complications, shorter hospital stay and early return to activity.

Keywords: Incisional Hernia, Laparoscopy, Prevention, Prosthesis

Citation: Hassan Y, Rather A.A, Rather S.A. Role of laparoscopy in the management of incisional hernia: A comparative study from a medical school. *J Surg Trauma*.2022;10(1):25-33.

Received: September 1, 2021

Revised: December 30, 2021

Accepted: January 2, 2022

Introduction

Incisional hernia occurs at the site of previous incisional scars in which abdominal fascia has been divided. It occurs in up to 10-50% of laparotomy and 1-5% of laparoscopic port site incisions (1). There are number of factors responsible for the development of an incisional hernia. These factors can be related to the patient (e.g., malnutrition, patient on immunosuppressive drugs, uremia, diabetes, and anemia), surgical technique (e.g., type of incisions, suture material, incision and technique of close), and wound (e.g., infection, hematoma, and foreign body). Post-operative surgical site infections increase the rate of incisional hernia up to 23% (2-3). Thus, incisional hernia is a common surgical problem encountered in day-to-day practice. The patient of incisional hernia may be asymptomatic, symptomatic, or aesthetically distressing. Incisional hernias should be repaired because they can become complicated, such as obstruction, strangulation, increase in size, and may become difficult to repair with time.

The myriads of methods have been developed for the repair of incisional hernia. Several trials have been performed to compare primary versus mesh repair of incisional hernia. Primary repair by simple suture technique is associated with high reported recurrence rates. The recurrence rate is estimated at 63% after suture repair of incisional hernia 10-years after surgery (4). Moreover, recurrence rates of 50% after suture repair of an incisional hernia were reproduced in several other studies (5-6).

Most incisional hernias are repaired with the use of prosthetic meshes via an open or laparoscopic approach. Mesh repair has become the standard technique of elective management of incisional hernia. The mesh can be placed in subcutaneous space superficial to fascial defects (on-lay repair), bridging the gap between the defect edges or within the abdominal wall musculoaponeurotic layer (interlay) and deep to the fascial intra or preperitoneal defects (underlay).

Though the open mesh repair of incisional hernia is being conducted extensively, minimally invasive surgical methods have been influencing since

the last decade. The minimal invasive surgical techniques result in shorter hospital stay and lesser complications compared to conventional open repair (7). Less incidence of wound infection, early return of bowel movements, and faster resumption of normal activities, favour laparoscopic incisional and ventral hernia repair (8-12). The study aimed to compare the surgical outcomes of laparoscopic versus open mesh repair in the management of incisional hernia.

Material and Methods

This prospective comparative study between the open and laparoscopic repair of incisional hernia was conducted in SKIMS Medical College, Srinagar, from January 2015 to January 2020. After obtaining proper ethical clearance from the Institutional Ethical Committee (SKIMS MCH/IEC/2015-88), total of 62 subjects (Kashmiri residents) were included in our study.

All patients with non-complicated primary incisional hernias aged 15-65 years were included in the study. The patients with erythema, skin discoloration, severe pain and very tender hernia, symptoms of bowel obstruction, very large defects (more than 10cm), and extensive intra-abdominal adhesions and those operated in an emergency set-up were excluded from the research. Pre-operatively, patients were thoroughly evaluated (including complete history taking and clinical examination) and were subjected to baseline investigations. The goals of the study and data usage were explained to the participants as per the ethical guidelines of Helsinki and proper informed consent was secured. The patients were matched for age, gender, operation time, postoperative complications, and hospital stay. All the operations were performed under general anesthesia. The patients were administered prophylactic 1 g of intravenous Ceftriaxone during the induction of anesthesia. After discharge, all the subjects were invited for follow-up at 1-week, 4-weeks, 6 months, and yearly thereafter. In open hernia repair, after excising the previous surgical scar, the hernia sac was dissected unto the margins of the hernia ring. The hernia sac was

opened and contents were reduced after lysis of the adhesions, followed by the closure of the peritoneum with running 2-0 Vicryl sutures. The facial defect was closed with a monofilament suture. Skin flaps were mobilized and adequate size polypropylene mesh was used in all the cases covering 5cm all around the defect. The mesh was placed in subcutaneous space superficial to fascial defects (on-lay repair). Skin was closed after insertion of 14F closed suction drain in subcutaneous plane.

In laparoscopy, we used closed method of pneumoperitoneum creation via Veress needle to achieve the intra-abdominal pressure of 12-15 mm Hg. The umbilicus was employed as the primary port site since it is a convenient and safe point of insertion. For patients with midline scar, pneumoperitoneum and the primary port was created away from the

midline. The commonest applied approach was Palmer's point, 3cm below the left costal margin in the midclavicular line.

All the secondary trocars were inserted under direct vision to avoid damage to the bowel, vessel, or bladder. The total of three ports was used, including 10-mm optical and two 5-mm working ports. We used 30-degree camera during surgery for a better panoramic view.

Meticulous hernia reduction and adhesiolysis using harmonic scalpel was performed taking due care to avoid any bowel injury. Proceed(ePTFE Mesh) prosthesis was used in all laparoscopic cases and anchored in place with sutures and tackers with a minimum of 5 cm overlap past the edge of defect on all sides. 10-mm port was always closed with 2-0 Vicryl at the end of surgery (Figure 1).

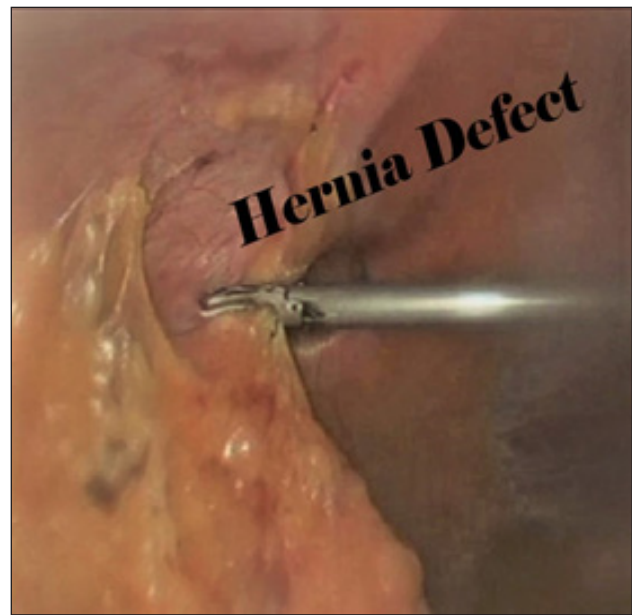


Figure 1. Incisional hernia defect and laparoscopic mesh fixation

Results

Total of 62 patients were included in our study. The youngest patient was the 22-year-old male and oldest 64-year-old female. The maximum number of patients (41.9%) were in the age group of 36-45 years, followed by 46-55 years (35.48%), 26-35 years (9.67%), 56-65 years (8.06%), and 15-25 years (4.8%). 32 (51.6%) patients underwent conventional open mesh repair and 30 (48.3%) subjects had intra-abdominal preperitoneal on-lay mesh repair (IPOM). Females outnumbered the males (64.5% vs 35.4%)

with a male: female ratio of 0.55. The mean age in female patients was 43.47 years, and 44.11 years among male subjects. The female preponderance of incisional hernia in our study had a history of lower abdominal cesarean section (30.6%), hysterectomy (17.7%), or surgery for some other gynaecological procedures. The majority of males had a history of exploratory laparotomy secondary to trauma (17.7%) or gut perforation (12.9%) (Table 1).

Due to the non-availability of laparoscopic equipment at peripheral healthcare systems

and myths associated with laparoscopy, open cholecystectomies are routinely conducted in this part of the developing world. In our study, 9.68% of patients had right upper abdomen scarsesecondary to open cholecystectomy. The incisional herniawas most common among patients who had a history of previous abdominal surgery via lower midline incision (43.55%) (Table 2).

In laparoscopic repair, majority of operations were completed between 60-90 minutes (68.8%) with a mean operative time of 87±8.62minutes. While as80% of surgeries in the open group were completed in 90-120minutes with a mean of 96.56±9.31 minutes (Table3).

The difference was statistically significant. 43.75% of our patients in open repairdeveloped short-term postoperative complications while as only 16.67% patients developed minor complications in the laparoscopic group.Wound site infection was the most common complication present in 5(8.06%) patients. Other complications included respiratory infection (4.84%), seroma (3.23%), hematoma (1.61%), and flap necrosis (1.61%). Moreover, 2 (3.22%) patients in the open group developed

postoperative ileus (Table 4). None of our subjects had serious postoperative complications, postoperative death, or recurrence. The difference between the two groups was not statistically significant with a p-value of 0.677. This was due to meticulous aseptic practice followed during the open mesh repair of incisional hernia. Patients with wound site infections were administered twice daily antiseptic dressing and culture-sensitive antibiotics. The postoperative period was uneventful in 69.35% of patients. RomoVac Suction drain was used in all open cases, and removed once the drainage falls to 25 to 30 mililitre. Drain removal was delayed in patients who developed postoperative seroma.

The duration of hospital stay was calculated from the day of admission to the day of discharge. The mean hospitalstay in the open and laparoscopic group was 5.58±1.69 days and 3.36±1.17 days, respectively. 62.5% of our open repair patients were discharged between the 5th and 6th days of admission, while as 93.33% patients in the laparoscopic group were discharged within 4 days. The difference between the two groups was statistically significant (Table5).

Table 1. Prior surgeries

Type of surgery	Number(percentage)
Hysterectomy	11(17.7%)
Caesarean section (emergency/open)	19(30.6%)
Peptic ulcer perforation	8(12.9%)
Trauma EL	11(17.7%)
Open cholecystectomy	5(8.06%)
Other gynecological operations	3(4.8%)
ELwith resection anastomosis	1(1.6%)
Open pyelolithotomy	1(1.6%)
Peritonitis (perforated appendix, ileal perforation [Enteric], post D&C uterine perforation)	3(4.8%)

EL: Exploratory laparotomy; D&C: Dilatation and curettage

Table 2. Location of previous incision and subsequent hernia

Type of Incision	Number (percentage)
Lower midline	27(43.55%)
Upper midline	19(30.65%)
Pfannenstiel	4(6.45%)
Right subcostal	5(8.06%)
Paramedian	4(6.45%)
Oblique lumbar	1(1.61%)
Right iliac fossa	1(1.61%)

Table 3. Time of operation

Operation time	Laparoscopic Group No.(Percentage)	Open Group No. (percentage)
30-60 min	1(3.33%)	3(9.38%)
60-90 min	22(73.33%)	4(12.5%)
90-120 min	1(3.33%)	24(75%)
120-150 min	6(20%)	1(3.13%)
Mean±SD	87±8.62	96.56±9.31

Table 4. Postoperative complications

Post-operative comp	Open group	Laparoscopic Group	Percentage
Seroma	2	0	3.23%
Haematoma	1	0	1.61%
Wound infection	5	0	8.06%
Serous discharge	1	3	6.45%
Respiratory tract infection	2	1	4.84%
Ileus	2	0	3.22%
Flap necrosis	1	0	1.61%
Recurrence	0	0	0%
Post-operative death	0	0	0%
Umbilical port infection	0	1	1.6%

Table 5. Post-operative hospital-stay

Stay in days	Open Group No.(Percentage)	Laparoscopic Group No.(Percentage)
1-2 days	0(0%)	5(16.67%)
3-4 days	5(15.62%)	23(76.67%)
5-6 days	20(62.5%)	1(3.33%)
7-8 days	5(15.62%)	1(3.33%)
9-10 days	1(3.13%)	0(0%)
11-12 days	1(3.13%)	0(0%)
Mean±SD	5.81±1.69	3.37±1.69±

Discussion

Incisional hernia is defined as a visible or palpable bulge at the site of previous surgical intervention which is more apparent during coughing and straining. The majority of patients present with asymptomatic swelling with positive cough impulse at the site of previous surgical scar and some of them may complain of pain or discomfort. Small fascial defect with a large hernia is more prone to develop obstruction and strangulation. On clinical examination, hernial contents can be palpated, hernia defect felt, and approximate size can be estimated. Patients with complex hernia or morbid obesity may warrant imaging before the surgery for diagnosis (13). The computed tomography scan is the most commonly used method to diagnose an incisional hernia and can also be useful in complex cases to help plan operative management (14-15). Open, laparoscopic, and robotic techniques have been commonly used to repair incisional hernia and must be tailored to the patient and hernia characteristics (16). Open mesh hernia repair is associated with extensive dissection, various postoperative complications, and prolonged hospital stay. Laparoscopy is fast emerging and mimicking the principles of open surgery using small trocars. It results in shorter hospital stays and lower short-term complications, compared to open repair (17). This study was conducted to compare the results of laparoscopic (i.e., IPOM) versus open mesh repair of incisional hernia in our medical college hospital.

In this study, the incidence of incisional hernia was found to be maximum in the age range of 36-45 years (41.9%) followed by 46-55 years (35.48%). The mean age was estimated to be 43.7 years. Females outnumbered the males with a male: female ratio of 0.55. Our results were comparable with the study carried out by Parmanand et al., in which incisional hernia was found more common among females with a male: female ratio of 1:3.25. In the mentioned study, there were 16 males and 52 females with a mean age of 51.1±11.1 years (range: 23-74 years) (18).

The female preponderance of incisional hernia in our study had a history of lower abdominal cesarean section (30.6%) and abdominal hysterectomies (17.7%). Therefore, lower abdominal cesarean section was the most common observed surgery followed by hysterectomy. The majority of males had history of exploratory laparotomy secondary to trauma (17.7%) or peptic ulcer perforation (12.9%). Though laparoscopic cholecystectomy is the treatment of choice for symptomatic cholelithiasis, open surgery is frequently performed in this part of the world. In our study, 8.06% of patients had right subcostal scar secondary to previous open cholecystectomy. This is due to the non-availability of laparoscopic equipment at our peripheral healthcare system and myths associated with laparoscopy. It is imperative to upgrade healthcare systems and health education. Midline incisions are associated with higher rates of incisional hernia than paramedian and transverse incisions (19-20).

The findings are in line with the results of our study. The incisional hernias were most common among patients who had a history of previous abdominal surgeries via lower midline incision (43.55%).

In laparoscopic repair, majority of operations were completed between 60-90 minutes (68.8%) with a mean operative time of 87 ± 8.62 minutes. While as 80% of surgeries in the open group were completed in 90-120 minutes with a mean of 96.56 ± 9.31 minutes. The difference was statistically significant (p-value of 0.05). The results of our study revealed that laparoscopic intra-peritoneal on-lay mesh repair was associated with significantly lesser operative time and hospital stay, compared to open repair. These results were in agreement with the study performed (21-22).

Based on the findings, 43.75% of patients developed short-term postoperative complications in the open repair, while as only 16.67% of patients in the laparoscopic repair had minor postoperative complications. Wound site infection was the most common complication present in 8.06% of patients. Other complication included seroma (3.2%), hematoma (1.61%), mesh infection (1.61%), flap necrosis (1.61%), and respiratory infection (3.2%). Among all participants in the current study, two patients (3.2%) in the open group developed postoperative ileus. None of our subjects had post-operative death or recurrence. The study conducted by Kamal et al. showed that complications were more common in the open repair (47.9%) than in the laparoscopic repair (31.5%) of incisional hernia and major morbidities were associated with open repair than laparoscopy (15% vs 7%) (23). The results of other studies showed that laparoscopic ventral hernia repair had a lower rate of wound infection, compared to open repair (24-26).

In our study, the mean durations of hospital-stay in the open and laparoscopic groups were 5.81 and 3.36 days, respectively. 62.5% of our patients in the open group were discharged between the 5th and 6th days of admission, while 93.33% of subjects in the laparoscopic group were discharged within four days. Consequently, total hospital stay was significantly less in the laparoscopic group than in

the open surgery group. The study results carried out by Carbajo et al. showed hospital stay of 2.2 days for the laparoscopic group and 9.1 days for the open group of patients (21).

This study was conducted on a small sample; therefore, it is required to perform a long-term prospective clinical study with a larger sample size to properly validate these conclusions.

Conclusion

Laparoscopic incisional hernia repair is a promising alternative to conventional repair with encouraging results. The results of our study indicated that laparoscopic repair is safe and resulted in lesser operative time, fewer complications, shorter hospital stay, and early return to activity.

Acknowledgments

None.

Funding

The authors declare that no financial support was received from any organization for the submitted work.

Conflicts of interest

The authors declare that there are no other relationships or activities that could appear to have influenced the submitted work. The authors have no other disclosure.

References

1. Bruce Tulloh & Stephen J. Nixen, *Abdominal wall, hernia and umbilicus*; 27 Edition, Bailey and Love, CRC Press Taylor and Francis Group, 2005: chapter 60; P 1039.
2. Itatsu K, Yokoyama Y, Sugawara G, Kubota H, Tojima Y, Kurumiya Y, Kono H, Yamamoto H, Ando M, Nagino M. Incidence of and risk factors for incisional hernia after abdominal surgery. *Br J Surg*. 2014;101:1439–1447.
3. Sanchez VM, Abi-Haidar YE, Itani KM. Mesh infection in ventral incisional hernia repair: incidence, contributing factors, and treatment. *Surg Infect*. 2011;12:205–210.

4. Burger JW, Luijendijk RW, Hop WC, Halm JA, Verdaasdonk EG, Jeekel J. Longterm Follow-up of a Randomized Controlled Trial of Suture Versus Mesh Repair of Incisional Hernia, *Ann Surg.*2004;240: 578–585.
5. Cassar K, Munro A Surgical treatment of incisional hernia. *Br J Surg.* 2002;89(5):534-545
6. Paul A, Korenkov M, Peters S, Kohler L, Fisher S, Troidl H. Unaccepted results of the Mayo Procedure for repair of abdominal incisional hernia. *Eur J Surg.*1998;164(5):361-367.
7. McGreevy JM, Goodney PP, Birkmeyer CM, Finlayson SR, Laycock WS, Birkmeyer JD. A prospective study comparing the complication rates between laparoscopic and open ventral hernia repairs. *SurgEndosc.* 2003;17:1778-1780.
8. Heniford BT, Park A, Ramshaw BJ, Voeller G. Laparoscopic ventral and incisional hernia repair in 407 patients. *J Am Coll Surg.*2000;190:645-650.
9. Olmi S, Magnone S, Erba Luigi. Results of Laparoscopic versus open abdominal and incisional hernia repair. *J Soc LaproendoscSurg.*2005;9:189-195.
10. Holzman MD, Purut CM, Reintgen K, Eubanks S, Pappas TN. Laparoscopic ventral and incisional hernioplasty. *SurgEndosc.*1997;11:32-35.
11. Franklin ME Jr, Gonzalez JJ Jr, Glass JL. Use of porcine small intestinal submucosa as a prosthetic device for laparoscopic repair of hernias in contaminated fields: 2-year follow-up. *Hernia.* 2004;8:186-189.
12. Larson GM. Ventral hernia repair by the laparoscopic approach. *Surg Clin North Am.* 2000;80(4):1329-1340.
13. Halligan S, Parker SG, Plumb AA, Windsor AC. Imaging complex ventral hernias, their surgical repair, and their complications. *European radiology.* 2018;28(8):3560-3569.
14. Farukhi MA, Mattingly MS, Clapp B, Tyroch AH. CT scan reliability in detecting internal hernia after gastric bypass. *JLS.* 2017;21(4): e2017.00054.
15. Holihan JL, Karanjawala B, Ko A, Askenasy EP, Matta EJ, Gharbaoui L, Hasapes JP, Tammisetti VS, Thupili CR, Alawadi ZM, Bondre I. Use of computed tomography in diagnosing ventral hernia recurrence: a blinded, prospective, multispecialty evaluation. *JAMA surgery.* 2016;151(1):7-13.
16. de Vries HS, Smeeing D, Lourens H, Kruyt PM, Mollen RM. Long-term clinical experience with laparoscopic ventral hernia repair using a Parietex™ composite mesh in severely obese and non-severe obese patients: a single center cohort study. *MITAT.*2019;28(5):304-308.
17. McGreevy JM, Goodney PP, Birkmeyer CM, Finlayson SR, Laycock WS, Birkmeyer JD. A prospective study comparing the complication rates between laparoscopic and open ventral hernia repairs. *SurgEndosc.*2003;17:1778-1780.
18. Parmanand Prasad, Om Tantia, Nirmal M Patle, Shashi Khanna, Bimalendu Sen. Laparoscopic Transabdominal Preperitoneal Repair of Ventral Hernia: A Step Towards Physiological Repair. *Indian J Surg.*73(6):403–408.
19. Cox PJ, Ausobsky JR, Ellis H, Pollock AV. Towards no incisional hernias: Lateral paramedian versus midline incisions. *J R Soc Med.* 1986;79(12):711-712.
20. Brown SR, Tiernan J. Transverse versus midline incisions for abdominal surgery. *The Cochrane Library.* 2005(4). doi.org/10.1002/14651858.CD005199.pub2
21. Carbajo MA, Del Olmo JM, Blanco JI, De la Cuesta C, Toledano M, Martin F, Vaquero C, Inglada L. Laparoscopic treatment vs open surgery in the solution of major incisional and abdominal wall hernias with mesh. *SurgEndosc.* 1999;13:250-252.
22. Ramshaw BJ, Esartia P, Schwab J, Mason EM, Wilson RA, Duncun TD. Comparison of Laparoscopic and open ventral herniorrhaphy. *Am Surg.* 1999;65:827-831.
23. Itani KM, Hur K, Kim LT, Anthony T, Berger DH, Reda D, Neumayer L. Comparison of Laparoscopic and Open Repair With Mesh for the Treatment of Ventral Incisional Hernia. *ArchSurg.*2010;145(4):322-328.
24. Bingener J, Buck L, Richards M, Michalek J, Schwesinger W, Sirinek K. Longterm outcomes in

laparoscopic vs. open ventral hernia repair. Arch Surg. 2007; 142(6):562-567.

25. Cuccurullo D, Piccoli M, Agresta F, Magnone S, Corcoine F, Stancanelli V, et al. Laparoscopic ventral incisional hernia repair: Evidence-based guidelines of the first Italian consensus conference. Hernia.

2013;17(5):557-566.

26. Sauerland S, Walgenbach M, Habermalz B, Seiler CM, Miserez M. Laparoscopic versus open surgical techniques for ventral or incisional hernia repair. Cochrane Libr. 2011(3). doi.org/10.1002/14651858.CD007781.pub2