



Case Report

Non-surgical endodontic treatment of long-standing traumatized immature tooth with periapical lesion: a case report

Maryam Dalaei Moghadam¹  , Forough Farahi² 

¹ Post Graduate Endodontics Student, Department of Endodontic, School of Dentistry, Zahedan University of Medical Science, Zahedan, Iran

² Assistant Professor, Department of Endodontic, Faculty of Dentistry, Zahedan University of Medical Science, Zahedan, Iran

Corresponding Author:

Tel: +09120407133

Email: Maryam.dalaei@yahoo.com

Abstract

The treatment of necrotic permanent teeth with immature apices is a daunting challenge. Apexification has been traditionally used to treat immature permanent teeth with lost pulp vitality. This technique promotes the formation of an apical barrier to close the open apex so that filling materials can be confined to the root canal. The authors present a case report of the successful treatment of a traumatized tooth with an open apex that was weakened due to a long-standing infection and thin dentin walls. In this case, we first used a triple antibiotic to disinfect the canal and then placed a calcium-enriched mixture (CEM) cement plug. Follow-up evaluations were performed 15 months after treatment. The CEM-cement appears to be a valid material to obtain periradicular healing in teeth with open apices and necrotic pulps.

Keywords: Apexification, Therapy, Dental Pulp Necrosis

Citation: Dalaei Moghadam M, Farahi F. Non-surgical endodontic treatment of long-standing traumatized immature tooth with periapical lesion: a case report. *J Surg Trauma*.2022;10(1):39-44.

Received: September 13, 2021

Revised: October 10, 2021

Accepted: November 3, 2021

Introduction

Periapical periodontitis is a common inflammatory odontogenic lesion of the jaw(1-2) defined as an oral inflammatory disease caused by the reaction of the host immune system to the presence of microorganisms or their products. The microorganisms are found close to or in the root canal system or at the outside around the root apex(3-4). Carious and trauma are the most common reasons for the inflammation or necrosis of the pulp tissue in permanent teeth (5). It is recognized that the healing of these lesions depends on proper mechanical and chemical removal of the infected canal content, as well as three-dimensional canal obturation(2-6).

Although root canal treatment is necessary under these circumstances, the treatment process is complicated for permanent teeth if their apices are open due to such reasons as incomplete root development by the necrosis of the pulp, trauma, or resorption of apex by the periapical lesion(5). Nonetheless, the absence of any apical constriction creates a risk for the extrusion of filling material beyond the apex(7). In the present study, the calcium-enriched mixture (CEM) cement was used to create a barrier at the apical end of the canal. The CEM cement was introduced as a hydrophilic tooth-colored endodontic biomaterial with a composition different from mineral trioxide aggregate (MTA). It is biocompatible, non-cytotoxic, and antibacterial with favorable sealing ability. The CEM is proved to be hard tissue-inductive with dentinogenic, cementogenic, and osteogenic potentials(8).

In vivo studies have confirmed the biocompatibility and hard tissue inductive effect of this material (8-12). The presence and size of periapical lesions have a major role to play in the prognosis of endodontic treatment. The negative effect of larger lesions on treatment success is due to the higher diversity of microorganisms and their association with long-standing infections since the bacteria in such lesions have greater penetration into the dentinal tubules. Moreover, these lesions may be associated with cystic transformation. On the other hand, larger lesions in some patients have a slower response to ecological changes caused by the treatment

protocol(13). Some studies found no significant difference in the success rate of lesions with different sizes(2-14-16). Nonetheless, the size of the lesion had a significant effect on treatment success in some other studies(15-19). This report pointed to the management of an immature maxillary incisor with a periradicular lesion.

Case

A 38-year-old male patient with a history of trauma 31 years ago and severe pain in tooth #9 was referred to the Department of Endodontics at Zahedan Dental University. At that time, the affected teeth had not been treated. The patient had visited a private office two weeks ago for the treatment of his swollen tooth (#9) and had undergone a polypectomy. Thereafter, he was referred to the Endodontic Department of Zahedan University of Medical Science. The medical history was non-contributory. Clinical evaluation revealed a crown fracture and gray discoloration of tooth #9 (Figure 1. A).

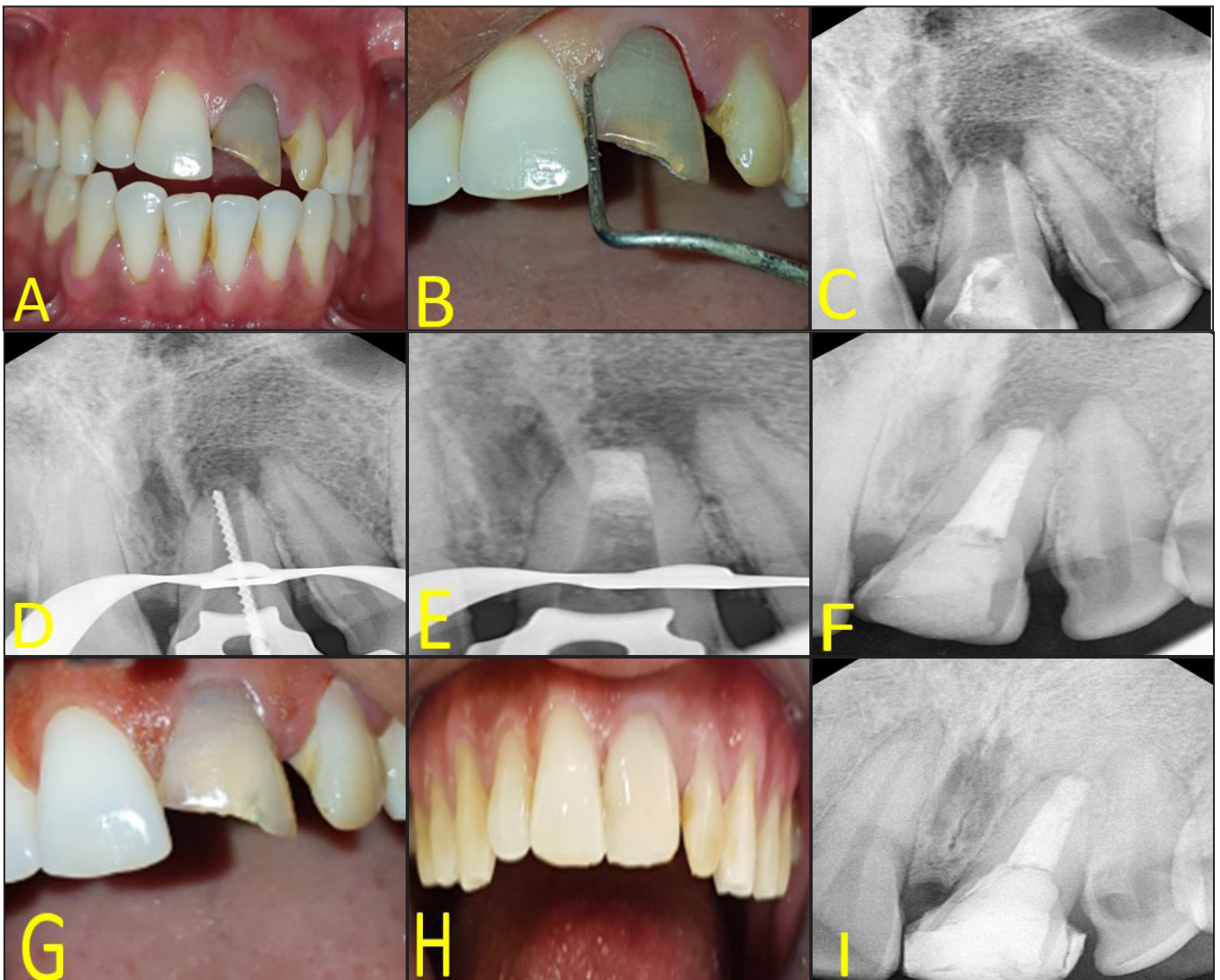
The patient had no pain or swelling upon admission. The tooth was sensitive to percussion/palpation. The probing depth of the adjacent gingiva was normal, and there was no mobility (Figure 1. B). The tooth did not show any response to different pulp tests. The radiographic examination revealed immature roots with an open apex and a large radiolucent lesion around the root apex of tooth# 9(Figure 1. C). The initial treatment plan was regenerative endodontic treatment (RET). The treatment steps were explained to the patient, and informed consent was obtained.

The tooth was anesthetized by infiltration anesthesia using 2% lidocaine with 1:80,000 epinephrine (Persocaine, DarouPakhsh, Tehran, Iran) and isolated using a rubber dam. Cavit was removed, and an endodontic access cavity was prepared. The canal was then gently cleaned with manual instruments and 0.5% sodium hypochlorite(NaOCl) (Chloraxid, Cerkamed, Poland) irrigation and agitation with ultrasonic tip (Dentsply Maillefer, Ballaigues, Switzerland). The working length(WL) was measured radiographically with a K-file and recorded for reference (Figure 1. D). The

canals were dried with sterile paper points, and an antibiotic paste (combination of three antibiotics: ciprofloxacin, metronidazole, and amoxicillin) was spun into the canal as an interim medication. In this case report, amoxicillin-containing TAP was used for the revascularization of non-vital immature teeth to prevent tooth discoloration(20).

The access cavities were sealed using a 3 mm Cavit (Golchay, Tehran, Iran). The patient was recalled after three weeks. Local infiltration anesthesia was performed with 3% plain mepivacaine and

without vasoconstrictor to facilitate bleeding as suggested by Petrino et al. (21), and the tooth was isolated by a rubber dam. The antibiotic intracanal medicament was gently removed from the canal via irrigation with 20 mL of normal saline and 20 mL of 17% EDTA solution (AriaDent, Tehran, Iran). At a subsequent visit, we tried to induce bleeding in the canal; nonetheless, we did not reach the result; consequently, we started apexification. After disinfection with 0.5% NaOCl, final irrigation was performed with saline.



A) Clinical picture depicting crown fracture and gray discoloration of left maxillary central incisor, B) The probing depth of tooth 9 was less than 3 mm, C) Preoperative diagnostic radiograph of tooth 9 with open apex and periapical radiolucency, D) radiography taken after determining the WL, E) CEM cement apical plug placement in the apical portion of the canal, F) Radiograph taken after root canal obturation, G) Clinical picture after bleaching, H) Clinical picture depicting composite restoration, I) 15-month radiograph showing almost complete healing of periradicular radiolucency

Once the canal was dry at the WL, with no exudate, the CEM cement apical plug (Bionique Dent, Tehran, Iran) was placed in the apical portion of the canal with a thickness of 3-5 mm, as recommended by the manufacturer and the formation of the mineralized barrier was confirmed radiographically (Figure 1. E). A sterile cotton pellet moistened with normal saline was placed over the canal orifice and the access cavity was sealed temporarily. After one day, the canals were back-filled with a vertical condensation technique (Figure 1. F). To improve teeth discoloration, bleaching treatment was considered with sodium perborate in two sessions at two-week intervals (Figure 1. G). The patient was referred for the final restoration to the restorative department (Figure 1. H). Clinical and radiographic signs at 15 months demonstrated evidence of a successful therapy (Figure 1. I).

Discussion

Trauma to young permanent anterior teeth may result in necrotic changes to the pulp since it may not withstand the impact of injury, leaving the tooth with thin fragile root walls, blunderbuss canals, and infection which promotes root resorption and periradicular disease(22). Injuries to the teeth occur more often as a result of falls, brawls in the schoolyard, and during sports activities, such as bicycle riding and contact sports. Boys often experience more dental trauma than girls and maxillary central incisors are the most commonly affected teeth(23). The goal of apexification is to obtain an apical barrier to prevent the passage of toxins and bacteria into the periapical tissues from a root canal(24).

Since instruments cannot be used properly in teeth with open apices, cleaning and disinfection of the root canal system rely on the chemical action of NaOCl as an irrigant and calcium hydroxide or antibiotic paste as an intracanal dressing. The NaOCl is known to be toxic, especially in high concentrations. Rinsing immature teeth with open apices increases the risk of pushing the irrigant beyond the apical foramen(25). Therefore, it is advisable to use less concentrated NaOCl (0.5%) which is less toxic. Ultrasonic tips

were used for the activation of NaOCl in this case. Studies have demonstrated that the use of ultrasonics increases the bactericidal efficiency of endodontic irrigation(26).

It was also found that regenerative endodontic procedures were suitable for patients within the age range of 9-18 years. Immature permanent teeth with a necrotic pulp that require a post for adequate coronal restoration are not suitable for RET and are better treated with apical MTA plug and root canal filling(27). The CEM-cement is a bioceramic used in a variety of clinical applications as a one-step apexification or revascularization treatment for necrotic immature permanent teeth. Due to the excellent biological properties of CEM-cement and its ability to create a good seal, it has been recommended for the creation of an artificial barrier in the apical area of teeth with open apices (10).

Some studies which compared regenerative endodontic treatment and apical barrier technique demonstrated no statistical difference between them in terms of survival and clinical success (28-29). A recent case series exhibited the success of CEM apical plug in the treatment of teeth with open Apices (30). Comparable to MTA, the CEM cement is biocompatible in terms of cytotoxicity and genotoxicity; moreover, it is able to induce hard tissue formation (i.e., osteogenesis, dentinogenesis, and cementogenesis (10). In this case, CEM cement has been used as an apical barrier, yielding satisfactory results.

The root canal system should be obturated three-dimensionally, and the final hermetical coronal restorations are needed. There is still controversy over the evaluation of successful and unsuccessful root canal treatments. Nevertheless, when the teeth are clinically asymptomatic and radiographic images show evidence of healing, it can be concluded that root canal treatment is successful.

Conclusion

This case study aimed to report the successful treatments of a case with a long-standing and large preapical lesion. It demonstrated that full execution of disinfection procedures and appropriate final

coronal restorations after nonsurgical root canal treatment resulted in healing, regardless of the degree of tooth maturation and size of the lesions.

Conflicts of Interest

The authors declare that they have no conflict of interest.

References

1. Angerame D, De Biasi M, Sossi D, Marigo L, Castagnola R, Somma F, et al. Periapical healing after simplified endodontic treatments: a digital subtraction radiography study. *G Ital Endod.* 2013;27(2):74-79.
2. Moghadam MD, Saberi EA, Molashahi NF, Ebrahimi HS. Comparative efficacy of Depo-phoresis and diode laser for reduction of microbial load and postoperative pain, and healing of periapical lesions: a randomized clinical trial. *G Ital Endod.* 2021;35(2).
3. Liang Y-H, Jiang L-M, Jiang L, Chen X-B, Liu Y-Y, Tian F-C, et al. Radiographic healing after a root canal treatment performed in single-rooted teeth with and without ultrasonic activation of the irrigant: a randomized controlled trial. *J Endod.* 2013;39(10):1218-1225.
4. Kakehashi S, Stanley H, Fitzgerald R. The effects of surgical exposures of dental pulps in germ-free and conventional laboratory rats. *Oral Surg Oral Med Oral Pathol.* 1965;20(3):340-349.
5. Demiriz L, Bodrumlu EH. Retrospective evaluation of healing of periapical lesions after unintentional extrusion of mineral trioxide aggregate. *J Appl Biomater Funct Mater.* 2017;15(4):382-386.
6. Ng YL, Mann V, Gulabivala K. A prospective study of the factors affecting outcomes of nonsurgical root canal treatment: part 1: periapical health. *Int Endod J.* 2011;44(7):583-609.
7. Fuks AB. Pulp therapy for the primary and young permanent dentitions. *Dent Clin North Am.* 2000;44(3):571-596.
8. Asgary S, Fazlyab M, Sabbagh S, Eghbal MJ. Outcomes of different vital pulp therapy techniques on symptomatic permanent teeth: a case series. *Iran Endod J.* 2014;9(4):295-300.
9. Utneja S, Nawal RR, Talwar S, Verma M. Current perspectives of bio-ceramic technology in endodontics: calcium enriched mixture cement-review of its composition, properties and applications. *Restor Dent Endod.* 2015;40(1):1-13.
10. Asgary S, Çalışkan MK. Vital pulp therapy of a mature molar with concurrent hyperplastic pulpitis, internal root resorption and periradicular periodontitis: a case report. *Iran Endod J.* 2015;10(4):284-286.
11. Asgary S, Ahmadyar M. Vital pulp therapy using calcium-enriched mixture: An evidence-based review. *J Conserv Dent.* 2013;16(2):92-98.
12. Dalaei Moghadam M, Farahi F. Tooth autotransplantation of the mandibular third molar: A case report. *J Surg Trauma.* 2021;9(4):166-170.
13. Ng YL, Mann V, Rahbaran S, Lewsey J, Gulabivala K. Outcome of primary root canal treatment: systematic review of the literature—part 1. Effects of study characteristics on probability of success. *Int Endod J.* 2007;40(12):921-939.
14. Byström A, Happonen RP, Sjögren U, Sundqvist G. Healing of periapical lesions of pulpless teeth after endodontic treatment with controlled asepsis. *Dent Traumatol.* 1987;3(2):58-63.
15. Strindberg LZ. The dependence of the results of pulp therapy on certain factors-an analytical study based on radiographic and clinical follow-up examination. *Acta Odontol Scand.* 1956;14:1-175.
16. Sjögren U, Hägglund B, Sundqvist G, Wing K. Factors affecting the long-term results of endodontic treatment. *J Endod.* 1990;16(10):498-504.
17. Hoskinson SE, Ng Y-L, Hoskinson AE, Moles DR, Gulabivala K. A retrospective comparison of outcome of root canal treatment using two different protocols. *Oral Surg Oral Med Oral Pathol Oral Radiol.* 2002;93(6):705-715.
18. Aksoy F. Outcomes of nonsurgical endodontic treatment in teeth with large periapical lesion. *Ann Med Res.* 2019;26(11):2642-2647.
19. Chugal NM, Clive JM, Spångberg LS. A prognostic model for assessment of the outcome of endodontic treatment: effect of biologic and diagnostic variables. *Oral Surg Oral Med Oral Pathol Oral Radiol Endod.* 2001;91(3):342-352.

20. Park H-B, Lee B-N, Hwang Y-C, Hwang I-N, Oh W-M, Chang H-S. Treatment of non-vital immature teeth with amoxicillin-containing triple antibiotic paste resulting in apexification. *Restor Dent Endod*. 2015;40(4):322-327.
21. Petrino JA, Boda KK, Shambarger S, Bowles WR, McClanahan SB. Challenges in regenerative endodontics: a case series. *J Endod*. 2010;36(3):536-541.
22. Damle S, Bhattal H, Loomba A. Apexification of anterior teeth: a comparative evaluation of mineral trioxide aggregate and calcium hydroxide paste. *J Clin Pediatr Dent*. 2012;36(3):263-268.
23. Francisco SS, Souza Filho F, Pinheiro ET, Murrer RD, Soares AdJ. Prevalence of traumatic dental injuries and associated factors among Brazilian schoolchildren. *Oral Health Prev Dent*. 2013;11(1):31-38.
24. Donyavi Z, Khoshbin E, Kavandi Z. The Treatment of Immature Teeth With Periapical Lesions Using Ca (OH) 2 and MTA: A Case Report. *Avicenna J Dent Res*. 2017;9(4). doi: 10.5812/ajdr.30189.
25. Raldi DP, Mello I, Márcia Habitante S, Lage-Marques JL, Coil J. Treatment options for teeth with open apices and apical periodontitis. *J Can Dent Assoc*. 2009;75(8).
26. Martin H. Ultrasonic disinfection of the root canal. *Oral Surg Oral Med Oral Pathol*. 1976;42(1):92-99.
27. Kim S, Malek M, Sigurdsson A, Lin L, Kahler B. Regenerative endodontics: a comprehensive review. *Int Endod J*. 2018;51(12):1367-1388.
28. Chen S-J, Chen L-P. Radiographic outcome of necrotic immature teeth treated with two endodontic techniques: A retrospective analysis. *Biomed J*. 2016;39(5):366-371.
29. Alobaid AS, Cortes LM, Lo J, Nguyen TT, Albert J, Abu-Melha AS, et al. Radiographic and clinical outcomes of the treatment of immature permanent teeth by revascularization or apexification: a pilot retrospective cohort study. *J Endod* 2014;40(8):1063-1070.
30. Nosrat A, Asgary S, Eghbal MJ, Ghodduji J, Bayat-Movahed S. Calcium-enriched mixture cement as artificial apical barrier: A case series. *J Conserv Dent*. 2011;14(4):427-431.