

# CASE REPORT

## A case of penetrating orbitocranial injury

Jalal Ahmadi<sup>1</sup>, Abbas Hosseinirad<sup>2</sup>, Hoda Dadgar<sup>3</sup>, Mahmoud Ganjifard<sup>4</sup>✉

<sup>1</sup> Neurosurgeon, Department of Neurosurgery, Birjand University of Medical Sciences, Birjand, Iran

<sup>2</sup> Assistant Professor, Department of Ophthalmology, Birjand University of Medical Sciences, Birjand, Iran

<sup>3</sup> M.D, Birjand University of Medical Sciences, Birjand, Iran

<sup>4</sup> Assistant Professor, Department of Anesthesiology, Birjand University of Medical Sciences, Birjand, Iran

Received: August 30, 2017

Revised: August 17, 2017

Accepted: September 24, 2017

### Abstract

The case is a 2-year-old previously healthy girl with coincidental penetrating eye and brain injury. A metal rod was inserted into the skull through the upper border of the right globe. After admission and diagnostic and surgical approaches, the rod was removed under general anesthesia, and no brain hematoma or ocular and significant periocular injuries were detected. No neurologic and ophthalmologic signs and symptoms were observed during hospitalization, and follow-up brain CT was normal.

**Key Words:** Penetrating cranial injury; Penetrating eye injury; Eye foreign body

### Introduction

A common cause of unilateral blindness in children and adolescents is eye injury. Adolescents, especially boys, bear severe orbital injury and are common victims of penetrating eye injury. Domestic (homemade) accidents and sport-related injuries are most common situations in which ocular injuries happens (1).

The pediatric age group accounts for 8-14% of all eye injuries. Pediatric ocular injury is usually accidental and unilateral (2, 3). In contrast, adult ocular injury is usually the result of intentional assault. Males are more affected than females at a rate of approximating 4:1 (4-7).

### Cases

A 2-year-old, previously healthy girl was presented to Imam Reza Hospital emergency department. A metal rod was inserted into the skull through the upper border of the right globe. The girl was agitated and irritated. History tracking revealed that the girl had an accidental falling on

the metal rod that was in her hand. No unconsciousness and vomiting were reported. The right eye was fixed and the right upper eyelid through which the metal rod was inserted was retracted completely (figure1). After initial evaluation, imaging studies, and laboratory examinations, the patient was referred to a neurosurgeon and ophthalmologic consultation was performed. Plane skull radiography and brain CT revealed that the rod was introduced into the brain through the orbit (figure2, 3, 4). Drug history, history of allergy, surgery and anesthesia were negative. The patient was NPO for 6 hours. On examination, her temperature was 37°C, BP=90/60, RR=20, HR=130. Heart auscultation revealed S1 and S2, and no click or murmur was heard. Lung auscultation was clear. Airway examination could not be performed because of poor cooperation. No ecchymosis, hematoma, edema and inflammation were in the insertion site, the right orbit, and other parts of the skull. Funduscopic examination was normal. Laboratory panel revealed Hgb=12.7, plt=271000, urea=24, creatinine=0.7, Na=143, K=5,

©2017 Journal of Surgery and Trauma

Tel: +985632381203

Fax: +985632440488

Po Bax 97175-379

Email: jsurgery@bums.ac.ir



✉ Correspondence to:

Ganjifard M, Anesthesiologist, Department of Anesthesiology, Birjand University of Medical Sciences, Birjand, Iran;

Telephone Number: +989155620522

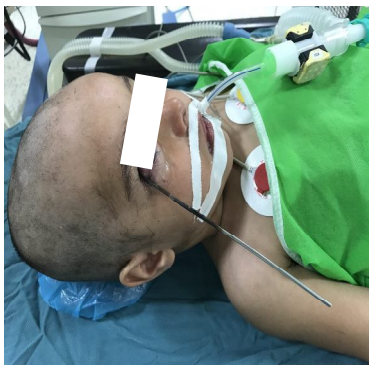Email Address: Ganji50@hotmail.com

and BS= 98.

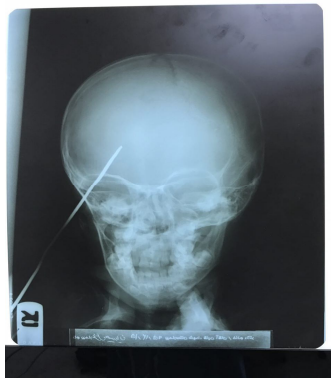Induction of anesthesia was performed by injection of 1 mg midazolam, 50 microgram fentanyl, 50 mg sodium thiopental, and 5 mg atracurium. The patient received 100 mic-gram/kg/min propofol as maintenance anesthetic drug. She was intubated by NO=4 endotracheal tube. Monitoring including ECG, NIBP, and SPO2 were applied. Ophthalmologic examinations were performed before and after induction. No sign of globe rupture was found, and anterior segment examination revealed intact cornea and sclera. The pupil was round and reactive and Marcus Gunn was negative. Fundoscopy of the right eye showed clear media, sharp optic disc margin, normal retinal vasculature, and normal macula. There was no edema and hemorrhage in the vitreous and retina.

After prep and drape in the supine position, skin incision in the upper border of the right eyebrow was performed, and a small craniotomy in the base of frontal lobe was performed. After detecting the entrance site of the foreign body (FB)

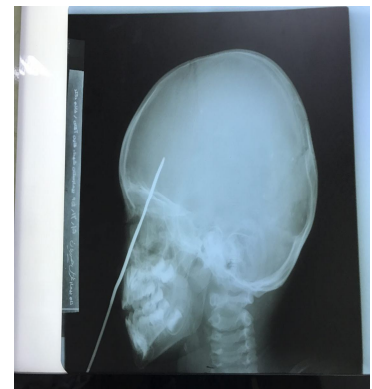into the cranium, FB was removed and dura was repaired. Thereafter, another complete and delicate ophthalmologic investigation was done. Globe was intact and no injury to the lacrimal gland was detected. Finally, cranioplasty and repair of skin incision were carried out (figure5,6). The surgery took one hour and the patient was extubated. Spontaneous breathing was effective, and hemodynamic and gas exchange conditions were acceptable. The patient was transferred to the neurosurgery ward. No neurologic and ophthalmologic signs and symptoms were observed during hospitalization. Computed tomography (CT) of the brain for follow-up was normal. Ocular examination of the right eye 3 days after trauma was done and only mild lid edema was found. Visual acuity tests for this age were normal. Ocular motility was normal and alignment of the patient in primary position, upgaze and downgaze was normal. Anterior and posterior segment evaluation was normal. No pain or ocular discomfort was reported by the patient.



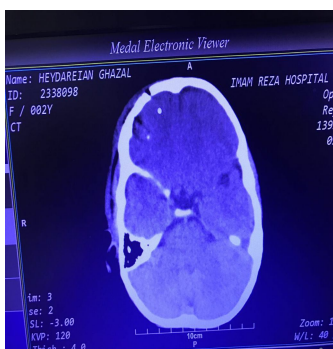
**Figure 1:** patient in the operating room after induction of anesthesia and before surgery



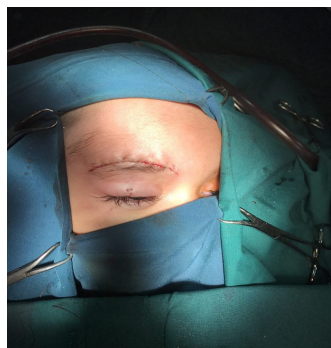
**Figure 2:** plain skull Xray (AP view) denoting trajectory of metal rod



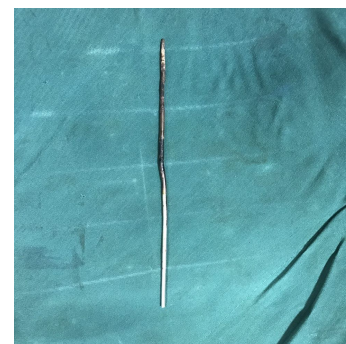
**Figure 3:** plain skull Xray(lateral view) denoting trajectory of metal rod



**Figure 4:** Brain CT scan denoting cross section of metal rod



**Figure 5:** right eye after completion of surgery showing site of rod entrance and surgical approach



**Figure 6:** metal rod after removal

## Discussion

In patients with a high likelihood of an open globe based on mechanism of injury (e.g. penetrating eye injury) or physical findings (obvious perforation with teardrop pupil, vitreous prolapse, or protruding intraocular foreign body), the emergency clinician should avoid any further examination procedure that might apply pressure on the eyeball, such as eyelid retraction or intraocular pressure measurement by tonometry and should not place any medication (e.g. tetracaine) or diagnostic eye drops (e.g. fluorescein) into the eye (4). Any protruding foreign body should be left in place. In young children, the extent of ocular injury often cannot be assessed by the emergency clinician due to poor cooperation. In these cases, examination under anesthesia by an ophthalmologist may be necessary. Eye trauma presents a challenge to anesthesiologists. The dilemma is to protect the patient from pulmonary aspiration of stomach content and to protect the eye from acute changes in IOP which could cause vitreous loss and retinal detachment. A rapid-sequence induction of anesthesia provides rapid control of airway but succinylcholine causes a moderate increase in IOP. Of course, intubating the trachea during light anesthesia or inadequate neuromuscular blockade can cause a large increase in IOP (8)(1).

At first, the external structures and bony orbit must be examined (by an ophthalmologist). The eyelids are evaluated for laceration, noting any involvement of the lid margins or lacrimal system. Examination of the pupils for their shape, size, symmetry, direct, and consensual responses to light should be noted. The pupillary examination is especially important in cases where intracranial injury is possible. The pupils should not be pharmacologically dilated until mental status has been assessed and neurologic status deemed stable. Evaluation of the extraocular muscle function in all directions of gaze may identify a restriction of gaze attributable to muscle entrapment within an orbital fracture or traumatic cranial nerve injury. Slit lamp examination of the globe allows classification of conjunctival hyperemia, subconjunctival hemorrhage, hyphema, corneal opacities and edema, foreign bodies, traumatic iris tears, and lens location and stability. Fluorescein strips can be used to delineate corneal abrasions and to detect any active aqueous leakage from the anterior chamber using the Seidel test. When presented with eyelid avulsion (tearing or shearing injury) or laceration, the restoration of any lacrimal injury should be considered prior to

repair. Injuries to the inferior punctum, inferior canaliculus, or common canaliculus are more likely to cause significant tearing (4).

Penetrating brain injury (PBI) is a traumatic brain injury caused by low-velocity sharp objects (e.g. a knife) or high velocity objects (shell fragment or bullet). Mechanism of injury in these two types of PBI is different. Low velocity sharp objects, which lack bulletistics, penetrate the scalp, skull and Dura and lacerate brain parenchyma and any blood vessels in their path (9, 10). The focal motor, cognitive and behavioral consequences of these injuries depend on the part of the brain that is injured. Injury of blood vessels produces subarachnoid hemorrhage, intracranial hematoma, or traumatic intracranial aneurysm (TICAs) and arteriovenous fistula (AVFs)(9, 11). When sharp objects, low velocity spall, and bullets penetrate the brain, they may cause focal deficits and additionally cause depressed level of consciousness if they disrupt the brainstem.

Patients with perioral and orbitocraniocerebral injuries, fragments associated with acute or delayed ICH and fragments passing through two Dura compartments, are highly prone to vascular injury. In any patient at risk for vascular injury, CT angiography should be performed (12, 13).

Surgical management of patients with PBI include debridement and repair of scalp lacerations, debridement and watertight closure of Dura matter, debridement of devitalized brain tissue, debridement of retained fragments and repair of the skull base. All patients should receive broad-spectrum antibiotics and anticonvulsants. Complications of PBI are neurovascular injury (traumatic intracranial aneurysm and arteriovenous fistulas), intracranial infections, and posttraumatic epilepsy

Coincidental penetrating brain and eye injury can be challenging to assess especially in children. The most effective and proactive approach to penetrating brain and eye injury is primary prevention by improving popular education and risk reduction.

Depending on the type of injury, various forms of imaging modalities may be pursued. Radiographs, ultrasonography, CT, or MRI may be ordered. MRI is always contraindicated when a metallic foreign body is suspected (4). CT and three dimensional reconstruction of the head define the entry site, trajectory of the fragment into the brain, and involvement of the paranasal sinuses, orbits, skull base and mastoids. Direct and indirect evidence of vascular injury can be clearly shown by cranial CT. CT shows the intracranial hematomas, brain edema and ischemia in the brain (14-17).

Various degrees of subarachnoid hemorrhage or delayed intracranial hematoma can indicate the need for angiography.

In this case, the major concern is late complications such as neurovascular abnormalities, epilepsy, lid abnormality, ocular motility problems, orbital cellulitis, and lacrimal injury.

## Conclusions

Thorough physical examination, imaging studies, and expert consultation are necessary in approach to patients with coincidental penetrating brain and eye trauma. In children, IV sedation is frequently required to prevent further injury and facilitate physical examination and imaging studies. Long-term follow-up of these patients needs also to be warranted. Recovery of full eyelid function, ocular motility and normal function of the lacrimal system are important considerations when approaching lid trauma. Follow-up for epilepsy and neurologic sign and symptoms must be considered. Popular education to prevent homemade penetrating trauma is the most efficient way for harm reduction. In this case, long-term follow-up noting late complications of penetrating eye and brain injury is warranted.

## Conflict of interest

The author declares no conflict of interest.

## References

1. Riordan-Eva P, Cunningham ET, 1960-, Vaughan D, 1921-2000., Asbury T. Vaughan & Asburys general ophthalmology. 18th ed. New York: McGraw-Hill Medical; 2011.
2. Scribano PV, Nance M, Reilly P, Sing RF, Selbst SM. Pediatric nonpowder firearm injuries: outcomes in an urban pediatric setting. *Pediatrics*.1997 ;100(4):E5.
3. Takvam JA, Midelfart A. Survey of eye injuries in Norwegian children. *Acta Ophthalmol*.1993;71(4):500-5.
4. Kosoko-Lasaki O, Palmer MM. Penetrating Eye Injury: A Case Study. *American Journal of clinical medicine*. Winter 2009. Volume6-Number one.
5. Dannenberg AL, Parver LM, Brechner RJ, Khoo L. Penetrating eye injuries in the workplace: the National Eye Trauma System Registry. *Arch Ophthalmol*.1992;110(6):843-8.
6. Dannenberg AL, Parver LM, Fowler CJ. Penetrating eye injuries related to assault: the National Eye Trauma System Registry. *Arch Ophthalmol*. 1992;110(6):849-52.
7. Wong TY, Klein BE, Klein R. The prevalence and 5-year incidence of ocular trauma: the Beaver Dam Eye Study. *Ophthalmology*. 2000;107(12):2196-202.
8. Forkin KT, Nemergut EC. Miller's Anesthesia, 8th Edition. *Anesthesiology*. 2016;124(4):977-8.
9. De Villiers J, Sevel D. Intracranial complications of transorbital stab wounds. *British Journal of Ophthalmology*. 1975;59(1):52-6.
10. du Trevaux MD, van Dellen JR. Penetrating stab wounds to the brain: the timing of angiography in patients presenting with the weapon already removed. *Neurosurgery*. . 1992;31(5):905-12.
11. Taylor AG, Peter JC. Patients with retained transcranial knife blades: a high-risk group. *J Neurosurg*.1997;87(4):512-5.
12. Aarabi B. Management of traumatic aneurysms caused by high-velocity missile head wounds. *Neurosurg Clin N Am*. 1995;6(4):775-97.
13. Bell RS, Vo AH, Roberts R, Wanebo J, Armonda RA. Wartime traumatic aneurysms: acute presentation, diagnosis, and multimodal treatment of 64 craniocervical arterial injuries. *Neurosurgery*. 2010;66(1):66-79.
14. Levy ML, Rezai A, Masri LS, Litofsky SN, Giannotta SL, Apuzzo ML, et al. The significance of subarachnoid hemorrhage after penetrating craniocerebral injury: correlations with angiography and outcome in a civilian population. *Neurosurgery*. 1993;32(4):532-40.
15. Levi L, Linn S, Feinsod M. Penetrating craniocerebral injuries in civilians. *Br J Neurosurg*.1991;5(3):241-7.
16. Stone JL, Lichtor T, Fitzgerald LF. Gunshot wounds to the head in civilian practice. *Neurosurgery*. 1995;37(6):1104-12.
17. Helling TS, McNABNEY WK, Whittaker CK, Schultz CC, Watkins M. The role of early surgical intervention in civilian gunshot wounds to the head. *J Trauma*. 1992;32(3):398-400.