

Early surgical and orthodontic treatment of a severely dilacerated maxillary central incisor: A case report

Mahdjoube Goldani Moghadam^{1✉}, Haniye Kazemi²

¹ Assistant Professor of Orthodontics, Department of Orthodontics, Faculty of Dentistry, Birjand University of Medical Sciences, Birjand, Iran;

² Undergraduate Student of Dentistry, Faculty of Dentistry, Birjand University of Medical Sciences, Birjand, Iran.

Received: December 22, 2017

Revised: January 15, 2018

Accepted: April 18, 2018

Abstract

Mechanical trauma or developmental disorders can cause an eruptive problem mostly called dilaceration. The prognosis of a dilacerated tooth depends on early diagnosis and appropriate treatment planning. The case presented in this paper is an example of severe dilacerations of a maxillary central incisor which has been treated with early orthodontic intervention.

Key Words: Tooth; Impacted; Single upper central incisor; Space Maintenance; Orthodontic

Introduction

Dilaceration is most appropriately defined as an abrupt deviation of the long axis of either the crown or the root (1). With this definition, dilacerations are distinguished from the physiological or abnormal bending of the root (2). The etiology of dilaceration is not fully known. There are two common explanations about its causes: The most common cause of dilacerations is acute mechanical trauma to the primary tooth, which causes dilaceration of the underlying developing succedaneous permanent tooth. Another explanation refers to an idiopathic developmental disorder as the cause of dilacerations, especially in cases where there is no record of traumatic injuries (2- 4). Dilacerations may appear in both permanent and primary teeth, but according to various studies, its incidence is very low (5). While some studies report no gender preference for dilacerations, others report that women have a six times greater

risk than men (6-8). Based on periapical and panoramic radiographs, its prevalence for the maxillary central incisor was 1.3% and 0.53%, respectively (9). The prognosis of a tooth with dilacerations depends on early diagnosis, position and direction of the impacted tooth, degree of root formation, number of dilacerations, availability of space for the impacted tooth, and patient motivation (10). A dilacerated tooth can have various clinical manifestations including the lack of affected tooth eruption, over-retained primary predecessor, and apical fenestration of the buccal or labial cortical plate. It may even be asymptomatic (5). The treatment of dilacerated teeth should start early to allow the non-calcified portion of the root to develop and align itself with the already calcified crown (8).

Among treatment approaches for the management of an impacted dilacerated permanent tooth, orthodontically induced tooth eruption would be the first choice.

© 2018 Journal of Surgery and Trauma

Tel: +985632381203

Fax: +985632440488

Po Bax 97175-379

Email: jsurgery@bums.ac.ir



✉ Correspondence to:

Mahdjoube Goldani Moghadam, Assistant professor of orthodontics, department of orthodontics, faculty of dentistry, Birjand university of medical sciences, Birjand, Iran ;
Telephone Number: 0985632391703
Email Address: mahdjoube.gm@gmail.com

It helps in the maintenance of the alveolar bone width and also offers periodontal and esthetic benefits (11).

When dealing with a dilacerated impacted tooth, one must be careful. Owing to the dangers involved when moving an impacted tooth via orthodontic traction, precise planning is required (12). In the management of dilacerations, the treatment failure due to ankylosis, external root resorption, and root exposure after orthodontic traction should be taken into account (13, 14). The case which is presented in this paper, is an example of early intervention to make the eruption of a dilacerated tooth possible.

Cases

The patient was a six-year-old girl presented to the orthodontic clinic of Birjand dental school with her parents. The chief complaint was eruption of the left maxillary central incisor toward the lip (figure 1). The child had no history of traumatic injury. A panoramic view was ordered to evaluate the displaced tooth (figure 2). The radiography showed severe dilacerations at the cements enamel junction.

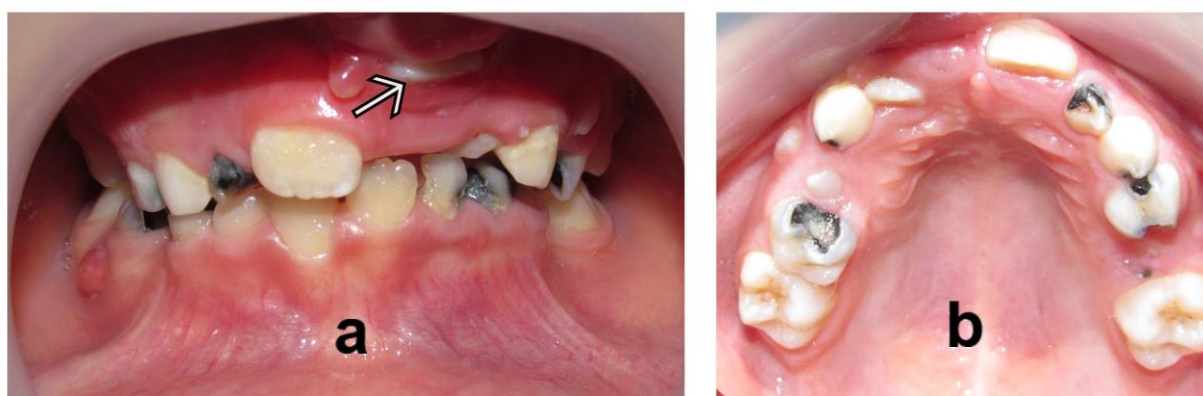

Figure 1: the pre- treatment intra- oral images, anterior view, the arrow points out the dilacerated tooth (a), occlusal view (b).

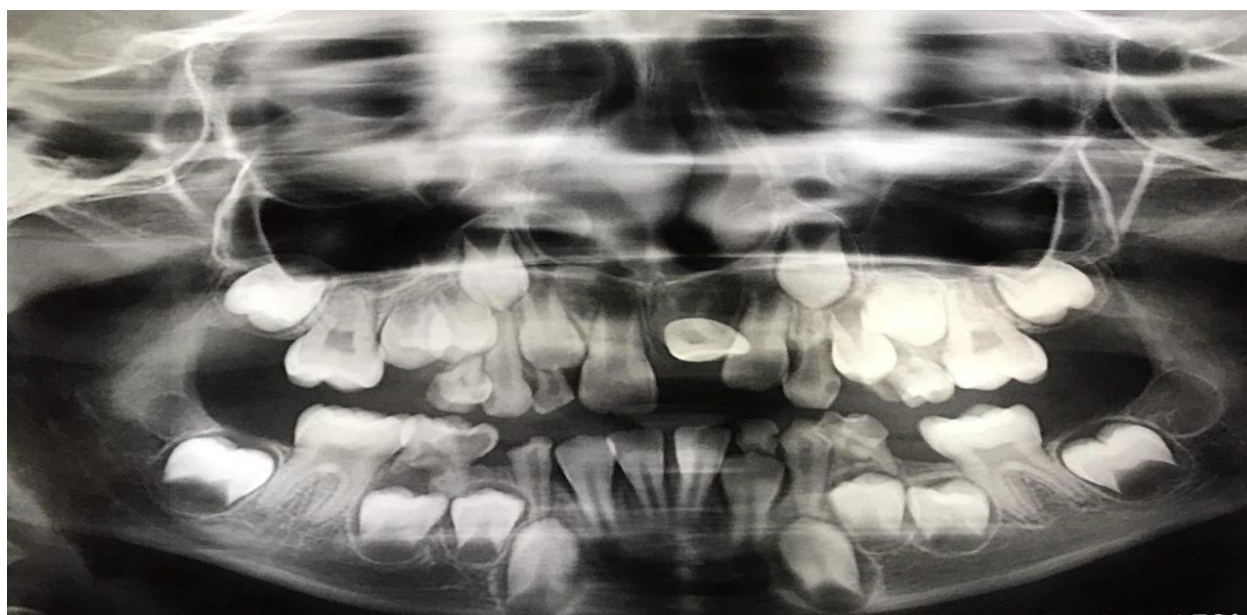


Figure 2: the pre- treatment panoramic view showed severe dilacerations at the cements enamel junction

The treatment options were reviewed and it was decided to align the tooth orthodontically. The orthodontic treatment of the maxillary arch was begun using fixed appliances including bands on the upper molars and brackets on the upper right central incisor and upper left lateral incisor teeth.

The eruption path of the dilacerated tooth (upper left central incisor) was corrected within five months (figure 3). A post treatment panoramic was taken which revealed the correction of the eruptive pass though the dilacerations still was evident (figure 4).

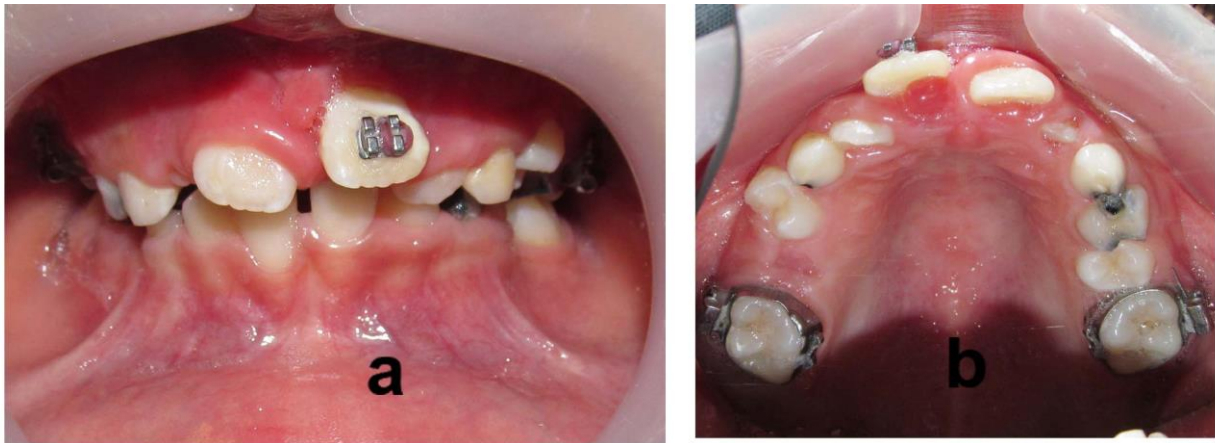

Figure 3: the post- treatment intra- oral images, anterior view, the eruption pass of the dilacerated tooth has been corrected(a), occlusal view (b).

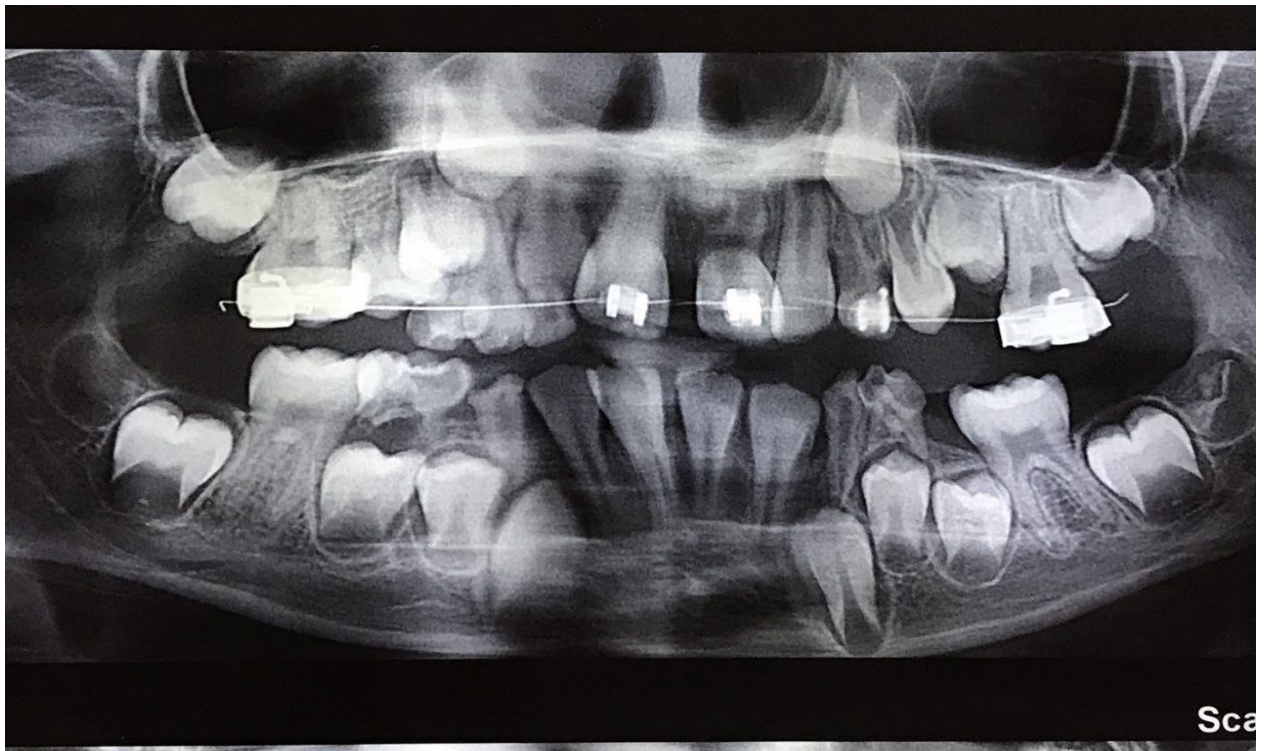


Figure 4: the post treatment panoramic revealed the correction of the eruptive pass though the dilacerations still is evident

Discussion

Dilaceration is an abnormality that results from an inappropriate spatial relationship between the uncalcified and already calcified portions of a developing tooth (15). The etiology of incisor dilacerations has not yet been fully understood. It has been shown that traumatic injuries and obstructive causes lead to the impaction of maxillary central incisors. In addition, improper oral habits—such as nail biting and finger sucking—may contribute to tooth impaction (16).

The most acceptable cause of dilaceration is acute mechanical trauma to the primary tooth, which causes dilaceration of the underlying developing succedaneous permanent tooth. But in the presented case, the parents did not remember a history of trauma. Therefore, the possible causes inducing a dilacerated root in the present case may be an ectopic development and an abnormal position of the tooth bud.

In a study by Stewart, who examined 41 patients with impacted dilacerated maxillary central incisors, only 22% had a history of trauma (7).

The impacted teeth cause concern among parents who have children in the early mixed dentition stage of growth, owing to the non-eruption of the anterior teeth (17, 18). In radiography, the unerupted dilacerated tooth is foreshortened coronally. Clinically, the maxillary incisors are deviated lingually while the mandibular incisors incline labially (19).

McNamara et al. showed that the probability of successful outcomes increases if the treatment of the dilacerated incisor starts early, so that the epithelial root sheath can be redirected and the root develops in the correct spatial relation of the aligned crown (8).

Several factors contribute to the prognosis of an impacted dilacerated tooth aligning. Among them are: a) the position and direction of the impacted tooth, b) the degree of root formation, c) the degree of dilacerations, and d) the available space for the impacted tooth (10).

When a dilacerated tooth has an obtuse inclination angle and a lower position in relation to the alveolar crest, combined with incomplete root formation, the prognosis for orthodontic traction is improved (20). In the present case, the patient was referred in the early mixed dentition phase and root development was incomplete.

Two different treatment approaches are used for the management of an impacted dilacerated permanent tooth: 1) surgical exposure followed by orthodontic traction; 2) extraction and, following

that, (a) space closure by mesialization of the lateral incisor in place of the central incisor with prosthetic restoration, or (b) surgical repositioning of the impacted central incisor. Among these methods, the stimulation of tooth eruption with orthodontics should be the first choice because of its benefits (5).

Chaushu et al. reported that surgical exposure followed by orthodontic traction for an impacted central incisor is generally successful. However, that is a long-term procedure, and it is significantly affected by the initial height of the impacted tooth in the alveolar bone (21).

Orthodontic traction is performed by a button or a bracket attached to the tooth after the crown is surgically exposed. The required force is applied by either an elastomeric chain or an elastic thread tied between the button and the arch wire (22).

There are two surgical approaches for the exposure of an impacted dilacerated tooth:

1) A closed-eruption surgical technique where the flap is returned to its original location after placing the attachment on the impacted tooth (23).

2) The tooth is surgically exposed with an apically positioned flap (24) or a u-shaped flap (25).

In comparison to the closed-eruption technique, the apically positioned flap technique had more esthetically negative effects, such as increased crown length and gingival scars (26).

The present case reveals the management of a dilacerated maxillary central incisor with incomplete root development, which is diagnosed in the early mixed dentition phase. Forced eruption was decided upon as the best treatment option based on the position of the tooth and the stage of root development, even though it was a clinical challenge.

Orthodontic traction has some disadvantages because of ankylosis and external root resorption. For this reason, despite the success in treatment, sometimes the root end of the tooth is irregular (10). Therefore, it is suggested that radiographic examinations be performed during orthodontic treatment (27). Even after successful orthodontic treatment, esthetic periodontal surgery might be necessary because sometimes the final position of the gingival margin is unsuitable because of gingival recession and/or clinical crown lengthening (5).

Despite the challenges, this treatment can be successfully managed by careful planning and with the participation of a multidisciplinary team, including the pedodontist, orthodontist, maxillofacial surgeon, endodontist, and periodontist (28).

Conclusions

In conclusion, the impacted dilacerated incisor diagnosed in the early mixed dentition stage should be treated as soon as possible with the aid of orthodontic traction.

Furthermore, the non-eruption of a maxillary incisor in a child is a critical problem for the parents in terms of esthetics because of its location. The eruption of the impacted tooth gives the patient confidence to smile and enhances self-esteem, the lack of which can be a critical problem early in life.

Conflict of interest:

The authors wish to declare there is no conflict of interest

References

- Andreasen JO, Sndström B, Ravn JJ. The effect of traumatic injuries to primary teeth on their permanent successors. I. A clinical and histologic study of 117 injured permanent teeth. *Scand J Dent Res*. 1971;79(4):219-83.
- Jafarzadeh H, Abbott PV. Dilaceration: review of an endodontic challenge. *J Endod*. 2007 Sep;33(9):1025-30. DOI: 10.1016/j.joen.2007.04.013
- Topouzelis N, Tsaousoglou P, Pisoka V, Zouloumis L. Dilaceration of maxillary central incisor: a literature review. *Dent Traumatol*. 2010 Oct;26(5):427-33. doi: 10.1111/j.1600-9657.2010.00915.x.
- Smith DM, Winter GB. Root dilaceration of maxillary incisors. *Br Dent J*. 1981 Mar 3;150(5):125-7.
- Walia PS, Rohilla AK, Choudhary S, Kaur R. Review of dilaceration of maxillary central incisor: A multidisciplinary challenge. *Int J Clin Pediatr Dent*. 2016 Jan-Mar;9(1):90-8. doi: 10.5005/jp-journals-10005-1341.
- Eversole LR. Clinical outline of oral pathology: diagnosis and treatment. PMPH-USA; 2001.
- Stewart DJ. Dilacerate unerupted maxillary central incisors. *Br Dent J*. 1978 Oct 17;145(8):229-33.
- McNamara T, Woolfe SN, McNamara CM. Orthodontic management of a dilacerated maxillary central incisor with an unusual sequela. *J Clin Orthod*. 1998 May;32(5):293-7.
- Malčić A, Jukić S, Brzović V, Miletić I, Pelivan I, Anić I. Prevalence of root dilaceration in adult dental patients in Croatia. *Oral Surg Oral Med Oral Pathol Oral Radiol Endod*. 2006 Jul 31;102(1):104-9.
- Tanaka E, Hasegawa T, Hanaoka K, Yoneno K, Matsumoto E, Dalla-Bona D, et al. Severe crowding and a dilacerated maxillary central incisor in an adolescent. *Angle Orthod*. 2006 May;76(3):510-8. DOI: 10.1043/0003-3219(2006)076[0510:SCAADM]2.0.CO;2.
- Rizzatto SM, de Menezes LM, Allgayer S, Batista EL, Freitas MP, Loro RC. Orthodontically induced eruption of a horizontally impacted maxillary central incisor. *Am J Orthod Dentofacial Orthop*. 2013 Jul;144(1):119-29. doi: 10.1016/j.jajodo.2012.08.028.
- Uematsu S, Uematsu T, Furusawa K, Deguchi T, Kurihara S. Orthodontic treatment of an impacted dilacerated maxillary central incisor combined with surgical exposure and apicoectomy. *Angle Orthod*. 2004 Feb;74(1):132-6.
- Sahpira Y, Kuftinec MM. Treatment of impacted cuspids: the hazard lasso. *Angle Orthod*. 1981 Jul;51(3):203-207.
- Boyd RL. Clinical assessment of injuries in orthodontic movement of impacted teeth. I. Methods of attachment. *Am J Orthod*. 1982 Dec;82(6):478-86. doi: 10.1016/0002-9416(82)90316-5.
- British Standards Institute. Glossary for Dental Terms. UK: British Standards Institute; 1982.
- Xue JJ, Ye NS, Li JY, Lai WL. Management of an impacted maxillary central incisor with dilacerated root. *Saudi Med J*. 2013 Oct 1;34(10):1073-9.
- Tsai TP. Surgical repositioning of an impacted dilacerated incisor in mixed dentition. *J Am Dent Assoc*. 2002 Jan;133(1):61-6.
- Bishara SE, Ortho D. Impacted maxillary canines: a review. *Am J Orthod Dentofacial Orthop*. 1992 Feb 1; 101(2):159-71.
- Asokan S, Rayen R, Muthu MS, Sivakumar N. Crown dilaceration of maxillary right permanent central incisor – A case report *J Indian Soc Pedod Prev Dent*. 2004 Oct-Dec;22(4):197-200.
- Chew MT, Ong MM. Orthodontic-surgical management of an impacted dilacerated maxillary central incisor: a clinical case report. *Pediatr Dent*. 2004 Jul-Aug;26(4):341-4.
- Chaushu S, Becker T, Becker A. Impacted central incisors: factors affecting prognosis and treatment duration. *Am J Orthod Dentofacial Orthop*. 2015 Mar;147(3):355-62. doi: 10.1016/j.jajodo.2014.11.019.
- Kuvvetli SS, Seymen F, Gencay K. Management of an unerupted dilacerated maxillary central incisor: a case report. *Dent Traumatol*. 2007 Aug 1;23(4):257-61.
- Lin YJ. Treatment of an impacted dilacerated maxillary central incisor. *Am J Orthod Dentofacial Orthop*. 1999 Apr;115(4):406-9.

24. Tanaka E, Watanabe M, Nagaoka K, Yamaguchi K, Tanne K. Orthodontic traction of an impacted maxillary central incisor. *J Clin Orthod*. 2001 Jun;35(6):375-8.
25. Macías E, de Carlos F, Cobo J. Posttraumatic impaction of both maxillary central incisors. *Am J Orthod Dentofacial Orthop*. 2003 Sep;124(3):331-8. DOI: 10.1016/S0889540603003056.
26. Vermette ME, Kokich VG, Kennedy DB. Uncovering labially impacted teeth: apically positioned flap and closed-eruption techniques. *Angle Orthod*. 1995;65(1):23-32; discussion 33.
27. Cozza P, Marino A, Condo R. Orthodontic treatment of an impacted dilacerated maxillary incisor: a case report. *J Clin Pediatr Dent*. 2005 Winter;30(2):93-7.
28. Pomarico L, de Souza IP, Primo LG. Multidisciplinary therapy for treating sequelae of trauma in primary teeth: 11 years of follow up and maintenance. *Quintessence Int* 2005 Jan;36(1):71-5.