


CASE REPORT

Removal of a sharp foreign body using rigid endoscopy

Bibifatemeh Shakhsemampour¹ 

¹ Assistant Professor, Department of Anesthesiology, Faculty of Medicine, Birjand University of Medical Sciences, Birjand, Iran

Received: February 09, 2019

Revised: February 23, 2019

Accepted: March 12, 2019

Abstract

Although foreign body ingestion is a frequent incident in children, it sometimes happens accidentally in normal adults or occurs intentionally in 10% of the cases due to psychological disorders. In spite of the recent increasing use of flexible endoscopy, there is still a position for the rigid endoscopy which is suitable for the tissue biopsy and foreign body extraction. Since the rigid endoscopy provides a wide-open space, it is regarded as a great advantage to remove sharp and keen foreign bodies from the esophagus.

Key words: Esophagoscopy, Esophagus, Foreign bodies

Introduction

Foreign body ingestion is a common problem in children aged 6 months to 5 years. However, it sometimes happens in adults accidentally, and 10% of the cases occur intentionally due to psychological disorders or mental disabilities (1). In total, 70-80% of foreign bodies pass spontaneously, whereas 20% of them is extracted by endoscopy and less than 1% requires surgery for extraction (2).

Foreign body ingestion is a common event in the United States with a reported annual incidence of 100,000 cases and an estimated 1,500 deaths (3). Totally, 12% of the esophagus perforation is caused by foreign bodies with a mortality rate of 2.1%.

Previous studies revealed that the ingested foreign bodies may get stuck in the cervical esophagus (57 %), thoracic esophagus (26%), and gastroesophageal junction (17%) (3).

Cases

A teenage female aspirated a piece of glass detached from the bottom of the cup while

drinking tea. She was immediately referred to the emergency department in her neighborhood, and she was sent to a well-equipped health center after providing necessary check-ups and taking necessary images to continue the treatment. The process took 6 hours due to long distance. Her clinical symptoms excluded dyspnea, coughing, bloating, choking, stridor, and hoarseness, whereas dysphagia and odynophagia were present. Figure 1 illustrates the neck and chest X-ray. The patient was immediately transferred to the operating room and underwent oral general anesthesia. Subsequently, the largest esophagoscope with an appropriate size was chosen. A piece of glass was removed after esophageal dilation (Figure 2). Afterward, the esophagus was evaluated once again with no symptoms of perforation in this case report. However, surface erosion was observed due to the sharp edges of the object on the esophagus. A broad-spectrum antibiotic was started for the patient and she was kept nil per os for 24 hours. Additionally, the patient did not have any symptoms of esophageal perforation, and follow-up chest x-ray and CT scan proved no esophageal perforation. The patient was eventually discharged with a good general condition. A lateral neck

©2019 Journal of Surgery and
Trauma

Tel: +985632381203

Fax: +985632440488

Po Bax 97175-379

Email: jsurgery@bums.ac.ir

✉ Correspondence to:

Bibifatemeh Shakhsemampour, Assistant Professor, Department of Anesthesiology, Faculty of Medicine, Birjand University of Medical Sciences, Birjand, Iran;

Telephone Number: +989158671186

Email Address: setayesh0083@gmail.com

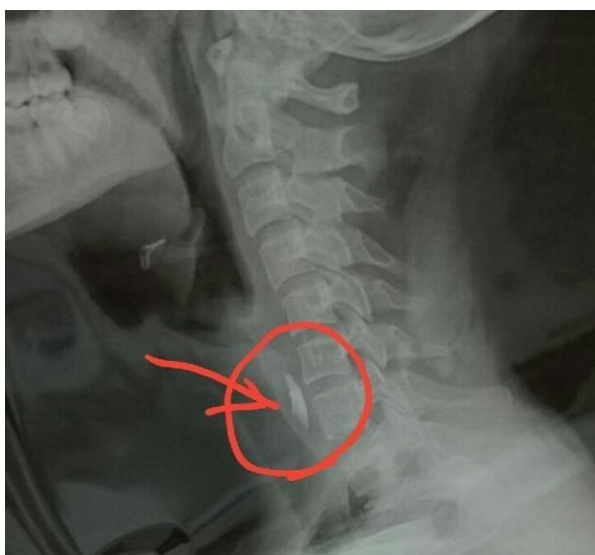

Figure 1: Neck and chest X-ray of the foreign body

radiography image was taken showing the aspirated piece of glass with high density in the area.

Discussion

Foreign body ingestion accounts for 4% of emergency endoscopies. Totally, 50% of sharp objects tend to be placed in the upper part of the esophagus that often leads to esophagus perforation (3). Ultimately, such cases undergo a rigid endoscopy or thoracotomy as well as cervical esophagotomy. The rigid endoscopy is the choice method to extract foreign bodies from the pharynx, larynx, esophagus, and trachea-bronchial tree (4).

The most common area where foreign bodies get stuck in the esophagus after cricoid is the surface of the aortic arch and the main left bronchial and diaphragm. It is possible for the flat foreign bodies to be stuck at the T1 level as well (5). In our case, the object was stuck in the cervical esophagus. Endoscopic extraction is the first-line treatment to remove a swallowed foreign body, and the surgical treatment is considered a rescuing therapy for non-extractable objects and also for the cases with clear and large perforations.

Although flexible endoscopy which is a cost-effective treatment does not require general and local anesthesia to remove objects, it has a limited impact if the object is too sharp or keen. Since the rigid endoscopy provides a wide-open space, it is regarded as a great advantage to remove sharp and keen foreign bodies from the esophagus. Moreover, it is also possible to utilize a variety of different tools by this method in

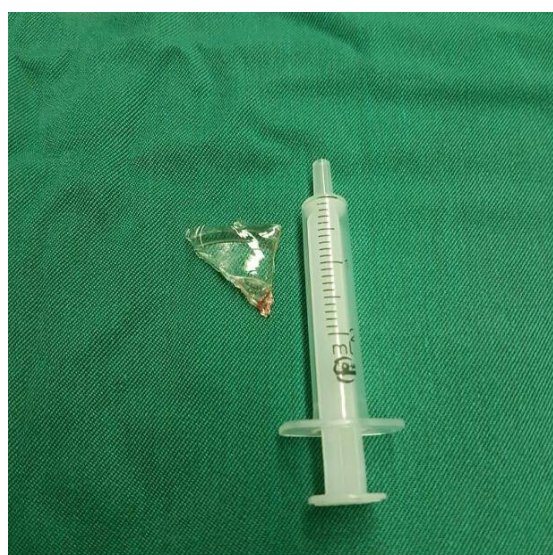

Figure 2: Removed foreign body

order to remove ingested foreign bodies. The third advantage of using the rigid endoscopy is the respiratory and aerial support provided by general anesthesia (3).

Various cases of foreign body aspirations have been reported in the esophagus, including fish bones, dentures, batteries, coins, metal wires, and toys. Out of these objects, dentures in adults and coins, as well as batteries in children, are the most common ingested foreign bodies (4, 6). In addition, other alternative methods have been proposed, such as the use of Foley and Boogie Catheters, which are not undoubtedly practical for sharp and keen objects. (7)

Objects with a diameter less than 2.5 cm or more than 5 cm are spontaneously excreted, whereas bigger or sharp foreign bodies may get stuck. In our case, the sharp object had a size of 1×1.5 cm (7). The rate of success for the rigid endoscopy is 94-100%, compared to that of 76-98.5% for the flexible endoscopy (6). In this case, the procedure was completely successful.

Conclusions

In spite of recent increasing use of flexible endoscopy, there is still a position for the rigid endoscopy which is suitable for the tissue biopsy and foreign body extraction. Since the rigid endoscopy provides a wide-open space, it is regarded as a great advantage to remove sharp and keen foreign bodies from the esophagus.

Conflict of Interest

There is no conflict of interests to be declared.

References

1. Anderson B, Karmali S. Adult glass ingestion: a case report and review of literature. *J Med Cases*. 2013; 4(8):552-4.
2. Pillai SA, Sivasankar A, Selvaraj T. Foreign bodies in the oesophagus-surgery for failed endoscopic retrieval. *Int Surg J*. 2016; 3(3):1426-30. DOI: [10.18203/2349-2902.isj20162722](https://doi.org/10.18203/2349-2902.isj20162722)
3. Ferrari D, Aiolfi A, Bonitta G, Riva CG, Rausa E, Siboni S, et al. Flexible versus rigid endoscopy in the management of esophageal foreign body impaction: systematic review and meta-analysis. *World J Emerg Surg*. 2018; 13(1):42. DOI: [10.1186/s13017-018-0203-4](https://doi.org/10.1186/s13017-018-0203-4)
4. Hussain G, Iqbal M, Hussain M, Ali S. Esophageal foreign bodies: an experience with rigid esophagoscope. *Gomal J Med Sci*. 2010; 8(2):218-20.
5. Aihole JS, Kumar P. Uncommon presentation of an unusual foreign body. *Indian J Crit Care Med*. 2017; 21(7):460-2. PMID: [28808368](https://pubmed.ncbi.nlm.nih.gov/28808368/) DOI: [10.4103/ijccm.IJCCM_436_16](https://doi.org/10.4103/ijccm.IJCCM_436_16)
6. Zanguoie M. Surgical removal of a foreign body from esophagus: in case of endoscopic removal failure. *J Surg Trauma*. 2018; 6(3):117-9.
7. Shivakumar AM, Naik AS, Prashanth KB, Hongal GF, Chaturvedy G. Foreign bodies in upper digestive tract. *Indian J Otolaryngol Head Neck Surg*. 2006; 58(1):63-8. PMID: [23120240](https://pubmed.ncbi.nlm.nih.gov/23120240/) DOI: [10.1007/BF02907744](https://doi.org/10.1007/BF02907744)