

CASE REPORT

Management of traumatically intruded permanent tooth with 30-month follow-up: A case report

Soheila Darmiani¹ 

¹Assistant Professor of Endodontics, Department of Endodontics, Faculty of Dentistry, Birjand University of Medical Sciences, Birjand, Iran

Received: August 03, 2019

Revised: September 03, 2019

Accepted: October 16, 2019

Abstract

Intrusive luxation often results in severe damage to the tooth, periodontium, and pulp tissue. Furthermore, treatment outcome is often unpredictable due to the presence of numerous injury-related variables affecting the treatment option and prognosis. The current report presents the case of a 14-year-old boy with a 9.0 mm intruded permanent right maxillary central incisor with a closed apex which was treated by orthodontic repositioning and root canal treatment with a favorable prognosis. At the last follow-up visit (30 months after the first treatment session), the tooth was asymptomatic, and radiographic examination showed normal periapical and periodontal appearance.

Key words: Orthodontic extrusion, Root canal obturation, Tooth injuries

Introduction

Intrusive luxation (intrusion), namely the most destructive kind of traumatic dental injury, is defined as an apical displacement of the tooth in its socket (1). It has been found to include 5-12% of luxation injuries and 0.3-1.9% of all traumatic injuries in the permanent dentition. Since intrusion indicates the most complex and severe injury to the dentoalveolar component, the healing sequence is complicated (1, 2). The main complications are pulp necrosis, root resorptions, and defects in marginal periodontal bone healing (3, 4). The occurrence of these healing complications are related to several treatment factors, such as period of splinting (days), repositioning method (e.g., expecting re-eruption, orthodontic, or surgical reposition), treatment delay, type of splint (rigid, semi-rigid, and flexible), and the use of antibiotics (5). Treatment strategies can be either active, by repositioning (surgical or orthodontic extrusion), or passive, by spontaneous re-eruption (4, 6). However,

the published evidence provides conflicting prognoses for these three treatment types. The protocols used by the International Association of Dental Traumatology and UK National Clinical Guidelines in Paediatric Dentistry were developed based on literature reviews and consensus meetings. In addition, the treatment decision considers the degree of intrusion and root formation, which are important confounding variables considering the treatment outcome. A systematic review conducted in 2017, suggested that when practicable, spontaneous re-eruption should be the treatment of choice. When spontaneous re-eruption is not indicated, there is no difference between orthodontic and surgical repositioning in terms of the positive outcome rates. The degree of root formation is important to the prognosis of the teeth, where teeth with incomplete root formation display a better prognosis (7). The present paper reports a case of delayed repositioning of an intruded right permanent maxillary central incisor accompanied by crown fracture.

©2020Journal of Surgery and
Trauma
Tel: +985632381203
Fax: +985632440488
Po Bax 97175-379
Email: jsurgery@bums.ac.ir

✉Correspondence to:
Soheila Darmiani, Assistant Professor of Endodontics,
Department of Endodontics, Faculty of Dentistry, Birjand
University of Medical Sciences, Birjand, Iran;
Telephone Number: +9370554413
Email Address: Soheiladarmiani@yahoo.com

Cases

A 14-year-old boy was referred to the endodontic department of Shahid Beheshti University of Medical Sciences, Tehran, Iran, with the chief complaint of pain in the upper anterior region. He had a previous history of fall at home without receiving any treatments 8 years prior to his referral. Finally, 8 years after the trauma, he visited a private dental office. After the examination, the dentist referred him to the endodontic department for managing the tooth. Although a remarkably long time had elapsed since his fall, the traumatic dental injury guidelines were followed. After the assessment of the medical history, the patient was examined for extraoral signs. He had no facial swelling, changes in skin color, facial asymmetry, limited mouth opening, and pain on palpation. Intraoral examination revealed dental traumas, including crown fracture with severe intrusive luxation of discolored right permanent maxillary central incisor. The pulp vitality tests, including electric pulp, heated gutta-percha, and Endoice tests were performed for control and traumatized teeth. In addition, the right maxillary central incisor showed no signs of vitality. Reaction to percussion was tested by tapping non-traumatized and traumatized teeth lightly with the handle of a mouth mirror in the vertical and horizontal direction. The intruded incisor revealed normal sound upon percussion. Parallel periapical radiographs showed the widening of the periodontal ligament and crown fracture of the right maxillary incisor. The neighboring teeth had normal socket (Figure 1).

The patient and his parents were informed about treatment options. Due to severe intrusion (about 9.0 mm) without spontaneous re-eruption, the orthodontic repositioning technique was chosen. At the first visit, the endodontic intervention for the right permanent maxillary incisor was initiated. After rubber dam placement, the root canal became accessible. Working length was determined using an electronic apex locator (Raypex 6, VDW, Germany) and the necrotic pulp tissue was removed with the help of crown down technique and copious irrigation with 0.5% sodium hypochlorite (Cerkamed). The canal was then filled with a calcium hydroxide-iodoform paste (Metapex; Meta Biomed Ltd, Cheongju, Chungbuk, Korea) for 7 days.

Since the patient had a papillary type of labial frenum attachment, frenectomy with diode laser was selected for the management. Surgery was performed using a diode laser (Picasso, AMD Lasers) of 810 nm wavelength at the power of 0.8 W in continuous mode (Figure 2). Prior to the laser excision procedure, 0.5 mL of 2% lidocaine without adrenaline was injected to the frenum. The laser fiber tip was used in a contact mode and moved from the base to the apex of the frenum, thereby excising it. Any remaining fiber over the periosteum was removed by gently sweeping the laser tip. Moreover, no suture was needed. The procedure was performed by an operator who has been trained in laser-assisted oral surgery.

Since the root canal treatment was initiated more than 10 days after the trauma, long-term dressing with densely packed calcium hydroxide was chosen until the tooth erupted in the right

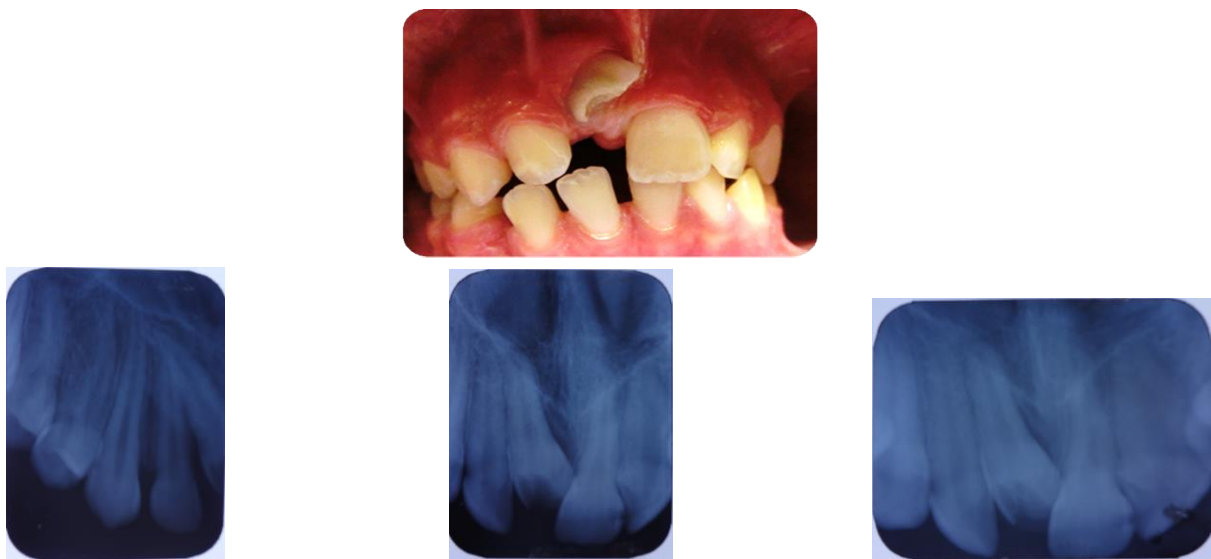


Figure 1: Intraoral and radiographic examinations 8 years after the trauma

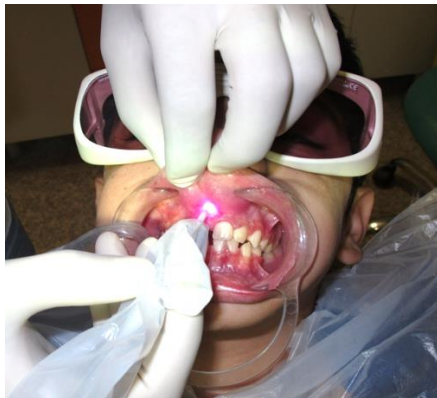

Figure 2: Frenectomy using a diode laser

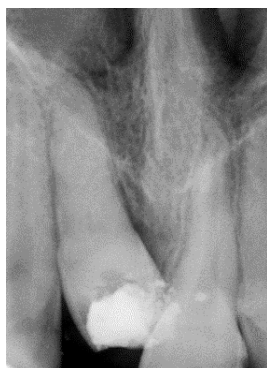
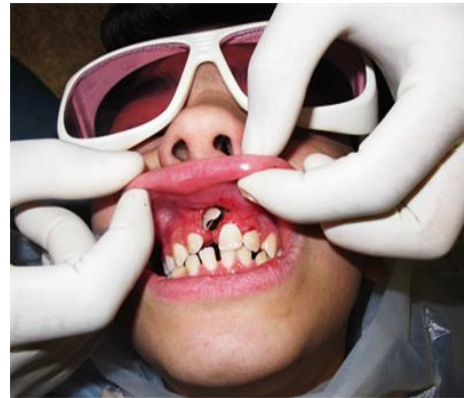
Figure 3: Root canal filled with densely packed calcium hydroxide

position (8). Once filled, the canal radiographically appeared to be calcified because the radiodensity of calcium hydroxide in the canal is usually similar to that of the surrounding dentine (Figure 3). The root canal dressing was checked every 3 months accompanied by the assessment of calcium hydroxide washout.

An orthodontic force was applied in order to re-erupt the tooth. The tooth was then actively orthodontically extruded. The patient was called again for control, and the condition of the right maxillary central was assessed. After 5 months, the tooth erupted in the right position and it was decided to obturate the root canal. Thereafter, calcium hydroxide was removed gently. The canal was flushed, dried, and filled with gutta-percha (Ariadent, Iran) and sealer (AH Plus, Dentsply De Trey GmbH, Germany) with lateral compaction technique (Figure 4) and restored with a light-cured resin composite (GC America, Alsip, IL, USA). It was decided to plan for clinical and radiographic controls of the treatment condition at 3, 6, and 12 months and yearly at least for 5 years. In a 30-month follow-up, the tooth had remained functional and esthetically acceptable. Moreover, the percussion sound and mobility were observed

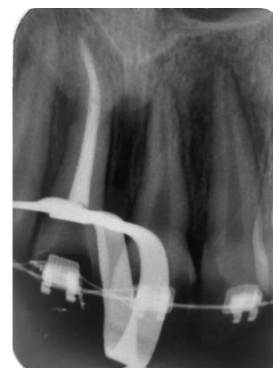

Figure 4: Radiograph during root canal obturation

to be normal. In radiographic examinations, no signs of various resorptions were detected and the adjacent anterior teeth were asymptomatic (Figure 5). The patient and his parents were satisfied with the functional and esthetic results. Although

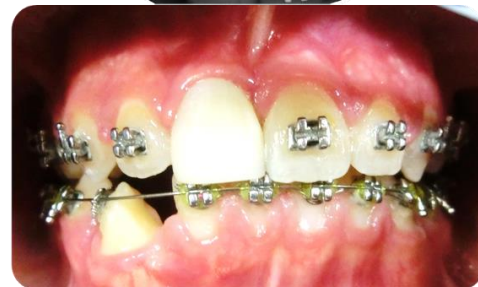
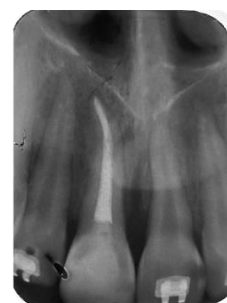
Figure 5: Intra-oral and radiographic images after 30-month follow-up

acceptable results were achieved, further annual observations are planned at least for 5 years.

Discussion

Intrusive luxation is the most severe kind of luxation injury (1). It is important to highlight that intrusive luxation is a very severe dental injury and about 30% of intruded teeth are lost after 15 years, irrespective of the stage of root development (4). Spontaneous eruption or repositioning the tooth, either surgically or by orthodontic means can be regarded as treatment strategies for intrusive luxation (3, 10). The advantages of repositioning include relief of compression zones in the periradicular area, better healing by cemental deposition rather than ankylosis (4).

Studies suggested that intrusions up to 3.0 mm have an excellent prognosis, whereas intrusions greater than 6.0 mm have a poorer prognosis with higher chances of pulp necrosis and inflammatory root resorption (8-10). In the presented case, the depth of intrusion was 9.0 mm and the intruded tooth had a closed apex, with root length completed.

For the comfort of the patient and fewer healing complications, all injuries should be treated as soon as possible. Based on the guidelines, it is recommended to treat dental intrusions within the first 24 h (6). Any treatment delay may increase the risk of healing complications (11). Costa et al. reported no difference between orthodontic and surgical repositioning in terms of the positive outcome rates when spontaneous re-eruption is not indicated (7). In the presented case, the right permanent maxillary central incisor was severely intruded with crown fracture which was left untreated for 8 years. Based on the clinical and radiographic factors, it was decided to reposition the tooth orthodontically.

It has been established that calcium hydroxide can arrest root resorption by arresting osteoclastic activity and stimulating tissue repair (11, 12). As a result, endodontic treatment was accomplished with calcium hydroxide therapy. Although acceptable results were observed, further follow-up regimen is mandatory.

In this case, the diode laser was used for frenectomy. Application of diode laser provides many clinical benefits, including administration of a reduced dose of infiltration anesthesia, bleeding control, and minimization of the post-operative swelling and pain. A laser-assisted frenectomy can be performed without or with minimal use of infiltration anesthesia, this encourages the patient co-operation during surgery (13).

Conclusions

Based on the findings of the present study, orthodontic repositioning and root canal therapy using calcium hydroxide dressing were successful in stimulating the repairing potential and arresting the healing complications associated with intrusive injuries even after delayed intervention. Further interpretations of the results need longer follow-up period.

Conflict of Interest

There are no conflicts of interest regarding the publication of the current research.

References

1. Patil AC, Patil RR. Management of intrusive luxation of maxillary incisors with dens in dente: a case report. *Dent Traumatol.* 2010; 26(5):438-42. [PMID: 20636362](#) [DOI: 10.1111/j.1600-9657.2010.00909.x](#)
2. Tsilingaridis G, Malmgren B, Andreasen JO, Malmgren O. Intrusive luxation of 60 permanent incisors: a retrospective study of treatment and outcome. *Dent Traumatol.* 2012; 28(6):416-22. [PMID: 22107160](#) [DOI: 10.1111/j.1600-9657.2011.01088.x](#)
3. Andreasen JO, Bakland LK, Matras RC, Andreasen FM. Traumatic intrusion of permanent teeth. Part 1. An epidemiological study of 216 intruded permanent teeth. *Dent Traumatol.* 2006; 22(2):83-9. [PMID: 16499631](#) [DOI: 10.1111/j.1600-9657.2006.00421.x](#)
4. Andreasen JO, Andreasen FM. Essentials of traumatic injuries to the teeth: a step-by-step treatment guide. 2nd ed. New Jersey: John Wiley & Sons; 2010. P. 103-12.
5. Andreasen JO, Bakland LK, Andreasen FM. Traumatic intrusion of permanent teeth. Part 3. A clinical study of the effect of treatment variables such as treatment delay, method of repositioning, type of splint, length of splinting and antibiotics on 140 teeth. *Dent Traumatol.* 2006; 22(2):99-111. [PMID: 16499633](#) [DOI: 10.1111/j.1600-9657.2006.00423.x](#)
6. Tzanetakakis GN. Management of intruded immature maxillary central incisor with pulp necrosis and severe external resorption by regenerative approach. *J Endod.* 2018; 44(2):245-9. [PMID: 29275849](#) [DOI: 10.1016/j.joen.2017.11.006](#)
7. Costa LA, Ribeiro CC, Cantanhede LM, Santiago Júnior JF, de Mendonça MR, Pereira AL. Treatments for intrusive luxation in permanent teeth: a systematic review and meta-analysis. *Int J Oral Maxillofac Surg.* 2017; 46(2):214-29. [PMID: 27649968](#) [DOI: 10.1016/j.ijom.2016.08.021](#)
8. Hargreaves KM, Goodis HE, Tay FR. Seltzer and Bender's Dental pulp. Chicago: Quintessence; 2012. P. 407.

9. Chacko V, Pradhan M. Management of traumatically intruded young permanent tooth with 40-month follow-up. *Aust Dent J*. 2014; 59(2):240-4. [PMID: 24861401](#) [DOI: 10.1111/adj.12164](#)
10. Al-Badri S, Kinirons M, Cole B, Welbury R. Factors affecting resorption in traumatically intruded permanent incisors in children. *Dent Traumatol*. 2002; 18(2):73-6. [PMID: 12184215](#) [DOI: 10.1034/j.1600-9657.2002.180205.x](#)
11. Kinirons MJ, Sutcliffe J. Traumatically intruded permanent incisors: a study of treatment and outcome. *Br Dent J*. 1991; 170(4):144-6. [PMID: 2007085](#) [DOI: 10.1038/sj.bdj.4807449](#)
12. Rafiee A, Moradian H, Ayatollahi M. A case-report of delayed repositioning of intruded permanent maxillary central incisors accompanied by complicated crown fractures: a 2-year follow-up. *Dent Res J (Isfahan)*. 2016; 13(5):458-61. [PMID: 27857773](#) [DOI: 10.4103/1735-3327.192310](#)
13. Viet DH, Ngoc VT, Anh LQ, Son LH, Chu DT, Ha PT, Chu-Dinh T. Reduced need of infiltration anesthesia accompanied with other positive outcomes in diode laser application for frenectomy in children. *J Lasers Med Sci*. 2019; 10(2):92-6. [PMID: 31360376](#) [DOI: 10.15171/jlms.2019.15](#)