

## Conservative management of asymptomatic hepatic hydatid cyst in pregnancy: our experience in seven patients

Mohsen Aliakbarian<sup>1</sup>, Mohammad Reza Motie<sup>1</sup>✉

<sup>1</sup>MD, Surgical Oncology Research Center, Imam Reza Hospital, Faculty of Medicine, Mashhad University of Medical Sciences, Mashhad, Iran.

Received: 20 August 2013

Revised: 20 October 2013

Accepted: 27 October 2013

### Abstract

**Introduction:** To present our experience about the safety of conservative management in asymptomatic and non-complicated hepatic hydatid cyst in pregnancy.

**Methods:** Seven pregnant patients with hepatic hydatid cysts as an incidental finding in routine obstetrical ultrasonography were referred to our center during 2001 to 2008. Three patients were visited in the second and the rest in the third trimester of their pregnancy. It was found that all of them had asymptomatic and non-complicated cysts. They were suggested to participate in our close conservative plan as their treating method. Monthly ultrasonography and clinical examination was performed to find out any changes in size or clinical course of the cysts.

**Results:** Cesarean section and simultaneous surgical treatment of the cyst were performed in three patients while for the rest went through a natural vaginal delivery and surgical treatment of the cysts were postponed until six weeks after delivery. No complication was seen in these two groups.

**Conclusions:** Conservative management of asymptomatic and non-complicated hepatic hydatid cysts until delivery may be a safe method in management of hepatic hydatid cysts in pregnancy which prevents preterm labor and other cyst related procedures complications.

**Key Words:** Hydatid disease; Pregnancy; Conservative Management

### Introduction

Hydatid disease is a zoonosis caused by *Echinococcus granulosus* in its larval stage [1]. This disease is commonly seen in the Mediterranean, South America, Australia, the Middle East, and New Zealand, and is the most common type of hydatid disease in humans [2, 3]. Different organs could be involved in hydatid disease for example the incidence of liver involvement is 50–75% and 25% of the cysts involve the lungs, while 5–10% of them distribute along the arterial system. Although hydatid disease is rare in pregnancy with an incidence of 1/20000 [4], but its management has remained as a challenge. There are some specific complications related to hydatid disease during pregnancy such as o

bstruction at delivery or preterm labor [5, 6] which may conduce to a different approach

compared to non-pregnant patients.

Different kinds of treatment have been proposed for hydatid disease in pregnancy such as open or laparoscopic surgery [7] or percutaneous treatment [8, 9] but still there is not a general consensus among authors for the treatment of choice.

This study was accomplished to investigate the efficacy and safety of conservative management for temporary management of hepatic hydatid disease in pregnancy and definitive treatment after delivery.

### Methods

During October 2001 to December 2008, seven pregnant patients (22 to 32 years old; with the mean age of 26 years old) referred to our center due to an incidental finding of hepatic hydatid cyst



in their right hepatic lobe during routine obstetrical ultrasound examination.

Three patients were visited in the second and the rest in the third trimester of their pregnancy. The treatment options were explained to the patients, so they decided to go through the conservative management. The ultrasonographic characteristics of the cysts including size, measured volume and echogenicity were recorded in the first visit as a base line to be compared to the next ultrasonographic examinations to find out any possible changes in size or type of the cysts. Medical treatment with Albendazole was started for all of them. The patients were followed up by monthly clinical examination and ultrasonography.

At the time of delivery, three patients with a history of previous cesarean section (C/S) became candidate for one staged operation, in which C/S and partial cystectomy with capitonage were accomplished through separate Pfannenstiel and subcostal incisions. The rest were allowed to have natural vaginal delivery and surgical management of the cysts was postponed until 6 weeks after

delivery when partial cystectomy and capitonage were done.

We also send a written statement for gynecologic surgeons and obstetricians to inform them about the probable risk of hydatid cyst rupture during the procedure of delivery so the imminent danger in case of upper abdominal compression during vaginal delivery or C/S.

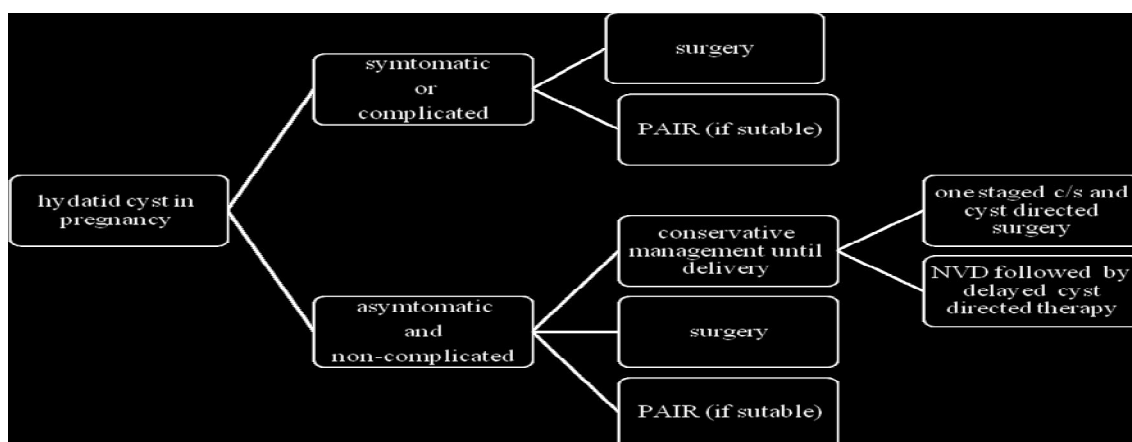
## Results

All of the patients were followed up for six months after delivery or surgery. According to Gharbi classification [10], four patients had type I (purely fluid collection), two had type II (fluid collection with a split wall) and one had type III (hydatid cysts fluid collection with daughter cysts) while none of them were involved in type IV and V of this classification (type IV: heterogeneous echo pattern, type V: cyst with thick reflecting wall).

No specific complication related to the hydatid cyst was seen during the following-up period or at the time of vaginal delivery or C/S.

**Table 1: Characteristics of the patients and their hydatid cysts**

No	Age	Type	Trimester	Initial size	Initial volume	Final size	Final volume	Treatment
1	22	I	first	7 ×8×9	263	same	205	C/S
2	28	I	second	5×6×6	78.5	7×7×8	175	NVD
3	25	II	first	10×7×8	293	8×7×6	293	C/S
4	24	I	first	8×9×9	339	same	339	NVD
5	29	III	second	3×5×4	31	5×5×5	65	C/S
6	23	I	second	6×4×6	75	4×3×3	19	NVD
7	32	II	first	6×6×6	113	4×3×3	19	NVD
Mean	26	-	-	-	170.35	-	159.28	-



**chart 1: Approach to hepatic hydatid cyst in pregnancy**

By ultrasonographic reports cysts enlargement for 2 patients, the shrinkage for 3 patients, and no changes in size for other 2 cases were detected (Table 1). We compared the length of hospital stay in two groups of the patients with NVD and C/S, in which the latter group had a longer hospitalization (4.6 vs. 3.5).

## Discussion

Management of the hepatic hydatid cyst during pregnancy is a point of debate. Among current treatments including medical treatment, surgery or PAIR, each has benefits and shortcomings. Considering the susceptibility of the fetus especially in the first trimester, medical treatment with anthelmintics like Albendazole is contraindicated in the first trimester of the pregnancy [11, 12], but although controversial it can be prescribed during second and third trimesters [13, 14].

Surgery in the first trimester also should be done with extreme caution (if at all) because of the probable risk of abortion. Although the risk of surgery in the second and third trimesters is less, preterm labor still remains a serious problem.

Puncture Aspiration Injection and Reaspiration (PAIR) is also a feasible way for treating the hydatid cysts during pregnancy [8-10], but its safety needs to be proven. Furthermore, this method may not be suitable in some patients because of unfavorable type or location of the cysts or incompetency of the patients.

Although conservative management of the hydatid cyst during pregnancy at least in theory may increase the risk of rupture, but this risk is trivial in comparison with other risks such as abortion or preterm labor.

## Conclusions

In this study, we concluded that conservative management of hepatic hydatid cyst during pregnancy and definitive treatment after delivery can be used safely and efficiently.

On this basis we propose an algorithm for management of hepatic hydatid cyst during pregnancy including alternative treatments which should be chosen according to the patient's characteristics, desires and institutional policies (Figure 1). Further studies are recommended to confirm the safety of conservative management of hepatic hydatid cyst in pregnancy.

## Reference

1. Kammerer WS, Schantz PM. Echinococcal disease. *Infectious Disease Clinics of North America* 1993; 7:605-16.
2. Pedrosa I, Saiz A, Arrazola J, Ferreirós J, Pedrosa CS. Hydatid disease: Radiologic and pathologic features and complications. *Radiographics* 2000; 20:795-817.
3. Motie MR, Ghaemi M, Aliakbarian M, Saremi E. Study of the radical vs. conservative surgical treatment of the hepatic hydatid cyst: A 10- year experience. *Indian Journal of Surgery* 2010; 72:448-52.
4. Dede S, Dede H, Caliskan E, Demir B. Recurrent pelvic hydatid cyst obstructing labor, with a concomitant hepatic primary. A case report. *The Journal of Reproductive Medicine* 2002; 47:164-6.
5. Erzurumlu K, Dervisoglu A, Polat C, Senyurek G, Yetim I, Hokelek M. Intrabiliary rupture: an algorithm in the treatment of controversial complication of hepatic hydatidosis. *World Journal Gastroenterol* 2005; 11:2472-6.
6. Kok AN, Yurtman T, Aydin NE. Sudden death due to ruptured hydatid cyst of the liver. *Journal Forensic Science* 1993; 38:978-80.
7. Fisher M, Kasis S, Oren M. Echinococcosis in pregnancy. *Harefuah* 1992; 122 (12):770.
8. Ustunsoz B, Ugurel MS, Uzar AI, Duru NK. Percutaneous treatment of hepatic hydatid cyst in pregnancy: long-term results. *Archives of Gynecology and Obstetrics* 2008; 277:547-50.
9. Ustünsöz B, Alemdaroğlu A, Bulakbaşı N, Uzar AI, Duru NK. Percutaneous treatment of hepatic hydatid cyst in pregnancy. *Archives of Gynecology and Obstetrics* 1999; 262:181-4.
10. Gharbi HA, Hassine W, Brauner MW. Ultrasound examination of the hydatid liver. *Radiology* 1981; 139:459-63.
11. Golaszewski T, Susani M, Golaszewski S, Sliutz G, Bischof G, Auer H. A large hydatid cyst of the liver in pregnancy. *Archives of Gynecology and Obstetrics* 1995; 256:43-7.
12. Kain KC, Keystone JS. Recurrent hydatid disease during pregnancy. *American Journal of Obstetrics & Gynecology* 1988; 159:1216-7.
13. Van Vliet W, Scheele F, Sibinga-Mulder L, Dekker GA. Echinococcosis of the liver during pregnancy. *International Journal of Gynecology & Obstetrics* 1995; 49:323-4.
14. Auer H, Kollaritsch H, Juptne J, Aspöck H. Albendazole and pregnancy. *Applied parasitology* 1994; 35:146-7.