



Case Report

Rehabilitation of severe burns complicated with multiple organ dysfunction syndrome in a middle-aged worker

Xiahong Li¹, Xue Wang¹, Renbiao Huang², Xiuquan Shi¹✉

¹MD, Department of Epidemiology and Health Statistics, School of Public Health, Zunyi Medical University, Zunyi, Guizhou, China

²MD, First Clinical College, Affiliated Hospital of Zunyi Medical University, Zunyi, Guizhou, China

Corresponding author:

Tel: +86-851-28643467

Email: xqshi@zmu.edu.cn

Abstract

High levels of hormones secreted by the adrenal cortex lead to hypercortisolism, among whose complications is Cushing's syndrome. Thyroid carcinoma is one of the malignant neoplasms of the thyroid gland, the most common type of which is Papillary thyroid carcinoma (PTC), which is more common in women in the age group of 30-50 years. The course of the patient's symptoms ranges from asymptomatic to foreign body sensation, dysphagia, neck swelling, and voice change. The prognosis of patients with surgical procedures is good, and the five-year survival of patients is 90%. The concurrent incidence of several diseases in one person is a rare phenomenon. The reported article is the first very rare case of Cushing's syndrome, papillary thyroid carcinoma, and renal cysts.

Keywords: Accidental Injuries, Burns, Multiple Organ Dysfunction Syndrome, Rehabilitation

Citation: Li X, Wang X, Huang R, Shi X. Rehabilitation of severe burns complicated with multiple organ dysfunction syndrome in a middle-aged worker. *J Surg Trauma*.2021; 9(1):32-36

Received: September 27, 2020

Revised: November 28, 2020

Accepted: April 17, 2021

Introduction

A report from China Health Statistics Yearbook in 2019 (1). showed that injury was the fifth leading cause of death among Chinese residents, after malignancies, heart disease, cerebrovascular diseases, and respiratory diseases. Burns are the fourth most common types of injury in the world, second only to traffic injuries, falls and interpersonal violence (2). The American Burn Association (ABA) stated that in the United States with about 329 million people, there was an estimated 40 thousand burn injury hospitalizations annually in 2016, and 30 thousands of patients were admitted to the 128 burn centers(2-4). In developing countries, burns are a public health

issue and a major cause of trauma morbidities, disabilities and deaths mainly due to undeveloped socioeconomic conditions (5). In addition to bringing pain to the patient, burns can also cause different degrees of scarring on the skin, which seriously affect the patient's physical and mental health (6). Burns are not only a catastrophic event for individuals, but also bring heavy economic burdens and a series of social problems to families and society (7).

Guizhou province, located in the southwest of China, is a predominantly mountain-rich and under developed region. Many people have to stay away from home to work outside. Due to harsh working environment and lack of

personal protective measures, they have more chance of exposure to occupational risk factors. In this report, we present a case of a middle-aged male with severe burns and multiple organ dysfunction syndrome (MODS). MODS is a serious complication of severe burn patients. Its condition is complex and progresses rapidly, which brings certain challenges to clinicians and should be highly alerted.

Case

A 52-year-old male patient was transferred to our hospital 6 day after multiple burns caused by gas pipeline explosion. The treatment was started in a local hospital with anti-infection, anti-shock and protecting organs, etc., but the condition did not improve significantly. Initial assessment revealed that he had severe burns involved in 50% total body surface area (TBSA) (including deep partial thickness and full thickness, which accounted for 32% and 18% of the TBSA, respectively). Laboratory examination results indicate that the C-reactive protein is 157.90mg/L, the White blood cells $14.16 \times 10^9/L$, and the Interleukin-6 328.500pg/ml, etc. (Table 1). Chest Computed Tomography (CT) and chest auscultation reveal bilateral pneumonia (Figure 1). Based on the history of burns and the results of routine urine tests, the patient had acute renal insufficiency. Without the use of vasoactive drugs, the patient's systolic blood pressure fluctuated in the range of 110-190 mmHg.

After admitted to intensive care unit (ICU), tracheotomy and ventilator-assisted breathing treatment were performed on the patient with acute respiratory failure, in addition to fluid resuscitation continued, anti-infection and symptomatic treatment according to both empirical judgments and microorganism cultures. For further burn treatment, he was transferred to the Department of Burns and Plastic Surgery. Based on the critical condition of the patient and the survival rate of the skin graft, the doctor performed the operation on the patient in stages. The doctor

firstly performed wound debridement, followed by 5 sessions of skin grafting with a combination of autograft and allograft. Postoperative anti-infection, continuous renal replacement therapy (CRRT) and other symptomatic treatment were conducted, while strengthening nutritional support treatment. The wounds healed without major complication, and the patient's condition improved gradually. He was transferred to the physiatry department to rehabilitation treatment on post burn days 230, including positioning, exercise training, compression garment therapy, scar release, etc. During the hospitalization, the patient complained of abdominal pain at night, and abdominal MRI+MRCP (Figure 2) and abdominal color Doppler ultrasound indicate gallstone and cholecystitis. Abdominal pain improved significantly after oral anti-inflammatory, and surgical treatment was not considered temporarily due to the stones was silt-like.

After 460 days of symptomatic treatment such as anti-infection, fluid replacement, and functional recovery, the patient recovered and was discharged. He was asked to continue comprehensive anti-scar treatments regularly, such as lasers and compression garment therapy after discharge, and at the same time strengthening functional exercises.

Discussion

Although the main cause of death after severe trauma is bleeding, many trauma victims later die due to complications such as MODS or sepsis (8). MODS remains an obstacle before achieving further improvement in survival in patients with large-area deep burns. Severe burns complicated with intestinal infection associated with endotoxemia can induce excessive inflammation, oxidative stress and high glucose stress, and promote the occurrence and development of MODS (9).

Severe burns have very few skin sources, many organ complications, and a long treatment cycle, which lead to a very difficult treatment, and if patients are not rescued in time, they are at risk of death at any time.

Table 1. Related physical examination and laboratory findings of the patient

Clinical indicators	Related values	Normal reference value
Heart rate, beats/min	104	80-100
Respiratory rate, times/min	22	12-20
Body temperature, °C	37.4	36~37
CRP, mg/L	157.90	0.068-8.2
RBC, x 1012/L	2.71	4.3-5.8
WBC, x 109/L	14.16	3.5-9.5
Neutrophils, %	0.89	0.40-0.75
Absolute neutrophils, x 109/L	12.60	1.8-6.3
Lymphocytes, %	0.05	0.20-0.50
Absolute lymphocytes, x 109/L	0.71	1.1-3.2
IL-6, pg/ml	328.500	<7.0
PCT, ng/ml	4.31	<0.05
NT-proBNP, pg/ml	4235.00	<125

Note: Abbreviations: CRP: C-reactive protein; RBC: Red blood cells; WBC: White blood cells; IL-6: Interleukin-6; PCT: procalcitonin; NT-proBNP: N-terminal B-type natriuretic peptide.

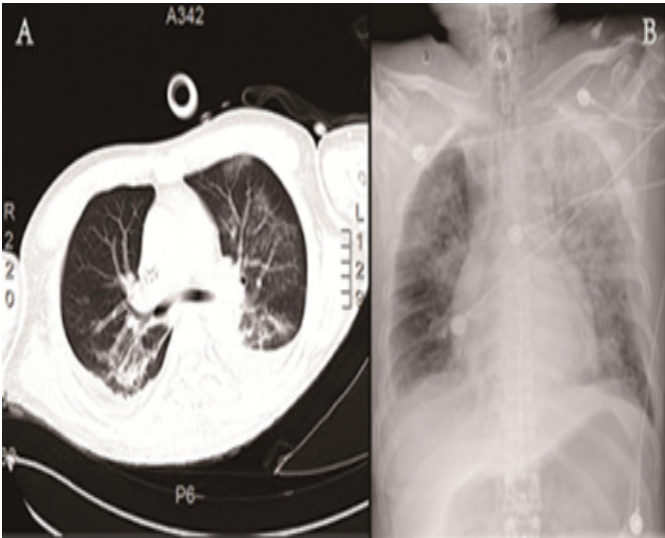


Figure 1. (A) shows multiple flaky ground glass shadows in both lungs, the lower lobes of both lungs have reduced volume, increased density, and bilateral pleural effusion. (B) shows multiple patchy high-density shadows on the chest and unclear display of the double costal diaphragm angle.

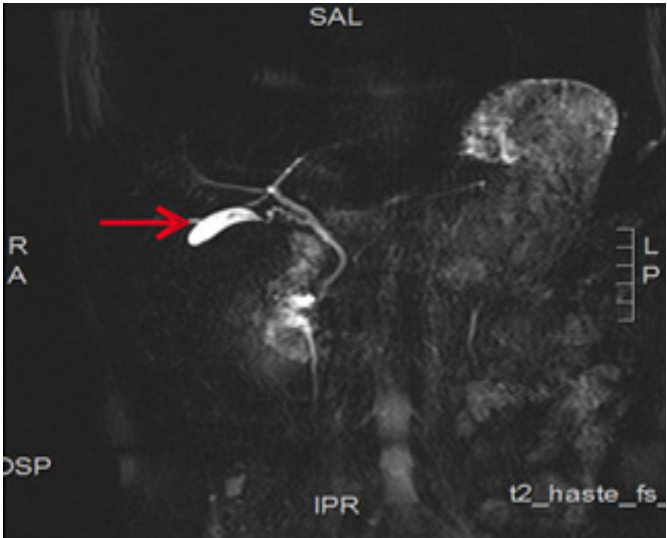


Figure 2. The bile duct system is clearly visualized, with multiple granular low signal shadows inside.

Previous study showed that extensive burn patients might undergo hypovolemic shock, followed by septic response (10). Moreover, the large amount of devitalized tissues occur invasive infection. Therefore, it is necessary to strengthen resuscitation in shock stage and prevention of infection and MODS. In this report, the patient received good first-aid treatment and was transported to ICU promptly. In order to improve the quality of shock resuscitation: the patient had acute respiratory failure, a tracheotomy was performed in time, and early ventilator support was used, so the hypoxic state was fundamentally corrected. In addition, active anti-infective, symptomatic and supportive treatments were performed for this patient, including maintenance of hemodynamic stability, nutritional support and correction of anemia

and hypoproteinemia. The effective supportive therapy is beneficial to maintain the organ function of severely burned patients, enhance the immune mechanism, control infection, and promote wound healing.

Moreover, it was worth mentioning that in this report, the burn patients underwent wound infection and systemic edema due to absorption of toxins from the wound into the blood to increase systemic vascular permeability. After the infection is initially controlled, the escharectomy and skin grafting can prevent further infection and obtain a better clinical prognosis.

However, after removing the necrotic tissue, most skin grafts neither survive nor spread on fresh wounds. It leads to more wounds after surgery and increases the risk of wound infection.

Therefore, the doctor performs the operation on the patient in stages. During the hospitalization, actively and effectively dealt with wounds promptly, and scabs were cut and allograft skin covered the wound to prevent further infection, followed by autologous skin grafting, which could increase the survival rate of skin grafts and shorten the time for wound coalescence.

Conclusion

The patients with severe burns with MODS have high risk of death, which deserves the attention of clinicians. Active and effective anti-infection and skin grafting can effectively promote wound healing. Moreover, working environment should be improved enough to ensure that the workers are free of injury, and the workers should also pay attention to self-protection.

Acknowledgement

We sincerely thank the doctors and nurses in Affiliated Hospital of Zunyi Medical University for maintenance of detailed medical records. This study was granted by National Natural Science Foundation of China (Grant No. 81560534, PI: Xiuquan Shi).

Conflict of Interest

There is no conflict of interest to be declared.

References

1. National Health Commission of the People's Republic of China. China Health Statistics Yearbook in 2019. Beijing: Peking Union Medical College Press; 2019. (in Chinese)ISBN: 978-7-5679-1323-3.
2. Legrand M, Dépret F, Mallet V. Management of burns. *N Engl J Med*. 2019;381(12):1188-1189.
3. American Burn Association. Burn incidence and treatment in the United States: 2016. .[Internet]. August 2020;Available from: <http://ameriburn.org/who-we-are/media/burn-incidence-fact-sheet>
4. Sibbald RG, Ayello EA. Deep burns: comparing the developed and developing world. *Adv Skin Wound Care*. 2019;32(1):5.
5. Wanjeri JK, Kinoti M, Olewe THAM. Risk factors for burn injuries and fire safety awareness among patients hospitalized at a public hospital in Nairobi, Kenya: A case control study. *Burns*. 2018; 44(4):962-968.
6. Garcia LP, Huang A, Corlew DS, Aeron K, Aeron Y, Rai SM,et al. Factors affecting burn contracture outcome in developing countries: areview of 2506 patients. *Ann Plast Surg*. 2016;77(3):290-296.
7. Yen CI, Chiou MJ, Kuo CF, Liao HT. Determination of risk factors for burn mortality based on a regional population study in Taiwan. *Burns*. 2018;44(6):1591-1601.
8. Hazeldine J, Naumann DN, Toman E,Davies D, Bishop JRB, Su Z.Prehospital immune responses and development of multiple organ dysfunction syndrome following traumatic injury: A prospective cohort study. *PLoS Med*. 2017;14(7): e1002338.
9. Wang Z, Chen R, Zhu Z,Zhang X,Wang S. Effects of insulin combined with ethyl pyruvate on inflammatory response and oxidative stress in multiple-organ dysfunction syndrome rats with severe burns.*Am J Emerg Med*.2016;34(11):2154-2158.

10. Wu P, Wang X, Jin R, Ho JK, Zhang L, Ding Y, et al. A 27-year follow-up for a patient with 100% total body surface area burn. *J Burn Care Res.* 2018;39(2):302-307.