

## Gallbladder volvulus: Review of the literature and report of three cases

Mostafa Mehrabi Bahar<sup>1</sup>, Mohammad Reza Motie<sup>2</sup>, Ahmad Amouzeschi<sup>3</sup>✉, Hossein Razavian<sup>4</sup>, Alireza Rezapanah<sup>4</sup>, Elena Saremi<sup>4</sup>

<sup>1</sup> Professor, Surgical Oncology Research Center, Imam Reza Hospital, Faculty of Medicine, Mashhad University of Medical Sciences, Mashhad, Iran;

<sup>2</sup> Associate Professor, Surgical Oncology Research Center, Imam Reza Hospital, Faculty of Medicine, Mashhad University of Medical Sciences, Mashhad, Iran.

<sup>3</sup> Assistant Professor, Department of General Surgery, Birjand University of Medical Sciences, Birjand, Iran;

<sup>4</sup> General Surgeon, Department of General Surgery, Mashhad University of Medical Sciences, Mashhad, Iran.

Received: 7 September 2013

Revised: 29 September 2013

Accepted: 27 October 2013

### Abstract

Torsion of the gallbladder is a relatively rare surgical disease which mimics acute cholecystitis' symptoms that usually would not be responsible to medical therapies. The torsion would mostly be diagnosed intra-operatively. Cholecystectomy is the treatment of choice. In general in our centre, General Surgery department, Imam Reza hospital, Mashhad, Iran, since 1986 over 14000 cholecystectomies have been performed and 3 cases with an underlying cause of gallbladder torsion are documented. The relative literatures reviewed so then the presentation, paraclinical findings, and the treatment of gallbladder volvulus are discussed. Gallbladder volvulus: Review of the literature and report of three cases.

**Key Words:** Gallbladder torsion; cholecystitis; cholecystectomy

### Introduction

Torsion of the gallbladder is a relatively rare disease. The disease was first described in 1898 by Wendel 1. The true incidence is not known, but over 500 cases has been reported in the last century 2. It is generally due to abdominal anatomical fixation of the gallbladder and twisting axially. The clinical presentation and laboratory findings are the same as in acute cholecystitis. Treatment consists of detorsion and cholecystectomy. We present three cases of gallbladder volvulus and clinical aspects of the disease will be reviewed.

### Cases

#### Case 1:

The first case is a 71 year old male with Coronary Artery Disease (CAD), (suffering from

right upper quadrant (RUQ) and epigastrium pain, nausea and vomiting for the last four days and a low grade fever; p

physical examination revealed tenderness in epigastrium and RUQ. Other physical findings were in normal ranges. Leukocyte count was 13100/mm<sup>3</sup>, with neutrophils as high as 84%. Serum total and direct bilirubin were in normal ranges. Liver function tests were elevated; while alkaline phosphatase was 360 IU/L.

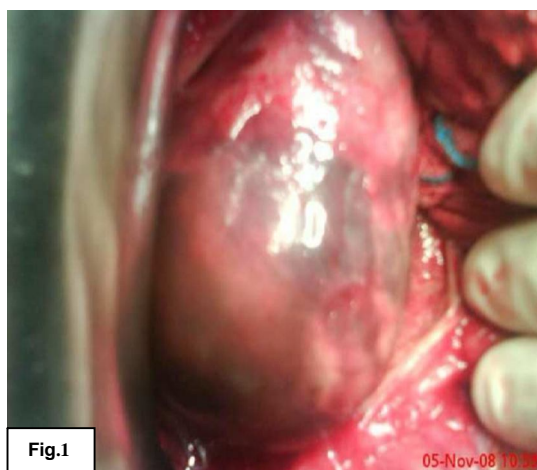
The abdominal plain films were normal. Ultrasound examination showed a large distended gallbladder with a thickened wall (5 mm) and multiple stones. Assuming acute cholecystitis as the diagnosis, the intravenous fluid, broad spectrum antibiotic and analgesic were started. Eight hours after the admission his complaints of right upper quadrant pain and muscle guarding



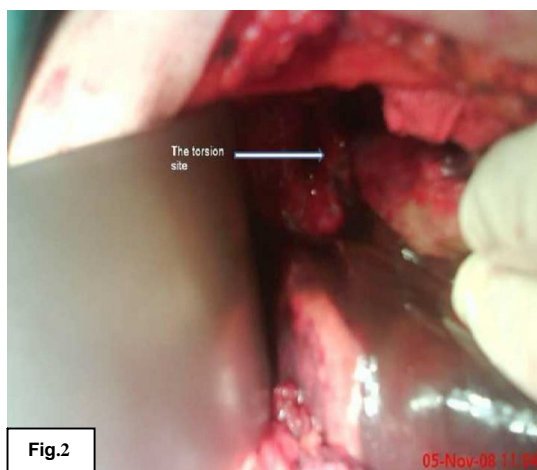had been

increased, despite analgesic therapies. Considering all these aforementioned facts along with the ultrasound findings, an emergent laparotomy was performed. At the operation he had a very large (13x8 cm), distended and gangrenous gallbladder that had rotated 180° counterclockwise.(fig.1,2,3) The mesentery of the gallbladder covered only the cystic duct and artery; and multiple large stones were found inside. The gallbladder was detorted and then excised. The pathologist reported a transmural gangrene of the gallbladder. The patient was discharged 6 days after the surgery.

#### Case 2:



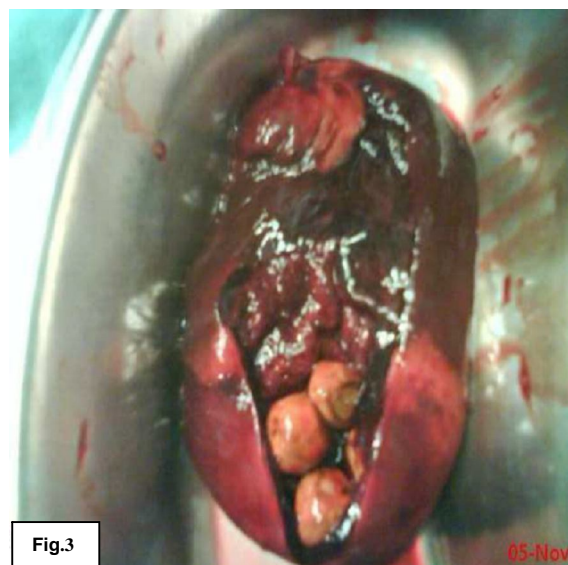
**Figure 1: Distended gallbladder intraoperatively**



**Figure 2: Torsion site is shown here**

A 67-year-old man was admitted to the emergency ward with a right upper quadrant and epigastrium pain with nausea and vomiting, which have been suddenly initiated 8 hours prior to the

time. With the exception of tenderness in epigastrium and RUQ, other physical findings were normal. A leukocyte count of 12000/mm<sup>3</sup> (PMN 94%), and normal serum total and direct bilirubin were his lab test results. The abdominal plain radiographies were normal. Ultrasound examination showed a large distended gallbladder with thickened wall (7mm) without any stones inside. Assuming acute cholecystitis as the diagnosis, intravenous fluid, broad spectrum antibiotics and analgesic were started. Because of the severe tenderness in his RUQ the patient underwent through an emergent laparotomy. The gallbladder has been rotated 180 degrees clockwise; therefore, after the detortion, it was excised. The patient was discharged 5 days after the surgery. The pathology report showed a transmural gangrene of the gallbladder.



**Figure 3: Gall stones inside the excised and opened up gallbladder**

#### Case 3:

A 56-year-old woman was admitted to the emergency ward with right upper quadrant and epigastrium pain, nausea and vomiting which had been suddenly initiated 15 hours prior to the time. With the exception of tenderness in RUQ, other physical findings were normal. The blood cell count and serum total and direct bilirubin were in normal ranges. The abdominal plain films were normal. Again, ultrasound examination showed a large distended gallbladder without any stones inside. In the same way, having acute cholecystitis as the initial diagnosis, intravenous fluid, broad spectrum antibiotics and analgesic were started. After 12 hours because of severe tenderness in RUQ,

an emergent laparotomy was performed. At the operation after detorting the distended gangrenous gallbladder, which had rotated 5270 counterclockwise, a cholecystectomy was performed. The patient was discharged 6 days after the surgery. The pathologist reported a transmural gangrene of gallbladder.

## Discussion

Generally over than 14000 cholecystectomies have been performed since 1986 in our centre, out of which these 3 cases of gallbladder torsion have been documented. Volvulus is a twist of a nonsolid organ over its mesenteric axis. The most common sources of volvulus are the sigmoid colon, cecum, and small intestine. It rarely occurs in the stomach. Gallbladder volvulus is an extremely rare disease in which immediate surgical intervention would be lifesaving. It was first described by Wendel in 1898. The true incidence is not exactly known. Eighty-five percent of gallbladder volvulus cases occur between the ages of 60 and 90 years, with a female-to-male ratio of 3:1. 3, 4, though this ratio has turned to be 1:2 in our study. Etiologically, the mechanisms leading to the torsion are poorly understood. While largely acquired and secondary to aging, GT may also be congenital. 5. Three anatomic variants are thought to be responsible for the torsion 1, 6, 7. The first one is due to a "free-floating gallbladder" suspended only by the cystic mesentery in which cystic artery acts as a vascular axis. The second one describes the gallbladder when it is hanging from the liver through an elongated, narrow-based and freely mobile mesentery due to age-related visceroptosis. The rotation occurs around an axis represented by the gallbladder itself or its liver mesentery. An extremely rare third variant consists of a normally fixed gallbladder to a mobile liver lobe free of its coronary and triangular ligaments 8.

Loss of fat and the liver atrophy that may occur with advancing age can cause an acquired elongated, narrow based gallbladder mesentery 6. Other precipitating factors are violent peristalsis of the neighboring organs, namely stomach, duodenum and colon, kyphosis, visceroptosis, atherosclerosis of the cystic artery 9, weight loss 10, constipation or diarrhoea, sigmoid volvulus 11, cholelithiasis 12, or even iatrogenic manipulation 13, intense gastric and duodenal peristalsis which will supposedly cause a clockwise torsion (51%). Peristalsis of the colon on the other hand can lead to a counterclockwise rotation (31.8%) and volvulus of the gallbladder 14, 15. In our study two of the torsions were counterclockwise. Torsion of

the gallbladder presents as an acute cholecystitis which fails to improve by conservative treatments.

This was the main clinical picture in all of our three patients. Surgeons should have high index of suspicion for a gallbladder volvulus and so proceed with prompt surgical treatment 14. An apt preoperative diagnosis of GT would rarely be made. Clinical symptoms would be nonspecific and include abdominal pain (100%), nausea and vomiting (52.7%) palpable mass (32.6%), fever (31.8%) and jaundice (0.8%) 15. If gangrene has already occurred, fever, peritonitis and ileus might also be present. If there would be an associated choledocholithiasis, or a direct compression of the common bile duct by the volvulated gallbladder, symptoms and signs related to cholestasis should occur 16.

Physical examination, which are sometimes unremarkable, usually shows non-specific right-sided findings such as guarding, tenderness, and low-grade fever. In 54% of cases a palpable gallbladder exists. 16

Laboratory investigations are not usually helpful. An elevated white blood cell count would be a frequent finding. Liver function tests are commonly normal 17. Approximately 70-80 % of patients with torsion have no gallstones 18. Although the importance of gallstones is unknown, but their presence may not play an important role in developing the gallbladder torsions 15. Volvulus interferes with blood supply and bile flow. Consequently, gallbladder wall thickening, hydrops, and finally, gangrene will develop. Ultrasonography most frequently reveals "cholecystitis" with or without cholelithiasis. A typical "square" gallbladder, which is largely scaled anteriorly and floats without gallstones, or a gallbladder outside its fossa, inferior to the liver, in a transverse orientation, with an echogenic conical structure (the twisted pedicle), is rarely seen on Ultrasonographies 7, 19.

Computed tomography scan provides similar diagnostic clues with ultrasonography which will be as the followings: the presence of gallbladder outside its fossa and inferior to the liver, pericholecystic fluid, and massively distended gallbladder with its wall thickened 20, 21. Color Doppler sonography would be helpful in differentiating the diagnoses by the mean of evaluating the gallbladder's wall blood flow. Blood flow would not be detectable in a torsive gallbladder, whereas the cystic artery along the wall could be visualized in an acute cholecystitis 15. A hydroxyiminodiacetic acid (HIDA) scans may

theoretically demonstrate twisting of the gallbladder 22, 23. It discloses focal accumulation of radioactivity (cystic duct just medial to the photopenic area: gallbladder), the so-called bulls-eye image 15, 23. Endoscopic retrograde cholangiopancreatography (ERC) demonstrates a peak-shaped cystic duct and the gallbladder would not be visualized in ERC 24,15. However scintigraphy or ERC may not be clinically suitable for patients with acute abdominal pain 16.

Magnetic resonance imaging in a GT, shows high signal intensity within the gallbladder wall on T1- weighted images (suggesting necrosis and hemorrhage) 21. The magnetic resonance cholangiopancreatography (MRCP) findings which have been defined by Usui et al. include v-shaped distortion of extrahepatic bile ducts as a result of traction by the cystic duct, tapering interruption of the cystic duct, a distended gallbladder at the end of the cystic duct which is deviated to the midline, and a difference in intensity between the gallbladder and the extrahepatic bile ducts and cystic duct 25.

Again despite all these imaging modalities, diagnosis is nearly always made during exploratory surgery. The operational treatment of GT is cholecystectomy. Other forms of surgical treatments, including cholecystopexy or visceropexy 26, 16 should be abandoned. Laparoscopic cholecystectomies for GT have been reported since 1995 27.

Percutaneous transhepatic gallbladder drainage should not be performed where there is anatomic abnormalities related to minimal fixation of the gallbladder to the liver bed 15 so that performing the percutaneous drainage may lead to a biliary peritonitis due to leakage of bile juice from the space between the liver bed and the floating gallbladder. Emergent cholecystectomy especially via laparoscopic is recommended 15, 17, 22 if gallbladder torsion is suspicious. Since the gallbladder is minimally adhered to the liver bed, laparoscopic cholecystectomy may easily and with a minimal invasion be performed 15.

Two of our patients had been operated even before the laparoscopic era. The thirds one had open surgery because of her cardiac failure.

## Conclusions

Gallbladder volvulus is a rare condition occurring in patients with "floating gallbladder" mostly in the 7th and 8th decades of life. With a high index of suspicion, it can be diagnosed preoperatively by an

ultrasonography. Laparoscopic cholecystectomy is feasible, safe and advisable, allowing a faster recovery and shorter hospital stay comparing to conventional cholecystectomy.

## References

1. Hinoshita E, Nishizaki T, Wakasugi K, Takahashi I, Onohara T, Ishikawa T, et al. Pre-operative imaging can diagnose torsion of the gallbladder: report of a case. *Hepato-gastroenterology* 1998; 46(28): 2212-5.
2. Ikematsu Y, Yamanouchi K, Nishiwaki Y, Kida H, Waki S, Okawada T, et al. Gallbladder volvulus: experience of six consecutive cases at an institute. *Journal of hepato-biliary-pancreatic surgery* 2000; 7(6):606-9.
3. Losken A, Wilson BW, Sherman R. Torsion of the gallbladder: a case report and review of the literature. *The American surgeon* 1997; 63(11): 975.
4. Stieber AC, Bauer JJ. Volvulus of the gallbladder. *The American journal of gastroenterology* 1983; 78(2): 96.
5. Gross RE. Congenital anomalies of the gallbladder a review of one. Hundred and forty-eight cases, with report of a double gallbladder. *Archives of Surgery* 1936; 32(1): 131-62.
6. McHenry CR, Byrne MP. Gallbladder volvulus in the elderly. An emergent surgical disease. *Journal of the American Geriatrics Society* 1986; 34(2): 137.
7. Schlinkert RT, Mucha Jr, PETER, FARNELL MB. Torsion of the gallbladder. In *Mayo Clinic Proceedings* 1984; 59(7): 490-2.
8. Morales AM, Tyroch AH. Wandering gallbladder. *The American Journal of Surgery* 2008; 196(2): 240-1.
9. Lai EC, Kwong WH, Chan KC, Leong HT, Lau WY. Acute torsion of the gall bladder. *ANZ journal of surgery* 2005; 75(10): 921.
10. Safadi RR, Abu-Yousef MM, Farah AS, Al-Jurf AS, Shirazi SS, Brown BP. Preoperative sonographic diagnosis of gallbladder torsion: report of two cases. *Journal of ultrasound in medicine* 1993; 12(5): 296-8.
11. Donadio F, Vajo M, La Ganga V, Campanella G, Moreno S, Granello M, Suriani R. Complicated torsion of the gallbladder. Presentation of a clinical case]. *Minerva chirurgica* 1989; 44(22): 2347.
12. Brasso K, Rasmussen OV. Gallbladder torsion. Case report. *The European journal of surgery Acta chirurgica* 1991; 157(8): 493.
13. Cave RK, Rose SC, Miller FJ. Gallbladder volvulus as a complication of percutaneous manipulation. *Journal of Vascular and Interventional Radiology* 1990; 1(1): 117-9.
14. Christoudias GC, Christoudias GC. Gallbladder volvulus with gangrene case report and review of

- the literature. *JSLs: Journal of the Society of Laparoendoscopic Surgeons* 1997; 1(2): 167.
15. Nakao A, Matsuda T, Funabiki S, Mori T, Kugochi K, Iwado T, et al. Gallbladder torsion: a case report and review of 245 cases reported in the Japanese literature. *Journal of hepatobiliary pancreat surgery* 1999;6:418-21.
  16. Marano A, Yahchouchy-Chouillard E, Spinelli R, Iannelli A, Aura T, Fingerhut A. Gallbladder torsion: report of four cases and review of the literature. *Asian Journal of Surgery* 2002; 25(2): 175-8.
  17. Shaikh AA, Anthony C, Shirley D, George S. Gallbladder volvulus: report of two original cases and review of the literature. *The American surgeon* 2005; 71(1): 87-9.
  18. Tarhan OR, Barut İ, Dinelek H. Gallbladder volvulus: review of the literature and report of a case. *Turk J Gastroenterol* 2006; 17(3): 209-11.
  19. Safadi RR, Abu-Yousef MM, Farah AS, Al-Jurf AS, Shirazi SS, Brown BP. Preoperative sonographic diagnosis of gallbladder torsion: report of two cases. *Journal of ultrasound in medicine* 1993; 12(5): 296-8.
  20. Cho YP, Kim HJ, Jung SM, Kang GH, Han MS, Jang HJ, et al. Torsion of the gallbladder: report of a case. *Yonsei medical journal* 2005; 46(6): 862-5.
  21. Aibe H, Honda H, Kuroiwa T, Yoshimitsu K, Irie H, Shinozaki K, et al. Gallbladder torsion: case report. *Abdominal imaging* 2002; 27(1): 51-3.
  22. Levene A. Acute torsion of the gall-bladder post-mortem findings in two cases. *British Journal of Surgery* 1958; 45(192): 338-40.
  23. Wang GJ, Colln M, Crossett J, Holmes RA. Bulls-eye" Image of Gallbladder Volvulus. *Clinical nuclear medicine* 1987; 12(3): 231-2.
  24. Desai HP, Gold BM, Burakoff R. Intermittent positional torsion of the gallbladder demonstrated on ERCP. *Gastrointestinal endoscopy* 1993; 39(4): 572-3.
  25. Usui M, Matsuda S, Suzuki H, Ogura Y. Preoperative diagnosis of gallbladder torsion by magnetic resonance cholangiopancreatography. *Scandinavian journal of gastroenterology* 2000; 35(2): 218-22.
  26. Merine D, Meziane M, Fishman EK. CT diagnosis of gallbladder torsion. *Journal of computer assisted tomography* 1987; 11(4): 712-3.
  27. Schroder DM, Cusumano III DA. Laparoscopic cholecystectomy for gallbladder torsion. *Surgical Laparoscopy Endoscopy & Percutaneous Techniques* 1995; 5(4): 330-4.