



Case Report

## Forgotten Migrated Intra-Uterine Contraceptive Device and its rare complication rare case report from Kashmir Valley

Yaqoob Hassan<sup>1</sup>, Tanveer Iqbal<sup>2</sup>, Shakeel Ahmad Mir<sup>3</sup>, Syed Mushtaq Ahmad Shah<sup>3</sup>

<sup>1</sup> MBBS, MS, Senior Resident Department of General and Minimal Access Surgery, Government Medical College, Srinagar, Kashmir

<sup>2</sup> MBBS, MS, Master of Chirurgiae in urology, Associate professor, Department of Urology, Government Medical College, Srinagar, Kashmir

<sup>3</sup> MBBS, MS, Professor and Head of the Unit, Department of General and Minimal Access Surgery, Government Medical College, Srinagar, Kashmir

**Corresponding Author:**

Tel: +917006563122

Email: [dryaqoobwani@gmail.com](mailto:dryaqoobwani@gmail.com)

### Abstract

The intra-uterine device (Copper T) has been widely used as contraceptive method since 1965. Due to its low cost, effective and reversible nature and long-term benefits, it is widely being used in the developing world. The intra-uterine contraceptive device (IUCD) has been linked to complications like bleeding, perforation and migration to other surrounding organs. The intra-abdomen migration of IUCD is rare but a serious complication. Even in asymptomatic cases, migrated IUCD warrants removal due to its grave complications and medico-legal issues it poses. We reported a rare case of asymptomatic migrated IUCD in a young female who presented to our department with unusual presentation. Both the husband and the subject denied any recollection of indwelling IUCD. The patient was evaluated and diagnosed, and IUCD was removed with right nephrectomy. A brief review in the context is also presented.

**Keywords:** Intrauterine Devicemigration, Female, Nephrectomy, Contraception

**Citation:** Hassan Y, Iqbal T, Mir SH.A, Shah S.M.A. Forgotten Migrated Intra-Uterine Contraceptive Device and its rare complication rare case report from Kashmir Valley. J Surg Trauma. 2022;10(2):84-88.

*Received: August 3, 2021*

*Revised: September 28, 2021*

*Accepted: January 4, 2022*

### Introduction

Long-acting reversible contraceptives, such as IUCDs, are the most widely used methods of contraception, particularly in this part of the developing world. In Asia, approximately 27% of married or in-union women use IUCD as a method of contraception. For medically eligible women, intrauterine contraceptive devices (IUCD) are a safe and cost-effective contraceptive method (1). IUCDs have several advantages, including long-term effectiveness, ease of reversal, safety in post-abortion patients, and use as emergency contraception (2). Similarly, immediate postpartum IUD insertion has been demonstrated to be safe and effective, even in women who intend to breastfeed (3-5). IUCDs are classified into three generations:

first generation (Lippe's loop), second generation containing copper or silver (T Cu -220, T Cu-380-Ag, etc.), and third generation (Mirena etc.). Cu T-380 is the most common in our part of the world. All IUCDs act primarily in the uterine cavity by creating a spermicidal intrauterine environment. IUCD migration into adjacent organs such as the colon, rectum, bladder, and so on is uncommon, but it is a serious complication of IUCD insertion (6). We present a rare case of asymptomatic forgotten IUCD migration in a patient, as well as its uncommon complication of a non-functioning kidney.

## Case

Mrs, 35-year-old female, illiterate, P3L3, normotensive, non-diabetic and euthyroid, from a rural area of Kashmir valley, was referred to our accident and emergency unit by a community health care centre with a 5-day history of colicky pain abdomen.

A detailed history was taken, including previous surgical, medical, obstetric, personal and family history. Neither the husband nor the subject reported any history of IUCD insertion. The results of a thorough general and clinical examination were unremarkable. Her pulse rate was 82bpm, B.P. =120/70 mmHg, respiratory rate 18 breaths/min, temperature 98.80F and her saturation was 96% at room air. The abdomen was soft, non-distended and non-tender. The digital rectal and pelvic examinations were remarkable.

Base line investigations including complete blood count, liver/kidney function tests, routine urine, serum electrolyte, radiography of chest, and an electrocardiogram were normal.

As a first radiological investigation, an abdomen/pelvis ultrasonography was performed, which revealed right Grade IV hydro-ureter nephrosis with thinning of renal cortex. In view of ultrasonographic evidence of Grade IV hydronephrosis (Figure 1), patient was admitted for evaluation and management to the Department of General and Minimal Access Surgery, Government Medical Surgery (GMC) Srinagar, Surgical Unit V, with Medical Record

Department Number X (Confidential). Patient was subjected to Contrast Enhanced Computed Tomography (CECT) scanning of abdomen and pelvis.

The CECT scan revealed right Grade IV hydronephrosis with dilated renal pelvis and thinned out renal cortex at mid region 1-2mm and at poles 2-3mm. No calculus, cyst or mass was seen. Right ureter was dilated up to S1-joint due to IUCD tip inserting into right ureter causing kinking of ureter, however patient was followed up to 1.5 hours and no excretion was seen on right side.

Left kidney measured 104\*47mm and was normal in size, outline and density, and had normal pelvicalyceal system and contrast excretion (Figure 2, 3, 4).

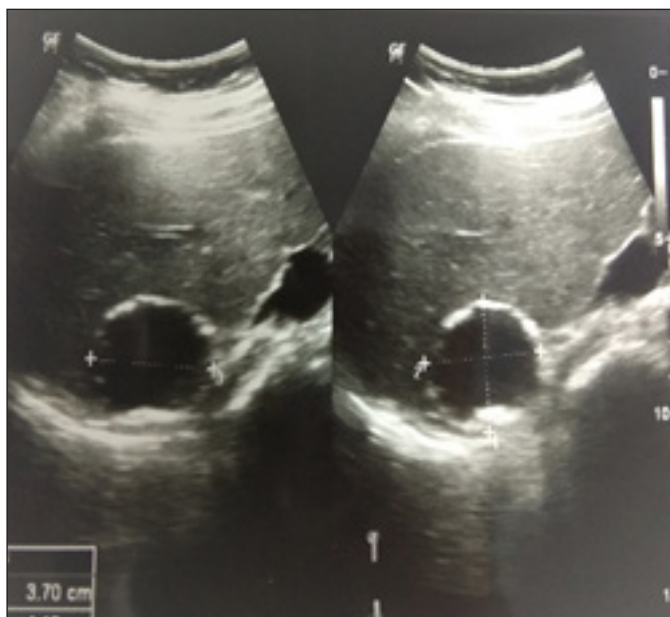Diethylenetriamine Pentaacetate (DTPA) scanning reported non-functioning right kidney. Patient was taken for surgery after pre-anesthesia clearance. After explaining the procedure, complications, and post-operative morbidities to the patient in her native language, written informed consent was obtained.

At the time of induction, a single intravenous Ceftriaxone 1gram dose was administered. During rounds, it was decided to use a transperitoneal open approach. An incision was made in the lower midline and was deepened to the general peritoneal cavity.

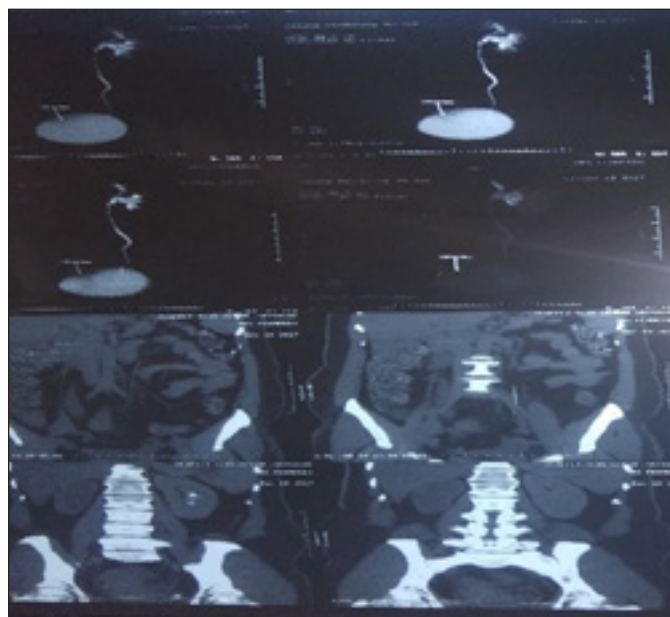
IUCD was localized and removed after meticulous dissection. A right sub-capsular nephrectomy was performed, and the specimen was sent for histopathological analysis. Foreign body (IUCD) was handed over to patient's husband. The tube drain was kept in the pelvis. The abdomen was closed back in layers, and an antiseptic dressing was applied. The patient was extubated and transferred to a ward for post-operative care. Drain was removed after 72 hours of surgery.

The intra- and post-operative periods were uneventful. The patient was discharged on the fifth post-operative day and invited for follow-up after a week to out-patient department.

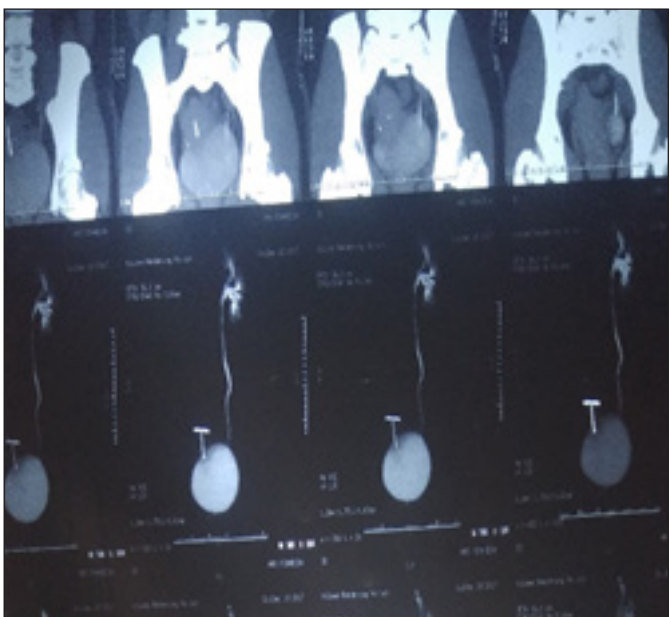After three years of follow-up, the patient is doing well.



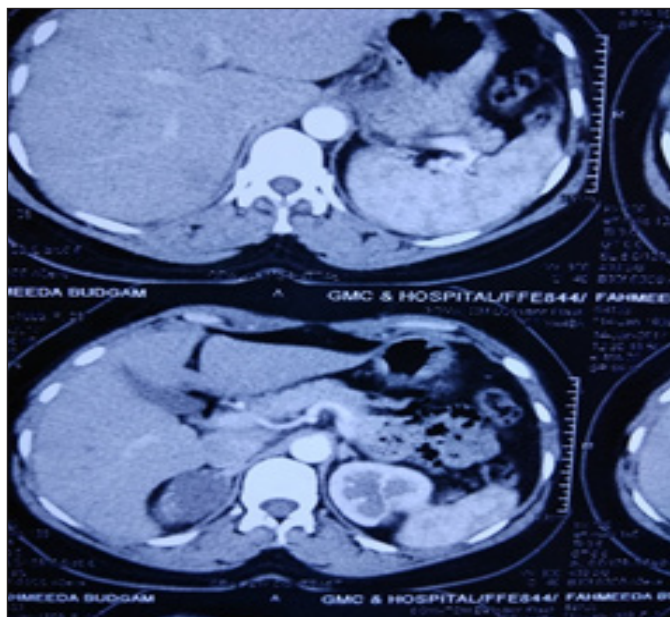
**Figure 1.** Right Grade IV Hydronephrosis.



**Figure 2.** Migrated IUCD with no excretion of contrast from right kidney



**Figure 3.** Migrated IUCD with no excretion of contrast from right kidney



**Figure 4.** Axial view section of CECT Abdomen showing Hydronephrotic right kidney.

## Discussion

Intra-uterine contraceptive devices have been widely used and regarded as one of the safest methods of contraception since 1965 (7). IUCDs are well-liked by users because they are safe, cost-effective, and reversible methods of contraception with no systemic side effects. They are not harmful to post-partum, post-abortion, or lactating mothers. Minor IUCD complications include pain during insertion, backache, dysmenorrhea, cramps, irregular periods,

spotting between periods, and heavier periods. These side effects improve over time or with the use of medications. Pelvic inflammatory disease (PID), perforation, migration, and infections are all serious but uncommon complications.

The uterine perforation is uncommon but a serious complication of IUCDs. Perforation may occur at the time of insertion or gradual pressure necrosis of uterine wall. In 1/350 to 1/2500 insertions, the uterus perforates (8). The rate of uterine perforation



is 0.3-0.6 in every 1000 users of copper IUD insertio (9-13). In addition to the insertion technique, early post-partum IUCD insertion within 12 weeks of pregnancy has been considered a commonly accepted risk factor for uterine perforation (14). In addition to the insertion technique, early post-partum IUCD insertions within 12 weeks of pregnancy have been identified as a risk factor for uterine perforation (14). A uterine perforation can be partial and asymptomatic or it can be complete and results in serious complications. After complete perforation, IUCDs can get migrated to bladder, colon, mesoappendix, mesentery, small gut, major vessels and bladder, causing variety of complications. The incidence of IUCD migrations from uterus is reported 0.5- 1 percent per 10000 users (15).

Migrated IUCDs have been reported to be the cause of appendiceal perforation (16); urinary bladder stone formation (17) or to be found embedded in omentum(15).We hereby report a case of forgotten migrated IUCD in a young illiterate patient and an associated rare complication of non-functioning kidney. What is peculiar about our case is that the patient landed up in a grave complication of non-functioning kidney, required nephrectomy and suffered life-long morbidity. We hereby recommend that well-deserved educated candidates should be chosen as users, and proper training of paramedical staff at peripheral and apex centers be made compulsory in order to provide women with safe and effective family planning options.

## Conclusion

Though IUCDs are a safe, effective, and reversible method of contraception, the educational status of the woman and her husband should be considered at the time of insertion. Patients should be invited for regular follow-up and should be stressed to check the position of IUCD on regular basis. The gynaecologist may be crucial in preventing the disastrous consequences of misplaced and migrated IUCDs. They can play an active role in their patients' decision-making, as well as in their recommendation of IUCD use in deserving subjects. Patient education about the potential benefits, side

effects, and complications of IUCDs is critical in our densely populated part of the world. Prevention is always preferable to cure.

## Conflict of interest

None.

## References

1. Ouyang M, Peng K, Botfield JR, McGeehan K. Intrauterine contraceptive device training and outcomes for healthcare providers in developed countries: A systematic review. *PloS one*. 2019;15(7):e0219746.
2. American College of O, Gynecologists. ACOG Practice Bulletin No. 121: Long-acting reversible contraception: Implants and intrauterine devices. *Obstetrics and gynecology* U6 2011;118(1):18.
3. Lopez LM, Bernholc A, Hubacher D, Stuart G, Van Vliet HA. Immediate postpartum insertion of intrauterine device for contraception. *Cochrane Database Syst Rev*. 2015 26;(6):CD003036. doi: 10.1002/14651858.CD003036.pub3. PMID: 26115018.
4. Cohen R, Sheeder J, Arango N, Teal SB, Tocce K. Twelve-month contraceptive continuation and repeat pregnancy among young mothers choosing postdelivery contraceptive implants or postplacental intrauterine devices. *Contraception*. 2016;93(2):178-83.doi: 10.1016/j.contraception.2015.10.001. Epub 2015 Oct 22. PMID: 26475368.
5. Chen BA, Reeves MF, Creinin MD, Schwarz EB. Postplacental or delayed levonorgestrel intrauterine device insertion and breast-feeding duration. *Contraception*. 2011;84(5):499-504. doi: 10.1016/j.contraception.2011.01.022. Epub 2011 Apr 16. PMID: 22018124; PMCID: PMC3202348.
6. Takahashi H, Puttler KM, Hong C, Ayzengart AL. Sigmoid colon penetration by an intrauterine device: a case report and literature review. *Mil Med*. 2014;179(1):127-129. doi: 10.7205/MILMED-D-13-00268. PMID: 24402999.
7. Zakin D, Stern WZ, Rosenblatt R. Complete and partial uterine perforation and embedding following insertion of intrauterine devices. I. Classification, complications, mechanism, incidence, and missing

string. *Obstet Gynecol Surv.* 1981;36(7):335-53. doi: 10.1097/00006254-198107000-00001. PMID: 7029368.

8. Ohana E, Sheiner E, Leron E, Mazor M. Appendix perforation by an intrauterine contraceptive device. *Eur J Obstet Gynecol Reprod Biol.* 2000 ;88(2):129-131. doi: 10.1016/s0301-2115(99)00142-6. PMID: 10690669.

9. Heinemann K, Reed S, Moehner S, Minh TD. Risk of uterine perforation with levonorgestrel-releasing and copper intrauterine devices in the European Active Surveillance Study on Intrauterine Devices. *Contraception.* 2015;91(4):274-279. doi: 10.1016/j.contraception.2015.01.007. Epub 2015 Jan 16. PMID: 25601352.

10. Caliskan E, Oztürk N, Dilbaz BO, Dilbaz S. Analysis of risk factors associated with uterine perforation by intrauterine devices. *Eur J Contracept Reprod Health Care.* 2003;8(3):150-155. PMID: 14667326

11. Harrison-Woolrych M, Ashton J, Coulter D. Uterine perforation on intrauterine device insertion: is the incidence higher than previously reported?. *Contraception.* 2003;67(1):53-56. doi: 10.1016/s0010-7824(02)00417-1. PMID: 12521659.

12. Harrison-Woolrych M, Zhou L, Coulter D.

Insertion of intrauterine devices: a comparison of experience with Mirena and Multiload Cu 375 during post-marketing monitoring in New Zealand. *N Z Med J.* 2003; 8:116(1179):1-7. PMID: 14513085.

13. Kaislasuo J, Suhonen S, Gissler M, Lähteenmäki P, Heikinheimo O. Intrauterine contraception: incidence and factors associated with uterine perforation--a population-based study. *Hum Reprod.* 2012;27(9):2658-2663. doi: 10.1093/humrep/des246. Epub 2012 Jul 3. PMID: 22763376.

14. Key TC, Kreutner AK. Gastrointestinal complications of modern intrauterine devices. *Obstet Gynecol.* 1980;55(2):239-244. PMID: 7352087.

15. Kriplani Alka, Garp Pradeep, Sharma Meenaskhi, Agarwal Nutan. Laparoscopic removal of extra uterine IUCD using fluoroscopic guidance: A case Report. *J Gynecol Surg.* 2005;21(1):29-30.

16. Carson SA, Gatlin A, Mazur M. Appendiceal perforation by Copper-7 intrauterine contraceptive device. *Am J Obstet Gynecol.* 1981;141(5):586-587. doi: 10.1016/s0002-9378(15)33284-1. PMID: 7294085.

17. Singh I. Intravesical Cu T emigration: an atypical and infrequent cause of vesical calculus. *IntUrol Nephrol.* 2007;39(2):457-459.