



Case Report

## Tooth autotransplantation of the mandibular third molar: A case report

Maryam Dalaei Moghadam<sup>1</sup>  , Forough Farahi<sup>2</sup> 

<sup>1</sup> Post Graduate Student, Department of Endodontic, Faculty of Dentistry, Zahedan University of Medical Sciences, Zahedan, Iran

<sup>2</sup> Assistant Professor of Endodontic, Department of Endodontic, Faculty of Dentistry, Zahedan University of Medical Sciences, Zahedan, Iran

**Corresponding Author:**

Tel: +989120407133

Email: [dalaei@yahoo.com](mailto:dalaei@yahoo.com)

### Abstract

Autotransplantation is a viable option for treating teeth with severe decay when a donor tooth is available. Our case was a 29-year-old female that her mandibular second molar was non restorable due to extensive root caries. After extraction of mandibular second molar, the mandibular third molar was reimplanted into the recipient site. Root canal therapy was done for the third molar after two weeks. After 15 months, clinical and radiographic examination revealed satisfactory outcome with no signs or symptoms suggestive of pathology.

**Keywords:** Second Molar, Transplantation, Wisdom Tooth

**Citation:** Dalaei Moghadam M, Farahi F. Tooth auto transplantation of the mandibular third molar: A case report. J Surg Trauma. 2021; 9(4):166-170.

*Received: August 27, 2021*

*Revised: August 29, 2021*

*Accepted: September 28, 2021*

### Introduction

Dental autotransplantation is defined as the movement of one tooth from one position to another, within the same person (1-2). It can be thought of as a controlled avulsion and re-implantation of a tooth in a new and surgically prepared socket. Furthermore, it is performed as a sterile procedure with a minimal amount of time from the donor tooth being extracted until it is sited in its recipient socket (3). Indications for tooth auto transplantation include impacted teeth, premature or traumatic tooth loss, loss of teeth because of the iatrogenic accident, congenitally missing teeth in one arch, replacement of teeth with bad prognosis, and developmental dental anomalies (4).

Autotransplantation of teeth ensures the maintenance of alveolar bone volume by physiological stimulation of the periodontal ligament (PDL) (5).

Despite the ongoing advances in dental technology and biomaterial sciences, significantly compromised permanent molars continue to pose both short- and long-term clinical dilemmas. Posterior tooth autotransplantation can be considered to be a fundamentally sound treatment option for significantly compromised molar teeth. It has been estimated that autotransplantation is 87% less costly than a restorative dental implant in private practice (6). Auto transplanted teeth, unlike prosthetic restorations, provide proprioception

during function and have a very good prognosis in growing patients (4). Many factors affect the success of tooth autotransplantation, such as the stage of root development, surgical trauma, the recipient site (local inflammation, alveolar bone volume, and quality), and the surgery procedure (stabilization method, use of intraoperative drugs, and storage) (7-9). Sufficient alveolar bone support in all dimensions with adequate attached keratinized tissue for the stabilization of the transplanted tooth are the most important criteria for the successful autotransplantation (10).

Another significant factor for successful autotransplantation is patient selection. The patient must be in good health status and have an excellent oral hygiene condition (10). This case report presents a case in whom a mandibular third molar was used to replace the mandibular second molar with a follow-up of one year (12 months).

## Case

A left lower second molar from a 29-year-old woman was compromised because of severe decay (Figure 1). Panoramic radiograph evaluation of tooth 18 (Figure 2A) showed no periapical lesion, and the crown of the second molar was severely decayed. The radiograph also showed a mesioangular tilted third molar (Figures 2A, 2B).

The patient did not have the economical possibilities to replace it with an implant and asked for a possible alternative therapy to maintain masticatory function. After getting periodontal and restorative consultation and talking to the patient, extraction was selected. There was a presence of the left lower third molar that may be used as a donor. The anatomy of the roots was almost compatible with the receiving site. Estimation of the recipient size was made well in advance during preoperative assessment with the aid of cone-beam computed tomography (CBCT).

The width and length of available bone at the recipient site should be approximate to or are slightly larger than the size of the donor (11) (Figures 2C, 2D, 2E). After explaining the procedure including the extraction of the second molar teeth and transferring the wisdom tooth to the prepared socket, the patient was asked to

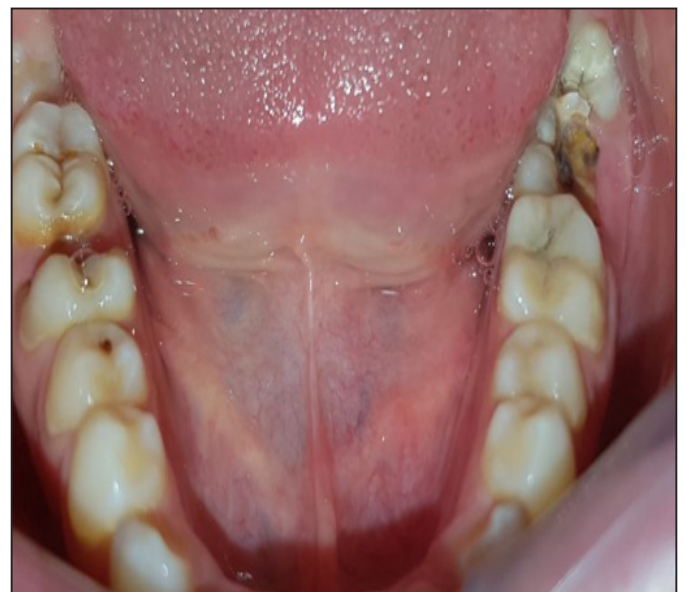sign the informed consent. The prognosis of the treatment plan was also explained. The second molar was extracted, and it was urgent to get good access to the socket and modify it. The third molar had to be extracted as traumatically as possible too and placed in moist gauze (12) till the socket modification was completed. The recipient site was prepared using surgical round burs with copious saline irrigation in a straight surgical hand piece (SAEYANG MICROTECH, MARATHON-3, Serial No.1320940, Daegu, KOREA).

Root end resection was conducted using a fissure bur, and root end preparation was performed using a taper carbide bur under gentle washing. EMcement (Bionique Dent, Tehran, Iran) retrograde filling was also performed. The third molar was transplanted, occlusion adjusted, and composite wire splinting was placed for three weeks (Figure 3A).

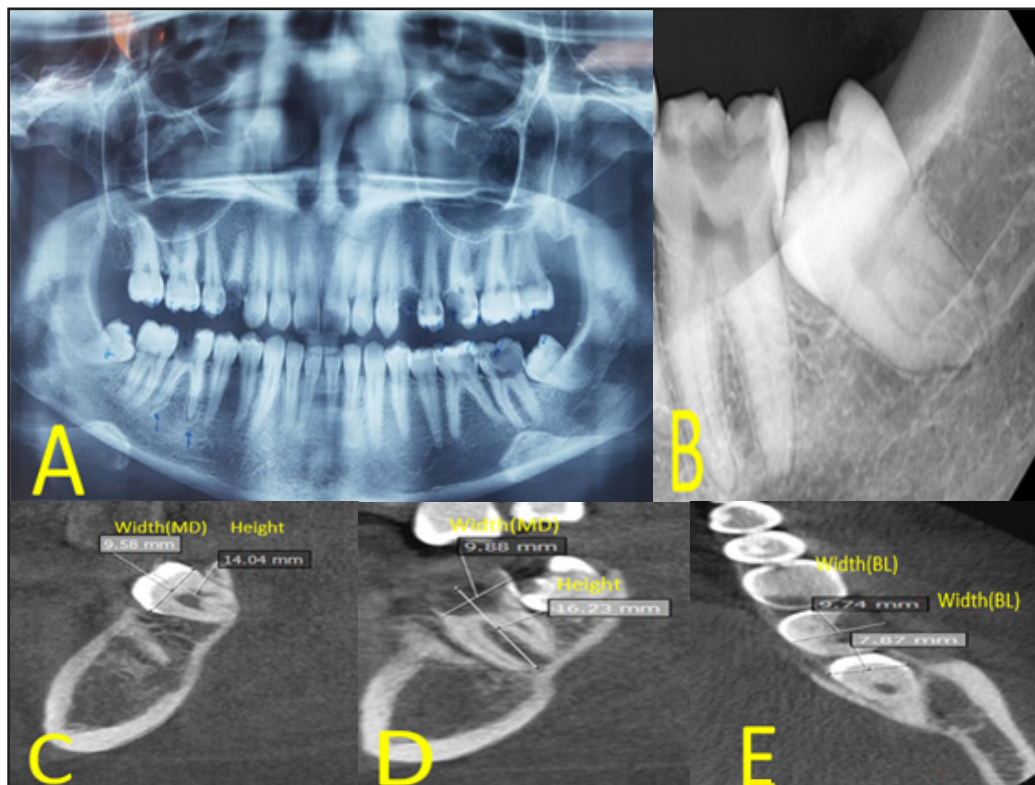
Antibiotics (Amoxicillin 1 g 2 times a day for 7 days) were prescribed, along with rinses with 0.2% chlorhexidine for two weeks.

Ibuprofen (400 mg) was prescribed to be consumed four times a day for two days after surgery to control swelling and pain.

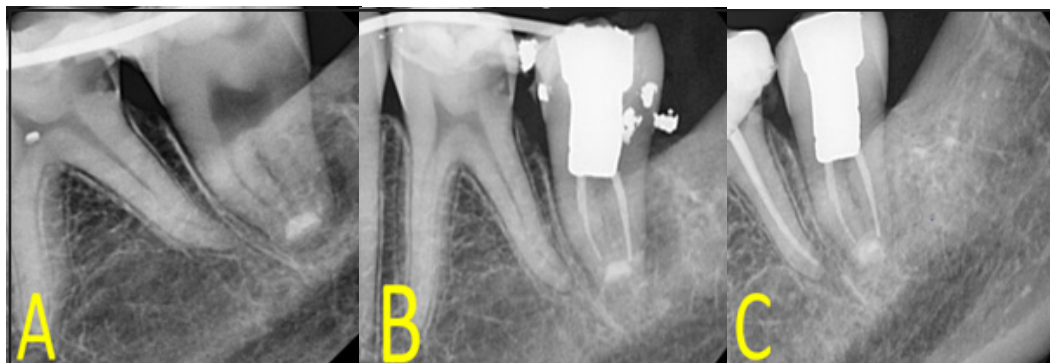
At two weeks, the root canal treatment was performed in one visit (Figure 3B). After the removal of the splint at three weeks (12), the tooth showed good stability and a positive adaptation of soft tissue. Patients showed no adverse event in a 15-month follow-up (Figure 3C).



**Figure 1.** Clinical images of the pre-operative situation of left second molar with severe decay



**Figure 2.** (A) Pre-operative panoramic showing the left third molar with mesioangular angulation. (B) Pre-op radiograph; (C, D, E) the measurements of the mesiodistal and buccolingual dimension and height of the donor tooth and recipient tooth at three different axes.



**Figure 3.** (A) Placement of splint; (B) After endodontic treatment; (C) An intraoral radiograph 15 months after transplantation

## Discussion

Auto transplantation gives the clinicians the possibility to successfully recreate all the pre-existent anatomical and functional conditions without any complication (13). Although there are many reasons for auto transplantation of teeth, tooth loss as a result of dental caries is the most common indication, especially when mandibular first and second molars are involved (14). In a systematic review, Almpiani et al. assessed the evidence concerning the complications and risk factors influencing the outcome of auto transplantation of teeth in humans. Due to the small number of the contributing studies, their

methodological limitations and the heterogeneous results reported; however, no definitive results were obtained. In the aforementioned study, root development of the donor teeth was recognized as one of the most important factors in the success of tooth auto transplantation (4). It has been shown that transplants with open apex were less likely to be lost, compared to transplants with closed apex (4). However, Bae et al. concluded that in tooth transplantation, even if the donor tooth has complete root formation, a high success rate can be achieved if the cases are selected and treated properly, which is consistent with the results of the present case report (12). In some case reports and case series



studies, mandibular third molar was transplanted to the first or second molar in humans successfully (6-12-18). The use of CBCT for postoperative monitoring of the auto transplanted teeth has also been advocated recently. The increased availability of CBCT and the reduced dose of the radiation produced, compared to spiral CT, should result in a more broad application of the method described (19). The prognosis of auto transplantation is good if the patient is healthy and able to maintain good oral hygiene. The ideal stage of donor tooth is when the root has 3/4 of its development. The ideal receptor alveolus has sufficient height and width to shelter the donor tooth. Surgical technique is meticulous and traumatic with reduced extra-alveolar time (11). The most frequently reported complications in auto transplantation of teeth include inflammatory and replacement (4). It appears that satisfactory healing in auto transplanted teeth takes place when there is no root resorption, maintenance of PDL space, and apparently normal tooth mobility (14). The most decisive factor for periodontal healing after surgical transplantation is the presence and viability of the periodontal ligament of the tooth.

Reports on the success rate of auto transplantation vary from 79% to 100% in the long-term cohort study depending on the duration of follow-up and criteria of success (11).

## Conclusion

Autogenous tooth transplantation is a procedure used in cases when the restoration is impossible due to severe dental caries. Transplantation offers other potential benefits, such as bone induction and the re-establishment of a normal alveolar process in addition to tooth replacement.

## Conflict of interest

The authors declare that there is no conflict of interest.

## Reference

1. Cohen AS, Shen T, Pogrel MA. Transplanting teeth successfully: autografts and allografts that work. *J Am Dent Assoc.* 1995;126(4):481-485.
2. Leffingwell CM. Autogenous tooth transplantation: a therapeutic alternative. *Dental survey.* 1980;56(2):22-23.
3. Amos MJ, Day P, Littlewood SJ. Autotransplantation of teeth: an overview. *Dent Update.* 2009;36(2):102-113.
4. Almpiani K, Papageorgiou SN, Papadopoulos MA. Autotransplantation of teeth in humans: a systematic review and meta-analysis. *Clin Oral Investig.* 2015;19(6):1157-1179.
5. Park JH, Tai K, Hayashi D. Tooth autotransplantation as a treatment option: a review. *J Clin Pediatr Dent.* 2010;35(2):129-135.
6. Ong DV, Dance G. Posterior tooth autotransplantation: a case series. *Aust Dent J.* 2021;66(1):85-95.
7. Andreasen J, Paulsen H, Yu Z, Bayer T, Schwartz O. A long-term study of 370 autotransplanted premolars. Part II. Tooth survival and pulp healing subsequent to transplantation. *Eur J Orthod.* 1990;12(1):14-24.
8. Andreasen J, Paulsen H, Yu Z, Schwartz O. A long-term study of 370 autotransplanted premolars. Part III. Periodontal healing subsequent to transplantation. *Eur J Orthod.* 1990;12(1):25-37.
9. Nimčenko T, Omerca G, Varinauskas V, Bramanti E, Signorino F, Cicciù M. Tooth auto-transplantation as an alternative treatment option: a literature review. *Dent Res J.* 2013;10(1):1-6.
10. Clokie CM, Yau DM, Chano L. Autogenous tooth transplantation: an alternative to dental implant placement? *J Can Dent Assoc.* 2001;67(2):92-96.
11. Mohd Mokhtar S, Abd Jalil L, Muhd Noor N. Autotransplantation of ectopic permanent maxillary incisors. *Case Rep Dent.* 2017.
12. Bae J-H, Choi Y-H, Cho B-H, Kim Y-K, Kim S-G. Autotransplantation of teeth with complete root formation: a case series. *Journal of endodontics.* 2010;36(8):1422-1426.
13. Milani S, Generali P. Tooth autotransplantation. What's the limit of our possibilities in conservative treatments?. *Giornale Italiano di Endodonzia.* 2018;32(2):86-91.
14. Chopra V, Munda H, Comert F. Autotransplantation of a mandibular third molar with complete root development-A case report. *J Dent Health Oral Disord Ther.* 2017;7(3):00243.
15. Silva MHC, Lacerda MFLS, Chaves MdGAM, Campos CN. Autotransplantation of a mandibular third molar: a case report with 5 years of follow-up. *Brazilian dental journal.* 2013;24:289-294.
16. Wu Y, Chen J, Xie F, Liu H, Niu G, Zhou L. Autotransplantation of mature impacted tooth to a fresh molar socket using a 3D replica and guided bone regeneration: two years retrospective case

series. BMC oral health. 2019;19(1):1-8.

17. Tsukiboshi M, Yamauchi N, Tsukiboshi Y. Long-term outcomes of autotransplantation of teeth: a case series. Journal of endodontics. 2019;45(12):72-83.

18. Gupta S, Goel M, Sachdeva G, Sharma B,

Malhotra D. Autotransplantation. J Conserv Dent: JCD. 2015;18(6):500-503.

19. Muhamad A-H, Nezar W, Mai A, Azzaldeen A. Tooth Autotransplantation; Clinical Concepts. J Den Med Sci. 2017;15:105-113.