



Case Report

Successful endovascular coiling of a ruptured internal iliac artery aneurysm: a case report

Lysanne Van Silfhout¹ , Wies Van Leeuwen¹, Ellen F. Dannenberg¹, Dick M. Scharn¹

¹ MD, Slingeland hospital, Doetinchem, The Netherlands

Corresponding Author:

Tel: +31623860565

Email: lysannevansilfhout@live.nl

Abstract

Ruptured internal iliac artery aneurysms (IIAA) are extremely rare, and the repair can be challenging. This case reports described an 83-year-old patient who presented at our Emergency Department with acute abdominal pain based on a ruptured IIAA. He refused open repair and only wanted to be treated as minimally invasive as possible. Therefore endovascular embolization of the IIAA was performed. Repeat angiography showed that the procedure was successful. Treatment of a ruptured IIAA by an emergency coiling procedure under local anesthesia has been shown to be effective in this reported case.

Keywords: Iliac Artery, Iliac Aneurysm, Angiography

Citation: Van Silfhout L, Van Leeuwen W, Dannenberg E.F, Scharn D.M. Successful endovascular coiling of a ruptured internal iliac artery aneurysm: a case report. J Surg Trauma. 2022;10(2):89-92.

Received: December 15, 2021

Revised: March 22, 2022

Accepted: April 18, 2022

Introduction

Iliac artery aneurysms are rare and often asymptomatic, they are usually diagnosed on radiological imaging for other conditions or in case of rupture (1). In general, iliac artery aneurysms are found in combination with an aortic aneurysm. Isolated internal iliac artery aneurysms are extremely rare and comprise less than 2% of all aneurysmal diseases (2).

Due to its location deep in the pelvis, the difficulty in exposing the distal branches, and the closely associated venous structures and ureter, repair of a (ruptured) internal iliac artery aneurysm (IIAA) can be challenging (1,3). Emergency treatment is necessary in case of a ruptured aneurysm. Open repair, as well as endovascular repair, are the two

current available methods to treat ruptured IIAA (4). There is a very limited amount of literature available on this topic, which for the most part describes results from endovascular stenting of IIAA in an elective setting. This case report addresses the successful treatment of a ruptured IIAA with endovascular coiling. Institutional Review Board approval was not required for this case report.

Case

An 83-year-old man presented at our Emergency Department with acute abdominal pain in the left lower quadrant and fainting. His medical history showed hypertension and diabetes mellitus type 2. Physical examination revealed abdominal tenderness and the patient was sweating. His blood pressure was

81/50 mmHg and his pulse rate was 84 beats/min. Bedside ultrasound showed signs of an aneurysm, however, imaging was suboptimal because of pain and further details could not be obtained. Therefore an immediately computed tomography angiography (CTA) was performed. This revealed an isolated aneurysm of the internal iliac artery with a size of 5.9 cm in diameter and a length of 2.4 cm. Extensive retroperitoneal hematoma around the iliac artery indicated a rupture (Figure A). The thoracic and abdominal aorta as well as the common iliac artery did not show signs of aneurysms.

Two treatment options were considered: open surgery or endovascular treatment. However, the patient refused any open surgery and did not want to go to the Intensive Care Unit, due to previous negative antecedents with medical treatment. Because he did

wish to attempt the endovascular treatment via a minimal approach, an embolization procedure was performed by the intervention radiologist. Digital subtraction angiography (DSA) confirmed the CTA findings and showed the IIA aneurysm without active contrast extravasation (Figure B). Using an 8-French sheath, two side branches of the internal iliac artery were embolized with a Glidecath Cobra catheter and 6 mm and 7 mm coils. The systolic blood pressure dropped during the procedure to 80-90 mmHg, after transfusion of one packed cell the blood pressure remained stable around 100-110 mmHg systolic. The procedure was continued and two Interlock coils were placed in the IIAA, the proximal internal iliac artery was embolized using a 16 mm Amplatzer plug. Repeat DSA showed a successful embolization of the IIAA (Figure C).

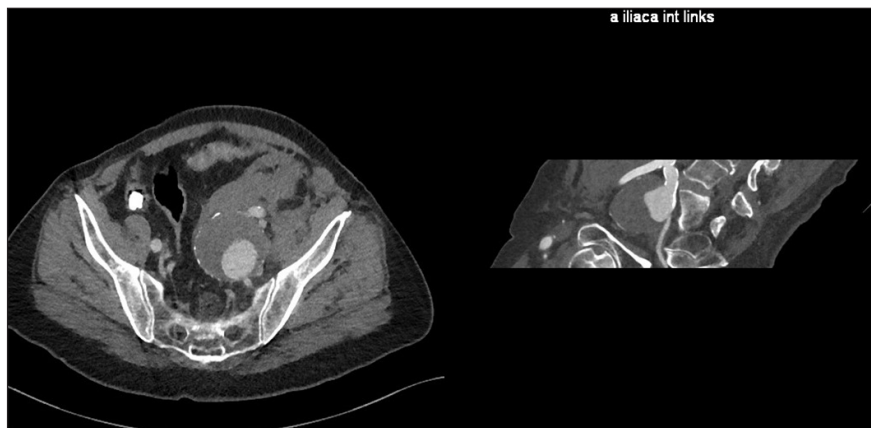

Figure A. Rupture of the IIAA with the associated retroperitoneal hematoma (both transversal and longitudinal coupe)

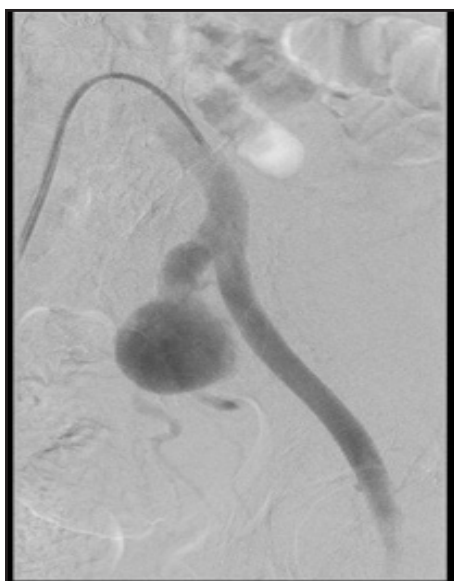


Figure B. DSA showing AII aneurysm

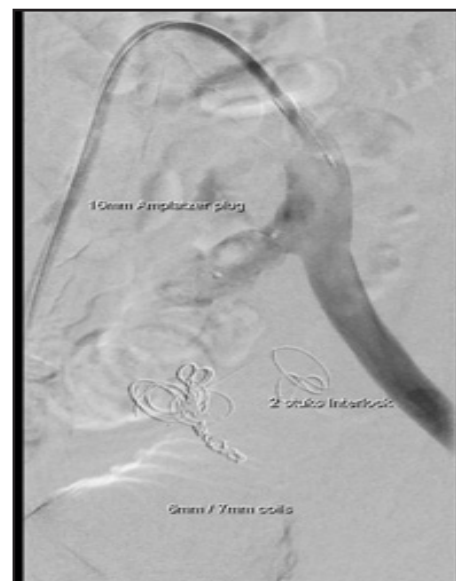


Figure C. Successful embolization with both coils and the Amplatzer plug

The patient was transferred to the surgical ward and remained hemodynamically stable overnight. Haemoglobin level remained stable as well during the next days and there were no signs of renal impairment. The patient was started on antiplatelet therapy; Acetylsalicylic acid. The postoperative phase elicited prolonged recovery, due to paralytic ileus attributed to the retroperitoneal hematoma. On the fourth day after the initial presentation, the patient was discharged from the hospital in clinically good condition.

Discussion

Ruptured IIAA are rare. Symptoms may consist of pain, hemodynamic instability, or compression of the genito-urinary system or the lumbosacral nerves(4). Emergency open surgical repair is associated with high mortality (33-50%) and morbidity due to perioperative blood loss and possible buttock or sigmoid ischemia(4-6). Compared to open repair, endovascular treatment has several advantages such as the use of local anaesthesia, fast haemostasis, and limited amount of blood loss(4).

This case report describes an 83-year-old patient who presented in our Emergency Department with a ruptured IIA. Treatment options were limited due to the refusal of the patient to consider surgical repair. Therefore the ruptured aneurysm was treated with endovascular exclusion using multiple coils in the IIAA. There were coils placed in the aneurysm sac as well as its branching vessels and the ostium of the internal iliac artery. The patient tolerated the procedure well, and was discharged home after a four-day stay in the hospital.

Several studies have reported on endovascular treatment of IIAA, however, almost all were in the elective setting. For example, in the study by Machado et al., they described among others two patients who were treated electively for their AII endovascular embolization with coils(7). Only three case reports have reported on endovascular treatment of a ruptured IIAA, all using a combination of both coils and stents to exclude the aneurysm from the circulation(1, 4, 8). To our knowledge, there has only been one other case report namely by Gupta which also describes the successful endovascular treatment of a ruptured IIAA using only coils without additional stent placement(9). This eliminates the need for suitable stent-grafts of the right size and

length and reduces the time of the endovascular procedure. Eventual coinciding negative side-effects of the coiling procedure are caused by the blocking of flow towards the regions internal iliac flow is directed. Among these, buttock claudication caused by compromising flow to the gluteal muscles, and colonic ischemia caused by diminishing the internal iliac flow, especially when the inferior mesenteric artery is no longer patent, are mentioned. Less frequently, but utterly devastating, spinal ischemia may arise, because the lumbar part of the spinal cord receives arterial radicular branches via the posterior trunks of the internal iliac arteries.

Conclusion

Occluding the inflow and outflow of a ruptured internal iliac aneurysm by an emergency coiling procedure under local anaesthesia has been shown to be effective in this reported case.

Conflicts of interest

The authors declare that they do not have any conflicts of interest.

References

1. Ricci MA, Najarian K, Healey CT. Successful endovascular treatment of a ruptured internal iliac aneurysm. *J Vasc Surg.* 2002;35(6):1274-1276.
2. Sandhu RS, Pipinos, II. Isolated iliac artery aneurysms. *Semin Vasc Surg.* 2005;18(4):209-215.
3. Soury P, Brisset D, Gigou F, Saliou C, Angel F, Laurian C. Aneurysms of the internal iliac artery: management strategy. *Ann Vasc Surg.* 2001;15(3):321-325.
4. van Kelckhoven BJ, Bruijninx BM, Knippenberg B, van Overhagen H. Ruptured internal iliac artery aneurysm: staged emergency endovascular treatment in the interventional radiology suite. *Cardiovasc Intervent Radiol.* 2007;30(4):774-777.
5. Dix FP, Titi M, Al-Khaffaf H. The isolated internal iliac artery aneurysm--a review. *Eur J Vasc Endovasc Surg.* 2005;30(2):119-129.
6. Parry DJ, Kessel D, Scott DJ. Simplifying the internal iliac artery aneurysm. *Ann R Coll Surg Engl.* 2001;83(5):302-328.
7. Machado RM, Rego DN, de Oliveira P, de Almeida R. Endovascular Treatment of Internal Iliac Artery Aneurysms: Single Center Experience. *Braz J Cardiovasc Surg.* 2016;31(2):127-131.

8. Kimura F, Ookubo R, Kobayashi D, Harada H, Baba T. Succesfull endovascular repair of a ruptured isolated iliac artery aneurysm: a case report. Clinical case reports. 2019;7(10):1880-1884.

9. Gupta AK. Endovascular coiling of ruptured internal iliac artery aneurysm in a leukemia patient - a case report. Ind J Radiol Imag. 2006;16(1):59-61.