



Case Report

## A left-sided inguinoscrotal hernia mimicking a right-sided hernia: a case report

Lysanne Van Silfhout<sup>1</sup> , Erik Staal<sup>1</sup>, Sjoerd B. Van Der Meer<sup>1</sup>

<sup>1</sup> MD, Department of Surgery, Slingeland Hospital, Doetinchem, The Netherlands

**Corresponding Author:**

Tel: +31623860565

Email: [lysannevansilfhout@live.nl](mailto:lysannevansilfhout@live.nl)

### Abstract

Inguinal hernia repair is a very common surgical procedure. To our knowledge, there are no reports of inguinal hernias crossing the midline from left to right (or vice versa). An 82-year-old man presented in our outpatient clinic with a large inguinoscrotal hernia on the right side. Medical history showed among others an open cystectomy and urostomy because of bladder cancer. He was therefore scheduled for routine repair via Lichtenstein's technique. A hernia sac was found, but further exploration revealed that its origin was not inguinal or femoral on the right side. The hernia sac crossed the midline and turned out to be from a medial inguinal hernia on the left side. This report describes a rare case of a left-sided inguinoscrotal hernia mimicking a right-sided hernia. Especially in patients with a laparotomy in their medical history, radiological imaging pre-operatively could be useful for diagnosing this rare phenomenon.

**Keywords:** Hernia, Lnguinal, Lnguinal Canal, Laparotomy

**Citation:** Van Silfhout L, Staal E, Van Der Meer S.B. A left-sided inguinoscrotal hernia mimicking a right-sided hernia: a case report. J Surg Trauma. 2022;10(3):122-124.

*Received: December 15, 2021*

*Revised: April 4, 2022*

*Accepted: June 12, 2022*

### Introduction

Inguinal hernias account for 75% of abdominal wall hernias, and the lifetime risk to develop an inguinal hernia is 27-43% for men and 3-6% for women (1,2). Repair of inguinal hernias is one of the most common operations in general surgery, a frequently used technique for this purpose is the Lichtenstein procedure (1,3). In this report, we present a patient who was scheduled for routine inguinal hernia repair according to Lichtenstein's technique of a clinically large right-sided inguinoscrotal hernia, which per-operatively turned out to originate from the left side. This case report aims to inform physicians and create awareness about this rare phenomenon.

### Case

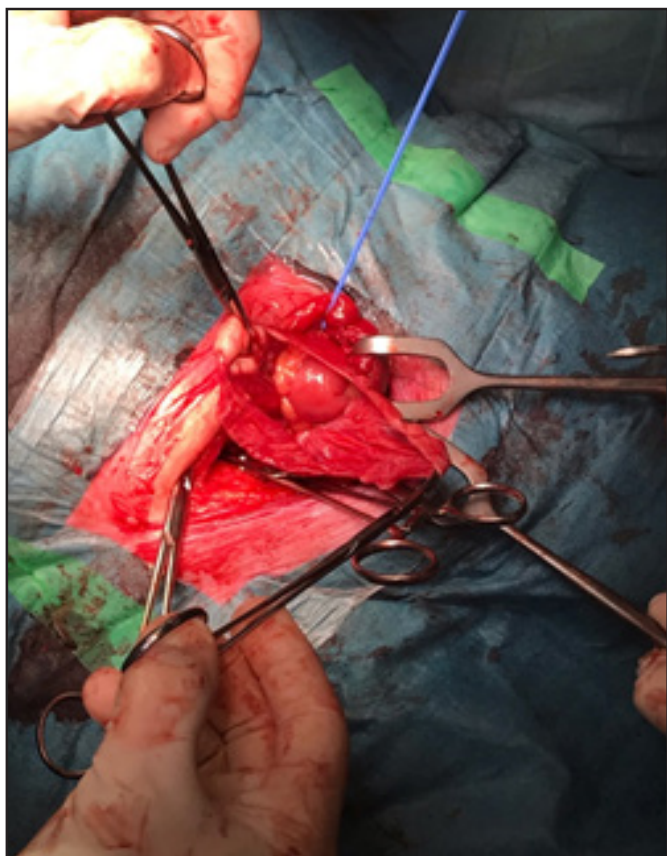
A man aged 82 years old was referred to the surgical department of our hospital by his general practitioner. The patient had a medical history of surgical treatment for bladder cancer, resulting in an urostomy, diabetes mellitus type two, gout, and angina. He complained of bulging in his right groin for one year, which was particularly unpleasant because he often used a mobility scooter. Physical examination confirmed the diagnosis of a large inguinoscrotal hernia on the right side. There was no hernia observed in the left groin

and no swelling over the pubic bone.

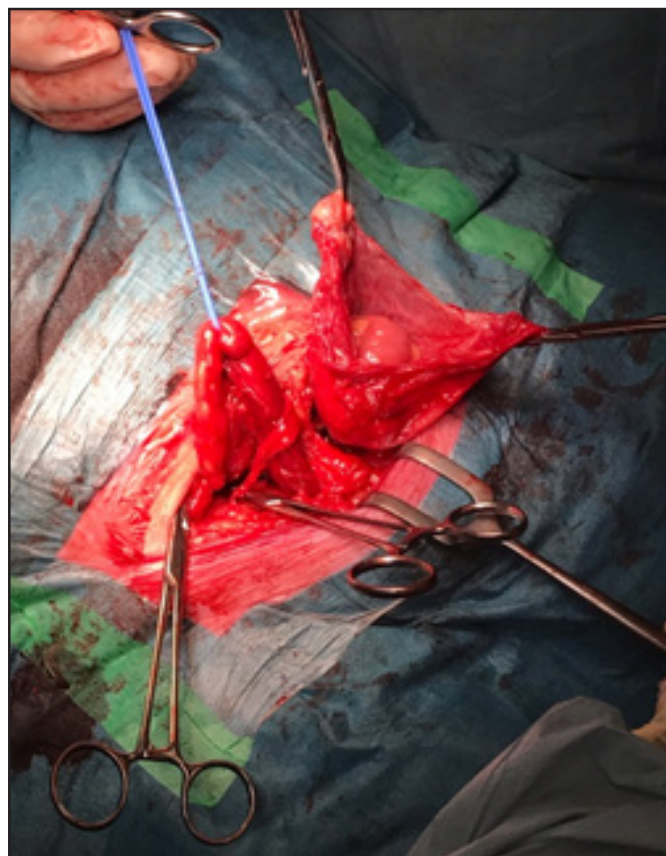
Following local and national guidelines, no radiological imaging was performed before the patient was scheduled to undergo surgical repair using Lichtenstein's technique. The surgical repair was performed under general anesthesia. The Lichtenstein technique was performed via a skin incision approximately two centimetres above Poupart's ligament. The Lichtenstein technique has been described elaborately by Amid et al.(3). After opening the external aponeurosis and inspection of the inguinal canal, there appears to be neither a lateral nor a medial inguinal hernia. We suspect it may then be a femoral hernia, and therefore explore below the level of Poupart's ligament. However, no femoral hernia is found.

that resembles a hernia sac, however, it does not lead back to the spermatic cord. Since the anatomy remains unclear, we open the sac and we find that it leads intra-abdominally and it contains small bowel. After careful dissection through adhesions and scar tissue from the cystectomy, it becomes clear that the patient has a medial inguinal hernia on the left side that moved past the pubic bone over the midline to the right side. (Figures 1, 2).

It is not possible to perform an inguinal hernia repair according to Lichtenstein on the left side. There is insufficient space for a mesh due to extensive adhesions and scar tissue. Therefore we decide partially resect the hernia sac and close it using a purse-string suture. The hernia defect is repaired using a modified Bassini's technique,



**Figure1.** The opened hernia sac contains small bowel on the right side of the patient. The blue cord loops around the right spermatic cord, which is not connected to the hernia sac.



**Figure 2.** After careful dissection through scar tissue, it becomes clear that the hernia sac originates from the left groin and crosses the midline over the pubic bone.

We decide to further explore the scrotum since there was clearly a hernia descending to the scrotum. For this purpose, the testicle is dislodged from the scrotum into the inguinal canal. There are no signs of a hydrocele testis. We do find something

which closes the hernia defect by reinforcing the transverse fascia, aponeurosis of the transverse, and the internal oblique abdominal muscles with sutures attached to Poupart's ligament. The inguinal canal on the right side was closed, before closing the sub

cutis and skin. The patient was discharged home on postoperative day one without any complications. Informed consent was obtained from the patient before writing this case report. Ethical approval is not required at our institution to publish an anonymous case report.

## Discussion

In this case report, we presented a patient with a left-sided inguinoscrotal hernia mimicking a right-sided hernia. To the best of our knowledge, there have been no other studies or case reports describing this condition. It has been described that the formation of adhesions after abdominal surgery is relatively common, and 63-97% of patients develop adhesions after abdominal or pelvic surgery; general surgery, gynaecological and urological surgery (4,5).

Therefore we hypothesize that such adhesions were also formed in our patient after undergoing both a laparotomy and a cystectomy. This then may have led to the distorted anatomy we encountered preoperatively, resulting in the unconventional presentation of a left-sided inguinal hernia.

Although a left-sided hernia rarely presents itself on the right side, physicians should keep it in mind when patients have had extensive abdominal surgery, such as in this case an open cystectomy as well as an urostomy because of bladder cancer. Ultrasound examination or computed tomography (CT) scan could play an important diagnostic role. This is consistent with the guidelines that recommend a tailored approach to inguinal hernia repair while paying attention to patient- and hernia-related factors(2). This might result in physicians considering radiological examination in patients with an extensive history of abdominal surgery,

before scheduling the patient for surgical correction of an inguinal hernia.

## Conclusion

In summary, we presented a rare case of a left-sided inguinoscrotal hernia mimicking a right-sided hernia. Although this is extremely rare, radiological imaging in patients with extensive abdominal surgery and laparotomies might be of diagnostic value and also of additional value in the pre-operative work-up.

## Conflict of interests

The authors declare to have no conflict of interests.

## References

1. Jenkins JT, O'Dwyer PJ. Inguinal hernias. *BMJ*. 2008;336(7638):269-272.
2. Köckerling F, Simons MP. Current concepts of inguinal hernia repair. *Visc Med*. 2018;34(2):145-150.
3. Amid PK, Shulman AG, Lichtenstein IL. Open "tension-free" repair of inguinal hernias: the Lichtenstein technique. *Eur J Surg*. 1996;162(6):447-453.
4. ten Broek RP, Issa Y, van Santbrink EJ, Bouvy ND, Kruitwagen RF, Jeekel J, et al. Burden of adhesions in abdominal and pelvic surgery: systematic review and met-analysis. *BMJ*. 2013;347: doi: <https://doi.org/10.1136/bmj.f5588>
5. Lier EJ, van den Beukel BAW, Gawria L, van der Wees PJ, van den Hil L, Bouvy ND, et al. Clinical adhesion score (CLAS): development of a novel clinical score for adhesion-related complications in abdominal and pelvic surgery. *Surg Endosc*. 2021;35(5):2159-2168.