



Case Report

Bilateral traumatic globe luxation after traffic accident: a case report

Sahel Soltani Shahgoli ¹  , Mansooreh Jamshidian Tehrani ² 

¹ MD, Farabi Eye Hospital, Tehran University of Medical Sciences, Tehran, Iran

² MD, Farabi Comprehensive Center of Excellence in Ophthalmology, Department of Oculofacial Plastic and Orbital Surgery, Tehran University of Medical Sciences, Tehran, Iran

Corresponding Author:

Tel: +989398462063

Email: drsahelsoltani@gmail.com

Abstract

Globe luxation resulting from traumatic incidents is an uncommon occurrence, with bilateral cases being particularly rare. This report presents a rare case of severe sinonasal trauma with bilateral globe luxation following a traffic accident. A 15-year-old boy was admitted with multiple traumas. He was riding a vehicle without helmet. A notable brain pulsation was observed in a wide and deep cut at the glabella. Bilateral globes were completely dislocated without perforation, and both pupils were dilated and nonreactive. Computed tomography scan showed multiple fractures of ethmoidal and nasal bones, in addition to the medial wall of the left orbit. The globe repositioning was performed after decompression of the orbital wall. The patient remained stable after four days, with no occurrence of meningitis or cellulitis. However, complete optic nerve avulsion resulted in no light perception. Bilateral tarsorrhaphy was conducted to safeguard the globes. In conclusion, managing life-threatening conditions takes precedence in cases of bilateral optic nerve avulsion.

Key words: Accidents Globe Luxation, Optic Nerve Injuries Traumatic Accident, Case Report

Citation: Soltani Shahgoli S, Jamshidian Tehrani M. Bilateral traumatic globe luxation after traffic accident: a case report .J Surg Trauma.2023;11(4): 163-166.

Received: June 29, 2023

Revised: February 17, 2024

Accepted: May 8, 2024

Introduction

Globe luxation with traumatic causality is not common and bilateral type is rare (1). Till now only two cases have been reported in the English-language literature we found on the PUBMED database. Traffic accident is the main reason. Due to high-energy trauma maxillofacial fractures, orbital and periorbital soft tissue injuries, and optic nerve avulsion may occur which leads to total vision loss (2). Above all saving patient's life from life-threatening sequels such as Cerebrospinal Fluid (CSF) leakage meningitis and intracranial hemorrhage are the most mandatory care. Among these, it is important to pay attention to the atmosphere of the patient's mental state and cosmetic issues (3). Herein we present a severe sinonasal trauma with bilateral globe luxation after traffic accident.

Case

A 15-year-old patient was admitted to the emergency service with multiple traumas following a motor vehicle accident. The patient was reported to have been riding vehicle without helmet. The patient was agitated and a wide and deep cut about 4 cm at the glabella with notable brain pulsation was discovered.

Bilateral globes without perforation were totally out of their sockets and both pupils were dilated and nonreactive to penlight (Figure 1 and 2). Computed Tomography (CT) scan revealed multiple fractures of the ethmoidal and nasal bone, as well as the medial wall of the left orbit without intracranial hemorrhage (Figure 3).

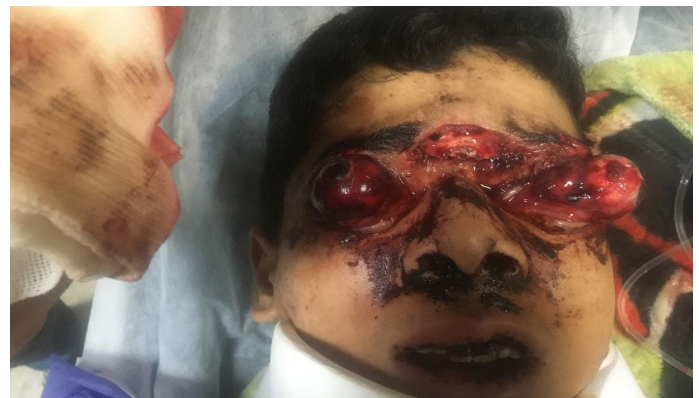
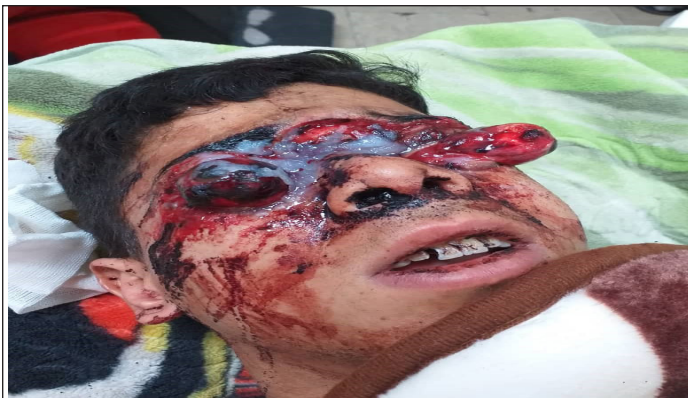
Figure 1.2 Bilateral globes dislocation

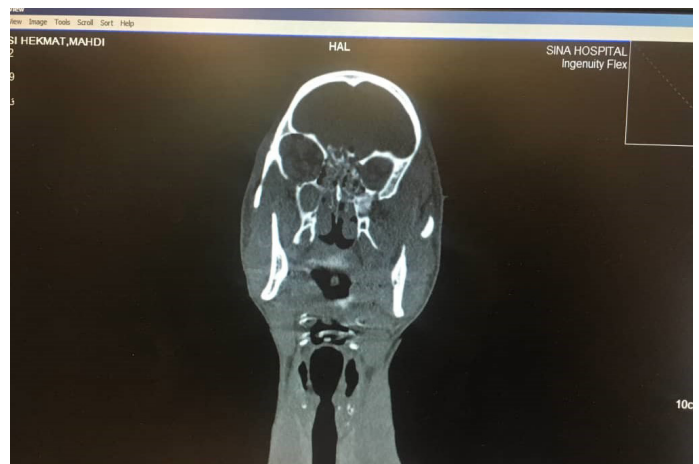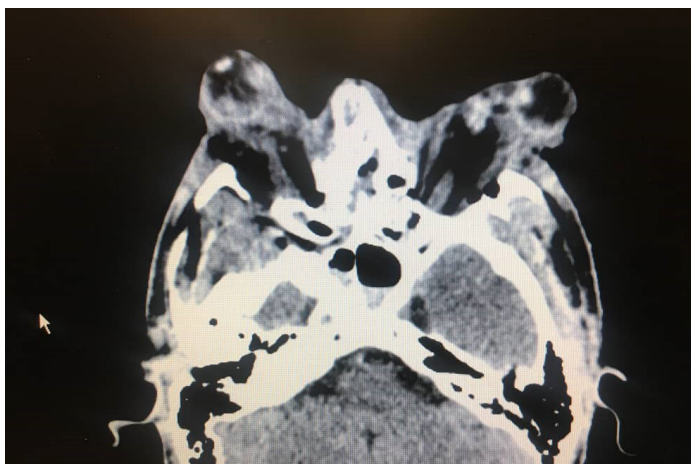


Figure 3. Computed tomography scan of bilateral globes dislocation

Decompression of the orbital wall with lateral and inferior approaches was performed and globe repositioning was done gently. After that, bilateral tarsorrhaphy was accomplished to save the globe. Due to possible sepsis and even meningitis related to cerebrospinal fluid (CSF) leak, required antibiotic coverage was done (Figure 4). After four days, the patient was stable and

meningitis and cellulitis did not happen. Also, CSF leakage was stopped. Visual acuity was bilateral and there was no light perception because of complete optic nerve avulsion. The informed consent was received from the patient. Ethical approval was obtained from the Tehran University of Medical Science, Tehran, Iran (Ethics code: IR.TUMS.FARABIH.REC.1402.031).

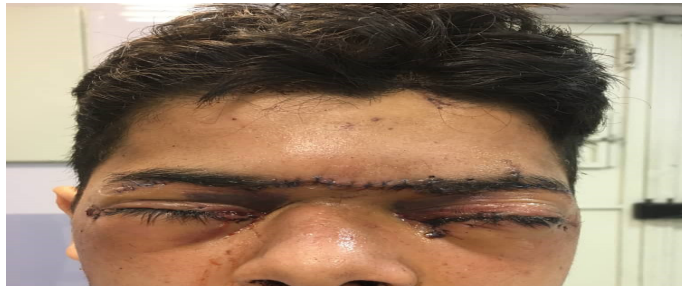

Figure 4. Decompression of orbital wall with lateral and inferior approach

Discussion

The essential goal in cases of globe luxation is the preservation of visual function however in the case of bilateral total optic nerve avulsion cosmetic and psychologic support should be considered. Therefore, in order to maintain the patient's mood, despite the optic nerve amputation and the impossibility of maintaining it, an attempt at primary enucleation is always recommended. This is also very decisive in terms of cosmetic correction. Traumatic globe luxation generally is associated with optic nerve avulsion. The most common site of avulsion is the orbital apex (4). Two usual mechanisms of globe luxation due to trauma have been described. Balaj et al. reported that multiple fractures of facial and orbital bones which compress the posterior part of the orbit so lead to reduction of orbital volume and anterior displacement of the globe (3).

Another way reported by Moris et al. is entering a wedge-shaped or long substance into orbit medially resulting in globe luxation and elongation and transection of the optic nerve (5).

In our case, the first mechanism is plausible. Because of the high energy property of these

injuries, a precise look at damage severity is obligatory. Therefore, as Timoney et al. mentioned, a detailed orbital and cranial scan is important to evaluate the extent of the damage and determine the need for subsequent interventions, as a result, CT scan plays the main role during the first hours of injury (6). Other life-threatening complications are subarachnoid hemorrhage and CSF leak followed by meningitis (7,8).

In our case, only CSF leakage without meningitis happened.

Conclusion

Bilateral optic nerve avulsion needs careful attention and managing life-threatening conditions must be considered at first then cosmetic and psychological rehabilitation is mandatory. Very rare similar cases have been studied and recorded in this subject, which requires further and more detailed studies of all aspects.

Conflict of Interest

The authors declare that there is no conflict of interest.

References

1. S Unal , E Arslan, F Demirkan, A Aksoy. Bilateral complete avulsion of ocular globes in a Le Fort III maxillofacial fracture: a case report and review of the literature. *Eur J Ophthalmol.* 2005;15(1).
2. Amaral, M. B., Carvalho, M. F., Ferreira, A. B., & Mesquita, R. A. Traumatic globe luxation associated with orbital fracture in a child: a case report and literature review. *J Oral Maxillofac Surg .* 2015; 14(1): 323–330.
3. Bajaj MS, Kedar S, Sethi A, Gupta V. Traumatic globe luxation with optic nerve transection. *Orbit.* 2000 ;19(3):165-70.
4. Zhou SW, Pang AYC, Poh EWT, Chin CF. Traumatic Globe Luxation With Chiasmal Avulsion. *J Neuroophthalmol.* 2019;39(1):41-43.
5. Morris WR, Osborn FD, Fleming JC. Traumatic evulsion of the globe. *Ophthalmic Plastic & Reconstructive Surgery.* 2002;18(4):261-267.
6. Timoney P, Tomasko K, Nunery WR, Lee HB. General Principles of Management of Orbital Fractures. *Ophthalmic plastic and reconstructive surgery.* 2021:1231-1235.
7. Tok L, Tok OY, Argun TC, Yilmaz O, Gunes A, Unlu EN. Bilateral traumatic globe luxation with optic nerve transection. *Case Rep Ophthalmol.* 2014;5(3):429-434.
8. Hindman HB, Srikumaran D, Halfpenny C, Hirschbein MJ. Traumatic globe luxation and enucleation caused by a human bite injury. *Ophthalmic Plastic & Reconstructive Surgery.* 2007;23(5):422-423.