

# CASE REPORT

## A Case Report of Ewing's Sarcoma of Tibial Epiphysis with Retrobulbar Mass

Reza Abdi<sup>1</sup>, Mohammad Mehdi Hassanzadeh Taheri<sup>2</sup>✉

<sup>1</sup> Assistant Professor of Orthopedic Surgery, Department of Surgery, Faculty of Medicine, Birjand University of Medical Sciences, Birjand, Iran;

<sup>2</sup> Associate professor of Anatomical Sciences, Department of Anatomy, Faculty of Medicine, Birjand University of Medical Sciences, Birjand, Iran.

Received: June 8, 2015

Revised: September 6, 2015

Accepted: September 23, 2015

### Abstract

Ewing's sarcoma is a relatively common malignant bone tumor that typically occurs in long bone diaphyses of adolescents and young adults of 10-30 years old. Often times, all Ewing's sarcoma of bone have radiographic abnormalities. Diagnosis is usually delayed and can be misdiagnosed as osteomyelitis. Bone to bone metastasis occurs, but soft tissue retro bulbar metastasis is rare. This article presents a 32-year-old man with Ewing's sarcoma of proximal tibial epiphysis, without any radiographic finding, that was treated as osteomyelitis and progressed as a retro bulbar mass.

**Key Words:** Ewing's sarcoma; Epiphysis; Metastasis; Orbit; Tibia; Retrobulbar mass

### Introduction

Ewing's sarcoma is the fourth most common primary malignancy of the bone<sup>1</sup>. The incidence is about 9-11% of primary malignancy of the bone [1-2] and approximately 90% of cases present themselves before the age of 20 [3]. Diaphyses of the long bones (femur, tibia, and humerus), the ribs, and the flat bones, such as the scapula and the pelvis, are the preferred sites [4-5]. Involvement of proximal metaphyses of tibia is rare with an incidence frequency of about 4-11% [6-7].

Although metaphyses of the long bones may occasionally be affected [8], the epiphyseal involvement is rare (2%)[9]. The average delay from onset of symptoms to the diagnosis is about eight months [1].

Clinically, Ewing's sarcoma may present itself as a localized, painful mass or with systemic

symptoms such as fever, malaise, weight loss, leukocytosis and increased erythrocyte sedimentation rate (SER)[10], and may be mistaken with osteomyelitis [11]. When the lesion is associated with systemic features, the prognosis is even worse than average [12].

Lytic destruction is the most common finding, but there may be regions of density due to stimulation of new bone formation. As the tumor bursts through the cortex, which may show only minimal radiographic changes, it often elevates the periosteum gradually. This elevation produces the characteristic multiple layers of subperiosteal reactive new bone, which produces the onionskin appearance. In Ewing's tumors, radiating spicules from the cortex of an affected bone are common. A few tumors are almost completely in a juxta osseous position and show little cortical destruction [12].

© 2015 Journal of Surgery and Trauma; Birjand University of Medical Sciences Journal Office, Ghaffari Ave., Birjand, I.R. Iran  
Tel: +985632443041 (5533)  
Fax: +985632440488  
Po Bax 97175-379  
Email: jsurgery@bums.ac.ir



✉ **Correspondence to:** Mohammad Mehdi Hassanzadeh Taheri; Associate professor, Department of Anatomy, Faculty of Medicine, Birjand University of Medical Sciences, Birjand, Iran; Telephone Number: +98989153617955  
Email Address: mmhtahery35@yahoo.com

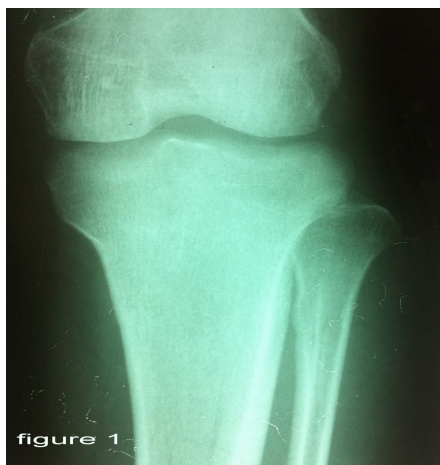## Cases

A 32-year-old man presented with a painful swelling in his left upper tibial metaphysis that was lasting for 3 months. It started with a low energy trauma which was gradually accompanied with constitutional symptoms such as loss of appetite, weight loss, and fever (39.5 °C). Initially, he was diagnosed with osteomyelitis and treated with antibiotics. Finally, he did not respond to antibiotic regimen, ESR did not decrease, and then a painful left eye proptosis and diplopia appeared. Following this, he referred to our hospital. Laboratory findings on the first day of admission were as follows:

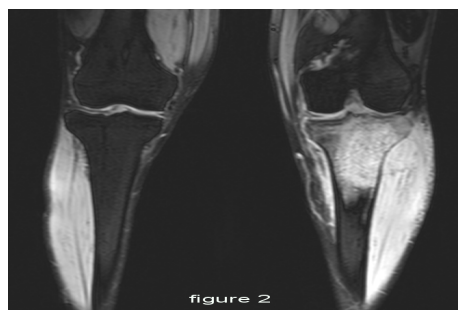
Blood parameters: ESR=122, ALP=normal, CRP=3+, WBC=8000, HCT=38.5, LDH=830 (up to 500 is normal), Blood culture: negative

Except for a very brief rarefaction in proximal metaphysis, the radiography was near normal, and there was no periosteal reaction (Figure 1). In whole body bone scan (tc 99), increased uptake was seen in the upper tibia, left lower rib, and lumbar vertebrae. CT scan of the chest was normal. High signal intensity was seen in MRI (T2) in tibial metaphysis, epiphysis and adjacent soft tissue (Figure 2). Skull CT scan has shown an orbital soft tissue mass (Figure 3).

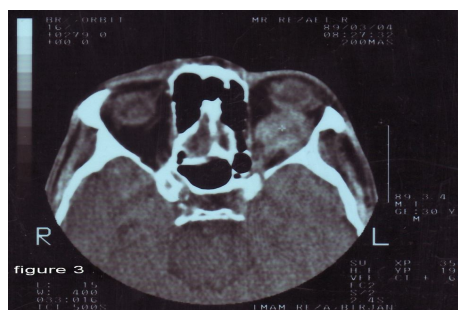Open incisional biopsy of upper tibial metaphysis was performed and the histopathological diagnosis was Ewing's sarcoma as confirmed by IHC (immunohistochemistry). After some course of chemotherapy and radiotherapy, diplopia was improved.



**Figure 1:** Simple radiography of knee with no finding of Ewing's sarcoma



**Figure 2:** MRI of proximal end of tibia



**Figure 3:** Retrobulbar mass in skull CT scan (Hyperdense soft tissue mass is seen in the right orbit.)

## Discussion

Ewing's sarcoma is an extremely malignant tumor that tends, also, to break through the cortex of bone into the adjacent tissues. Spread of this tumor into the orbits is most likely through blood vessels although metastases of this neoplasm to orbits are extremely rare [13]. The related literature rarely reports any significant cases of orbital metastasis of Ewing's sarcoma to our knowledge. Khurana et al. (1992) reported that an Ewing's sarcoma originated from right iliac crest and metastased to orbit bilaterally [13]. Extraosseous Ewing's tumor is a rare entity that primarily originates from soft tissue in orbit. For example, Pang et al (2007)[14] and Alio et al. (2013)[15] reported cases of Ewing's sarcoma originating from extraosseous tissue of orbits where full-body scans and systemic evaluation of these patients showed no metastasis [14, 15]. Nair et al. (2011) reported an Ewing's sarcoma in the orbit with intracranial and extradural extension [16]. Kaler and Sheriff (2013) also reported a primary Ewing's sarcoma with orbit and paranasal sinuses origin [17].

Ewing's sarcoma of a limb with orbital soft tissue metastasis is very rare. This rare case was misdiagnosed, leading to delayed treatment, which is detrimental to the outcome of the disease. Clinoradiologically, Ewing's sarcomas can be misinterpreted as osteomyelitis, giant cell lesions,

lymphomas, and osteosarcomas [1]. Their differentiation often requires extensive evaluation using different imaging modalities. The classical radiological presentation of Ewing's sarcoma is a destructive lesion in the diaphysis of long bones with an onionskin periosteal reaction and a large soft tissue mass [1]. Sometimes, the only apparent change in a radiograph is the presence of erosion without any periosteal reaction. The absence of a periosteal reaction and the lack of cortical thickening have also been noted in this case. In Ewing's sarcoma, the metastatic pattern may be the pulmonary involvement, bone marrow spreading, or combined metastasis [12].

Lymphoma must also be included in the differential diagnosis although this lesion usually occurs in older age groups. The important radiologic difference is usually the absence of a soft tissue mass in lymphoma, whereas in Ewing's sarcoma, a soft tissue mass is almost invariably present, often being disproportionally large compared with the amount of bone destruction [1].

When confronted with the problem of Ewing's tumor in a patient who is beyond the third decade of life, one must be especially careful to exclude metastatic carcinoma [4].

## Conclusions

The case report shows that the classical clinical and radiological presentation of Ewing's sarcoma of bone may not be a rule, and one should be highly suspicious of the disease even if there is no direct pointer to the disease as was encountered in our case. Orthopaedicians, rheumatologists, and radiologists should be alert to this rare atypical occurrence.

The reported case had been misdiagnosed and treated as osteomyelitis.

This case is reported here for the rarity of its presentation and metastasis to soft tissue in orbit.

## References

1. Heck Jr RK. Malignant tumors of bone. In: Terry Canale S, Beaty JH. Campbell's operative orthopedics. 11<sup>th</sup> ed. Philadelphia: Mosby; 2008. pp:901-38.
2. Greenspan A, Jundt G, Remagen W. Differential diagnosis in orthopedic oncology .2<sup>nd</sup> ed. Philadelphia: Lippincott Williams & Wilkins;2007.
3. Bhansali SK, Desai PB. Ewing sarcoma: observation on 107 cases. J Bone Joint Surg Am.1963;45(3):541-53.
4. Dahlin DC, Unni KK. Bone tumors: General aspects and data on 8,542 cases. 4<sup>th</sup> ed. Springfield, IL: Charles C Thomas;1986.
5. Levine E, Levine C. Ewing tumor of rib: radiologic finding sand computed tomography contribution. Skeletal Radiol. 1983;9(4):227-33.
6. Nesbit ME Jr, Gehan EA, Burgert EO Jr, Vietti TJ, Cangir A, Tefft M, et al. Multimodal therapy for the management of primary, non metastatic Ewing's sarcoma of bone: a long-term follow-up of the First Intergroup study. J Clin Oncol. 1990;8(10):1664-74.
7. Widhe B, Widhe T. Initial symptoms and features in osteosarcoma and Ewing sarcoma. J Bone Joint Surg Am. 2000;82(5):667-74.
8. Saifuddin A, Whelan J, Pringle JAS, Cannon SR. Malignant round cell tumours of bone: atypical clinical and imaging features. Skeletal Radiol. 2000;29(11):646-51.
9. Mirra JM, Picci P, Gold RH (eds). Bone tumors: clinical, radiologic, and pathologic correlations. Philadelphia: Lea & Febiger;1989.
10. Kissane JM, Askin FB, Foulkes M, Stratton LB, Shirley SF. Ewing's sarcoma of bone. Clinicopathological aspect of 303 cases from the intergroup Ewing's sarcoma study. Hum Pathol. 1983;14(9):773-9.
11. Friedman B, Hanoaka H. Round-cell sarcomas of bone. A light and electron microscopic study. J Bone Joint Surg Am.1971;53(6):1118-36.
12. Krishnan Unni K, Inwards CY. Dahlin's Bone Tumors: General Aspects and Data on 10,165 Cases. 6<sup>th</sup>ed. Philadelphia: Wolters Kluwer, Lippincott Williams & Wilkins;2010.
13. Khurana AK, Ahluwalia BK, Gupta S, Rajan C, Arora BB. Bilateral proptosis due to metastatic *Ewing's sarcoma* of the orbit: Fine needle aspiration cytology (FNAC) and histopathology of a case. Indian J Ophthalmol. 1992;40(1):15-7.
14. Pang NK, Bartley GB, Giannini C. Primary Ewing sarcoma of the orbit in an adult. Ophthal Plast Reconstr Surg. 2007; 23(2): 153-4.
15. Alio JL 2nd, Sales-Sanz M, Vaz MA, Barrancos C, Reguero ME, Diamantopoulus J, et al. Primary extraosseous Ewing sarcoma of the orbit. Ophthal Plast Reconstr Surg. 2013;29(3):e91-3.
16. Nair AP, Bettaswamy G, Jaiswal AK, Garg P, Jaiswal S, Behari S. Ewing's sarcoma of the orbit with intracranial extension: A rare cause of unilateral proptosis. J Pediatr Neurosci. 2011;6(1):36-9.
- 17- Kaler AK, Sheriff S. Primary Ewing's sarcoma of the paranasal sinuses and orbit. Innovative Journal of Medical and health Science. 2013;3(1):1-3.