Case Report

Open Access
Publish Free

Cardiopulmonary Bypass Management in A Patient with Unilateral 100% Internal Carotid Artery Stenosis and Prior Stroke: A Case Report

Ali Taherinezhad Ledari[1], Ahmad Amouzeshi[2], Seyyed Ebrahim Hosseini Zargaz[3], Mahmoud Ganjifard[4] ✉

[1] Student Research Committee, Babol University of Medical Sciences, Babol, Iran.

[2] Department of Cardiology, School of Medicine, Cardiovascular Diseases Research Center, Birjand University of Medical Sciences, Birjand, Iran.

[3] Cardiovascular Diseases Research Center, Birjand University of Medical Sciences, Birjand, Iran.

[4] Department of Anesthesiology and Critical Care, Faculty of Medicine, Birjand University of Medical Sciences, Birjand, Iran.

✉**Corresponding Author:** Email: fardganj@gmail.com

Received: 8 March 2026

Revised: 9 June 2026

Accepted: 15 June 2026

Citation: Taherinezhad Ledari A, Amouzeshi A, Hosseini Zargaz SE, Ganjifard M. Cardiopulmonary Bypass Management in A Patient with Unilateral 100% Internal Carotid Artery Stenosis and Prior Stroke: A Case Report. J Surg Trauma. 2026.

DOI: jsurgery.bums.ac.ir

Abstract

Background: Carotid stenosis is one of the risk factors associated with increased complications and comorbidities associated with open heart surgery. Depending on the severity of the stenosis, this disease can aggravate stroke and other complications of surgery.

Case report:

Case Report The patient we reported was a 69-year-old man who was a candidate for coronary artery bypass surgery with complete stenosis of the internal carotid artery and a history of myocardial infarction. The patient underwent open heart surgery due to occlusion of the three main vessels as an on-pump. Hybrid strategies such as alpha statin and ph statin were considered for him at specific times. The patient was transferred to the ward and discharged without any exacerbation of cerebral complications.

Conclusion:

Although carotid artery stenosis is associated with a high risk of cerebral complications after open heart surgery, the exacerbation of cerebral complications during and after surgery can be reduced by combining the two strategies of Alpha and PH stat.

Key words: Cardiopulmonary Bypass, Internal Carotid Artery Stenosis, Stroke

Introduction

A complete occlusion of the internal carotid artery (ICA) represents a major cause of cerebrovascular disease (1). Precise data on the prevalence of ICA occlusion is difficult to determine, as the condition may remain asymptomatic.

In a population-based retrospective study of patients with symptomatic ICA occlusion, the incidence rate was reported as six cases per 100,000 people (2). Some researchers believe that this incidence rate is likely an underestimate, as many patients with transient ischemic attacks (TIAs) do not seek medical care, and some patients with stroke or TIA do not undergo carotid imaging for investigation. The researchers stated that approximately 15% of large-vessel ischemic strokes might occur due to ICA occlusion. The concurrence (comorbidity) of symptomatic coronary artery disease with severe carotid artery stenosis has been reported in a range between 3.4% and 22% (2, 3).

The incidence of stroke following coronary artery bypass grafting (CABG) is also estimated to be between 0.8% and 6%. This risk increases to approximately 10% in cases of severe carotid artery stenosis. This case report involved a patient with 100% right ICA stenosis, who had a history of

Copyright © 2026, Journal of Surgery and Trauma. This is an open access article distributed under the terms of the Creative Commons Attribution License (CC-By-NC4.0: https://creativecommons.org/licenses/by-nc/4.0/legalcode.en), which permits use, distribution, and reproduction in any medium, provided the original work is properly cited and is not used for commercial purposes.

cerebrovascular accident (CVA), and was a candidate for open-heart CABG due to coronary atherosclerosis (4). We reported this case to highlight the intraoperative management challenge in a patient with severe unilateral ICA stenosis and previous stroke, and to describe the successful use of a hybrid alpha-stat and pH-stat strategy during cardiopulmonary bypass.

Case Report

A 69-year-old male patient with a history of hypertension and a CVA approximately 7 years prior, presented for a check-up following a sudden cardiac death of his brother. His presenting symptom was left upper limb paresis. Angiographic evaluation of the patient revealed a diagnosis of three-vessel disease (3VD). Based on subsequent Doppler ultrasound findings, which demonstrated 100% right ICA stenosis, carotid Doppler ultrasonography showed an intima-media thickness of 0.8 mm on the right side and 0.7 mm on the left side. Two adjacent calcified plaques were observed on the posterior wall of the right common carotid artery (CCA) bulb. In the right ICA, complete involvement of the proximal segment with no visible blood flow in the distal segments was reported, suggesting complete occlusion. On the contralateral side, several small plaques were observed in the left CCA bulb; however, they did not result in significant stenosis. Vascular flow in both vertebral arteries was normal, and several management strategies were considered for this patient (Figure 1). A total of 300 units of heparin per kilogram of body weight were administered to the patient upon induction of anesthesia. Initially, a relatively high partial pressure of carbon dioxide (PCO_2) was maintained, with the PCO_2 level kept between 45 and 50 mmHg. The pH-stat technique was used during cooling, followed by the alpha-stat technique after rewarming. The alpha-stat technique was selected due to increased cerebral metabolic demands, aiming to preserve cerebral perfusion and minimize the risk of CVA. The PCO_2 range was then maintained between 40 and 45 mmHg. The second strategy involved maintaining the mean arterial pressure (MAP) between 70 and 75 mmHg. The third strategy involved the initial use of volume-assisted perfusion (VAP) and retrograde autologous priming (RAP) techniques, followed by additional volume acquisition and an increase in intraoperative hemoglobin concentration. The patient underwent three CABG procedures. The patient's cross-clamp time was 60 min, and the cardiopulmonary bypass (CPB) time was 80 min. The patient was successfully weaned off the pump without any specific complications. Extubation was performed 4 h later in the intensive care unit. After two days, the patient was transferred to the general ward with no neurological deficits concerning limb movement and orientation. The patient was discharged after five days.

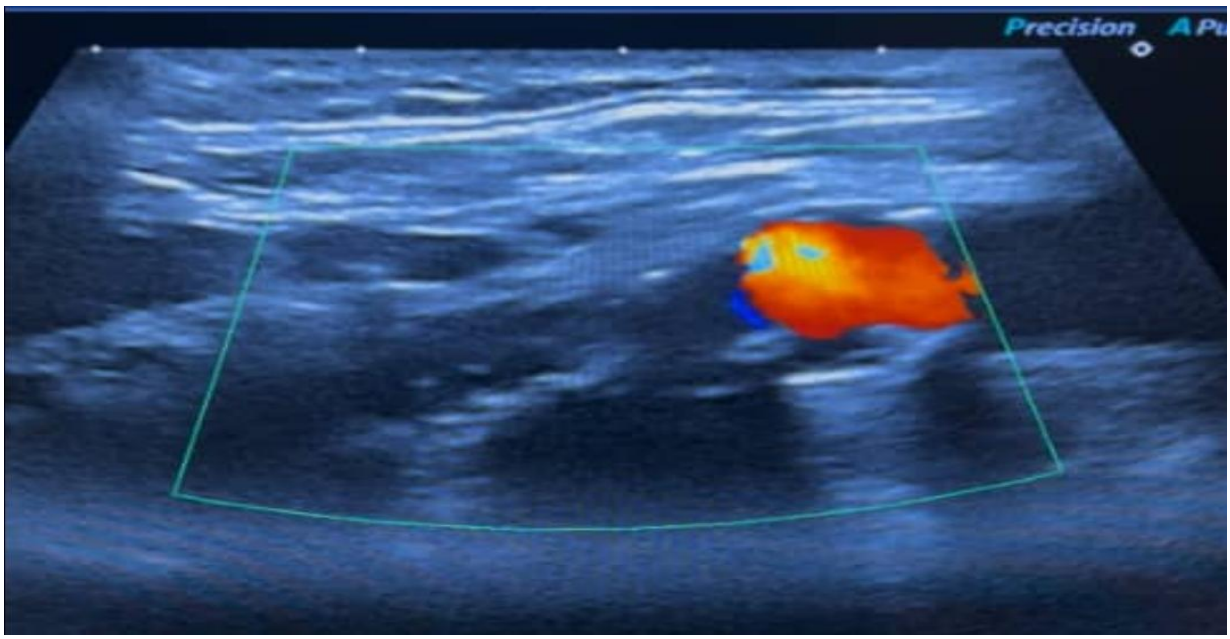

Figure 1. Ultrasound demonstrating normal flow within the common carotid artery (CCA), with absence of flow distally, consistent with complete occlusion of the internal carotid artery (ICA).

Discussion

Coronary artery bypass graft is among the most common heart surgeries (5). Management during CPB in patients with 100% unilateral carotid artery stenosis and a history of CVA is one of the most challenging procedures in the field of perfusion. A study reported that in patients with unilateral carotid artery stenosis, the incidence of stroke exceeded 16%, and these patients were found to be at a higher risk of mortality. In such cases, insufficient perfusion reduces cerebral perfusion pressure (CPP) in the ipsilateral hemisphere. Therefore, maintaining appropriate pressure during CPB is essential (6, 7). The primary goal in these patients is to provide cerebral protection and prevent hypoperfusion, thus mitigating the risk of postoperative stroke. In the current case, we adopted several strategies. First, to increase hemoglobin levels and maintain oxygen delivery (DO2) above 300, RAP and VAP were performed, and the hematocrit level during CPB was maintained between 30 and 32. The second action was to maintain the MAP between 70 and 75. The next strategy was the hybrid use of the alpha-stat and pH-stat techniques. For our patient, the pH-stat technique was used during the cooling phase, followed by the alpha-stat strategy. Previous studies indicated that in adult patients with mild hypothermia, the use of the pH-stat technique is generally unnecessary due to the presence of cerebral autoregulation, and this technique is typically reserved for pediatric patients and those undergoing deep hypothermia. However, in patients with complete unilateral carotid artery stenosis and a history of stroke, the autoregulation system on the side of severe carotid artery stenosis becomes impaired. Therefore, the application of the pH-stat technique during the cooling phase leads to an increased amount of CO2 injected into the circuit, resulting in vasodilation and improved cerebral tissue perfusion. In the subsequent step, during the rewarming phase, the alpha-stat strategy was implemented given that cerebral metabolism increases. This is because a rise in CO2 during this phase can culminate in luxury perfusion, resulting in the impairment of cerebral autoregulation and a disruption in the coupling between cerebral blood flow and metabolism (8). The present case report has several limitations owing to its single patient design and the absence of comparative data, which limit its generalizability. Larger studies are required to confirm the safety and effectiveness of the hybrid alpha stat/pH stat approach. However, the present case suggests that in high risk patients with severe carotid stenosis and a prior stroke, careful cerebral perfusion management and individualized acid–base strategies may help improve cerebral oxygenation and reduce neurological complications.

Conclusion

In patients with 100% carotid artery stenosis, especially those with a history of stroke, a primary concern is maintaining adequate cerebral perfusion and minimizing the risk of postoperative stroke or neurological deterioration. With a series of supportive measures, it is possible to mitigate the occurrence of postoperative neurological complications and allow these patients to undergo CPB safely. In our case, we utilized a hybrid approach combining both alpha-stat and pH-stat techniques. A critical consideration throughout the procedure was to ensure that the PCO_2 did not fall below 35 mmHg at any stage.

Abbreviations

ICA: Internal carotid artery
DO2: Oxygen delivery
CPB: Cardiopulmonary bypass

Ethics Approval and Consent to Participate

Written informed consent for publication of this case report and any accompanying images was obtained from the patient.

Consent for Publication

Not applicable.

Data Availability Statement

The data supporting the findings of this study are available from the corresponding author upon reasonable request.

Funding Statement

The authors received no funding for the present research.

Acknowledgements

None.

Author's Contribution

A. A. contributed to the study conception, patient management, and supervision of the manuscript. F. Sh. was involved in data collection, writing of

literature review, and drafting the manuscript. A. Kh. participated in the clinical management of the patient and revision of the manuscript. S. E. H. Z. contributed to data interpretation and critical revision of the manuscript. M. G. assisted in the study design, manuscript editing, and final approval of the publication-ready version. All authors read and approved the final manuscript..

Conflict of Interest

All authors declared that there were no conflicts of interest to report.

Declaration of Generative Artificial Intelligence in Scientific Writing

During the preparation of this study, the authors used Perplexity AI to improve readability. After using this tool, the authors reviewed and edited the content and take full responsibility for the final publication.

References

1. Ma Y, Wang T, Wang H, Amin-Hanjani S, Tong X, Wang J, et al. Extracranial-intracranial bypass and risk of stroke and death in patients with symptomatic artery occlusion: the CMOSS randomized clinical trial. JAMA. 2023;330(8):704-14. [DOI: 10.1001/jama.2023.13390]
2. Tang M, Yan X, Gao J, Li L, Zhe X, Zhang X, et al. High-resolution MRI for evaluation of the possibility of successful recanalization in symptomatic chronic ICA occlusion: a retrospective study. AJNR Am J Neuroradiol. 2022 Aug 1;43(8):1164-71. [DOI: 10.3174/ajnr.A7576]
3. Al Kasab S, Nguyen TN, Derdeyn CP, Yaghi S, Amin-Hanjani S, Kicielinski K, et al. Emergent large vessel occlusion due to intracranial stenosis: identification, management, challenges, and future directions. Stroke. 2024;55(2):355-65. [DOI: 10.1161/STROKEAHA.123.043635]
4. Thanvi B, Robinson T. Complete occlusion of extracranial internal carotid artery: clinical features, pathophysiology, diagnosis and management. Postgrad Med J. 2007;83(976):95-9. [DOI: 10.1136/pgmj.2006.048041]
5. Jalili Shahandashti F, Mozayan M, Abdolkarimi L, Kargar F, Ghanbari A, Heidarinia S, et al. The effect of administration of Del Nido cardioplegia solution containing vitamin C on myocardial protection and clinical outcomes in patients undergoing coronary artery bypass graft surgery. Egypt Heart J. 2025;77(1):72. [DOI: 10.1186/s43044-025-00641-3]
6. Abbasi K, Shirani S, Araghi MF, Karimi A, Ahmadi H, Abbasi SH, et al. Coronary artery bypass grafting combined with total occlusion of internal carotid artery. Res Heart Yield Transl Med. 2008;3(2):77-82. [URL: https://jthc.tums.ac.ir/index.php/jthc/article/view/86]
7. Lescan M, Steger V, Andic M, Veseli K, Haeberle H, Krüger T, et al. Cardiac surgery in the presence of chronic internal carotid artery occlusion. Heart Vessels. 2019;34(9):1471-8. [DOI: 10.1007/s00380-019-01381-6]
8. Nauphal M, El-Khatib M, Taha S, Haroun-Bizri S, Alameddine M, Baraka A. Effect of alpha-stat vs. pH-stat strategies on cerebral oximetry during moderate hypothermic cardiopulmonary bypass. Eur J Anaesthesiol. 2007;24(1):15-9. [DOI: 10.1017/S0265021506000998]