Journal of Surgery and Trauma 2015; 3(1-2):26-29.
www.jsurgery.bums.ac.ir

CASE REPORT

Treatment of horizontal root fracture with extrusion: A case report

Sediqe Ebrahimipour[1]

[1] *Department of Endodontics, Faculty of Dentistry and Dental Research Center, Birjand University of Medical Sciences, Birjand, Iran*

Received: January 9, 2016 ***Revised: February 3, 2016*** ***Accepted: February 9, 2016***

Abstract

Root fractures are defined as fractures involving dentine, cementum, and pulpal and supportive tissues. They comprise about 0.5–7% of all dental injuries. Horizontal root fractures are commonly observed in the maxillary anterior region and 75% of these fractures occur in the maxillary central incisors. Case report: This case report is about a 26-year-old male referred to the endodontic department of Zahedan dental school 3 days after motorcycle accident. Radiographic examination shows a horizontally root fracture of the right mandibular central incisor in the apical third. Initially, the coronal fragment was repositioned and this was radiographically confirmed. Then, the stabilization splint was applied and remained for 50 days. Two weeks splinting which radiographic examination showed the lesion adjacent to the fracture line, the two visit endodontic treatment of the coronal portion was started and the root canal was obturated with gutta percha points. Conclusion: One-year follow-up examination revealed the clinical and radiographic signs of healing with hard tissue repair of the fracture line.

Key Words: Dental trauma; Root fracture; Endodontic treatment; Tooth splint

Introduction

Horizontal root fracture is a rare traumatic injury and comprises about 0.5 to 7 % of all dental injuries [1-3]. It is defined as a fracture involving dentine, cementum, pulp and supportive tissues. The fracture can be at the cervical, middle or apical region of the root. This kind of fracture usually occurs because of severe trauma, such as traffic accidents and sports injuries. Varieties of methods are suggested for management of the tooth with a horizontally fractured root [3-5]

Principle of treatment is stabilization of the coronal part and protectitn of the pulp vitality, for which splint application is recommended. At the present time, splinting with the orthodontic wire and composite resin for 1–3 months is preferred in the teeth with a root fracture [1]. one recent study proposed intra radicular splinting with endodontic instrument [3].

In cases of horizontal root fracture, healing occurs with one of these four types: healing with hard tissue, interposition of connective tissue, interposition of bone and connective tissue, and interposition of granulation tissue. “Healing with hard tissue” is the best result that is expected and interposition of the granulation tissue represents an inflammatory state, and it means treatment failure [6].

The healing process depends on different variables such as the age of the patient, the mobility of the coronal fragment, location of root fracture (apical, middle or coronal), and stage of root formation [7]. The international association of dental traumatology guidelines, recommend endodontic treatment only after pulpal necrosis, not as a prophylactic intervention [8]. Researches have demonstrated that the pulp in the apical third will remain vital with a high percentage of successful healing in most cases, thus root canal therapies are

@2015 Journal of Surgery and Trauma
Tel: +985632381203
Fax: +985632440488
Po Bax 97175-379
Email: jsurgery@bums.ac.ir

✉ **Correspondence to:**
Sediqe Ebrahimipour; Assistant Professor, Department of Endodontics, Faculty of Dentistry and Dental Research Center, Birjand University of Medical Sciences, Birjand, Iran;
Telephone Number: 056-32237553
Email Address: sdent22@bums.ac.ir

[Downloaded from jsurgery.bums.ac.ir on 2026-11-28]

not recommended [9]. The purpose of placing a root end filling material is to provide an apical seal which inhibits the leakage of irritants from the root canal system into the periradicular tissues via fractured line. At the present time, MTA (mineral trioxide aggregate) is used for sealing the apical potion of the coronal fragment because MTA has been reported to seal off all the pathways of communication between the root canal system and the external surface of the tooth. Orthograde MTA is routinely used; however, one study used retrograde MTA placement by surgically removing the fractured fragment [10]. Because of the extent of fracture line, gutta percha points, while more convenient, they may not fill the irregularities of the dentinal wall and the area could not be well obturated. Successful application of gutta percha depends on the canal diameter and it is depends on the tooth type and the fracture level.

The aim of this case report was to present the healing response of fractured root in a mature mandibular central incisor treated with gutta percha points.

Cases

A 26-year-old man was referred to the endodontic department of Zahedan dental school 3 days after motorcycle accident with chief complaints of "My tooth is loosed ". The extra oral examination revealed swelling of the lower lip. Intra oral examination showed the luxation of the #25 and crown fractures of the teeth #22, #23, #24, #26 and #27. Radiographic examination showed horizontal root fracture with extrusion of the coronal fragment of #25.

The coronal portion of the fractured root had fallen out of the socket and was replaced in the socket by the patient. It was quite mobile (Figure 1). At emergency session, the coronal fragment was reducted and splinted with #4 stainless steel wire and composite resin (Colten, Switzerland). On the next appointment that was designed one week later, the vitality test of the fractured teeth and radiographic examination were performed. Radiographic examination showed an intraosseus lesion around the fracture line of ≠25 (Figure 2) which was indicative of tooth necrosis. The access cavity was prepared and after cleaning and shaping of the coronal portion, one-week calcium hydroxide therapy was started (Golchai, Karaj, Iran). On the next session, the canal was washed and filled with gutta-percha points (Arya Dent, Tehran, Iran) and AH26 sealer (Arya Dent, Tehran, Iran). Because of the narrowing of the root canal of mandibular central incisor, the apical stop was obtained with a No. 50K file (Maillefer, Balaiggues, Switzerland) so the apical seal was provided with gutta percha and no apical plug was needed.

The splint was opened after 50 days. Radiographic evidence revealed the healing of the bone lesion and binding the fragments in adjacent fracture line. One-year radiographic follow up showed complete healing of bone lesion, close contact between the broken fragments, the connection between dental parts and the formation of hard tissue between the two fragments (Figure 3).



Figure 1: Initial radiography

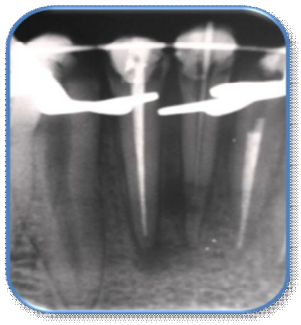

Figure 2: Formation of bone lesion near the fracture line1 week later



Figure 3: follow up radiography (1 year)

Discussion

This case report presents a simple method for the management of a mandibular central incisor with a horizontal root fracture; healing potential of these teeth is great (80%) compared with luxations [11-13]. In many cases where root fractures are in the apical and middle third region, the fracture remains undiagnosed and healing occurs spontaneously [13]. Thus, immediate endodontic intervention in the cases of horizontal root fracture should be avoided if no clinical and/or pathological signs or symptoms are present. However, in some

[Downloaded from jsurgery.bums.ac.ir on 2026-11-28]

cases especially in the cases with displacement, the coronal pulp may be necrotized and requires endodontic treatment. About 25% of adult patients with a horizontal root fracture show pulpal necrosis in the coronal fragment and require a root canal treatment [6]. As the apical fragment is not displaced, it usually remains vital because the apical pulpal circulation is often not disrupted [14]. Endodontic treatment of only the coronal fragment enhances the healing compared to when endodontic treatment of both fragments is accomplished [6]. It is because the irritants of the root canal system penetrate to the periradicular tissue via the two fragments space and delay or prevent healing. After proper clinical management with repositioning and splinting, the first step is elimination of the infection in the coronal fragment; otherwise, healing will not occur.

Since the apical part of the coronal fragment resembles the teeth with open apices, especially in maxillary teeth that have a wide root canal, MTA is suggested in many studies for optimal closure of the wound area because of biocompatibility and precise adaptation of this material to the dentinal walls and provision of hydraulic seal [15-18]. But in the present study, in the mandibular central incisor with narrow root canal, the apical seal was achieved by gutta percha too. It seems that with appropriate infection control and proper sealing of the necrotic fragment, the long term prognosis of tooth will not be affected by the type of filling material.

Conclusions

Healing of the fractured root depends on the establishment of healthy pulp, dentin, cementum and alveolar bone in the area. It seems that the prognosis of the horizontal root fractures is good and if the coronal and apical seal is achieved, the sealing material would not be an important factor. Correct diagnosis, appropriate treatment and clinical management and follow up radiographs are essential for successful treatment.

References

1. Andreasen JO, Andreasen FM, Andersson L (eds). Textbook and color atlas of traumatic injuries to the teeth. 4th ed. Hoboken: John Wiley & Sons; 2013.
2. Birch R, Rock WP. The incidence of complications following root fracture in permanent anterior teeth. Br Dent J. 1986; 160(40): 119-22.
3. Çiçek E, Yılmaz N, Koçak MM. Intraradicular Splinting with Endodontic Instrument of Horizontal Root Fracture. Case Rep Dent. 2015; 2015:505370.
4. Kusgoz A, Yildirim T, Tanriver M, Yesilyurt C. Treatment of horizontal root fractures using MTA as apical plug: report of 3 cases. Oral Surg Oral Med Oral Pathol Oral Radiol Endod. 2009; 107(5):e68-72.
5. Poi WR, Manfrin TM, Holland R, Sonoda CK. Repair characteristics of horizontal root fracture: a case report. Dent Traumatol. 2002; 18(2):98-102.
6. Cvek M, Mejàre I, Andreasen JO. Conservative endodontic treatment of teeth fractured in the middle or apical part of the root. Dent Traumatol. 2004; 20(5):261-9.
7. Andreasen JO, Andreasen FM, Mejàre I, Cvek M. Healing of 400 intra-alveolar root fractures. 2. Effect of treatment factors such as treatment delay, repositioning, splinting type and period and antibiotics. Dent traumatol. 2004; 20(4):203-11.
8. Pan CS, Walker RT. Root fractures: a case of dental non-intervention. Endod Dent Traumatol. 1988; 4(4):186-8.
9. Polat-Özsoy Ö, Gülsahi K, Veziroğlu F. Treatment of horizontal root-fractured maxillary incisors–a case report. Dent Traumatol. 2008; 24(6): e91-5.
10. Agrawal N, Agrawal H, Parmar G. Treatment of maxillary left central incisor with horizontal root fracture-A case report. Endodontology. 2014; 26(1).
11. Giuliani V, Baccetti T, Pace R, Pagavino G. The use of MTA in teeth with necrotic pulps and open apices1. Dent Traumatol. 2002; 18(4):217-21.
12. Artvinli LB, Dural S. Spontaneously healed root fracture: report of a case. Dent traumatol. 2003; 19(1):64-6.
13. Calişkan M, Pehlivan Y. Prognosis of root-fractured permanent incisors. Endod Dent Traumatol. 1996; 12(3):129-36.
14. Clark SJ, Eleazer P. Management of a horizontal root fracture after previous root canal therapy. Oral Surg Oral Med Oral Pathol Oral Radiol Endod. 2000; 89(2):220-3.
15. Holden DT, Schwartz SA, Kirkpatrick TC, Schindler WG. Clinical outcomes of artificial root-end barriers with mineral trioxide aggregate in teeth with immature apices. J Endod. 2008; 34(7):812-7.
16. Chala S, Abouqal R, Rida S. Apexification of immature teeth with calcium hydroxide or mineral trioxide aggregate: systematic review and meta-analysis. Oral Surg Oral Med Oral Pathol Oral Radiol Endod. 2011; 112(4):e36-42.
17. Gondim E, Zaia AA, Gomes BP, Ferraz CC, Teixeira FB, Souza-Filho FJ. Investigation of the marginal

[Downloaded from jsurgery.bums.ac.ir on 2026-11-28]

adaptation of root-end filling materials in root-end cavities prepared with ultrasonic tips. Int Endod J. 2003; 36(7):491-9.

18. Camilleri J, Montesin FE, Papaioannou S, McDonald F, Pitt Ford T. Biocompatibility of two commercial forms of mineral trioxide aggregate. Int Endod J. 2004; 37(10):699-704.

[Downloaded from jsurgery.bums.ac.ir on 2026-11-28]