

# CASE REPORT

## Role of paraclinical assessment in management of massive pulmonary embolism: A case report

Niloufar Valizadeh<sup>1</sup>, Farbod Hatami<sup>1</sup>, Mahmood Hosseinzadeh Maleki<sup>1</sup>✉, Fatemeh Zahra Bahador<sup>2</sup>

<sup>1</sup> Birjand CardioVascular Diseases Research Center, Birjand University of Medical Sciences, Birjand, Iran;

<sup>2</sup> Department of Cardiac Surgery, Birjand University of Medical Sciences, Birjand, Iran.

Received: November 21, 2016

Revised: January 18, 2017

Accepted: February 1, 2017

### Abstract

Despite all the diagnosis and treatment processes of pulmonary thromboembolism (PTE), it is still associated with a high rate of mortality. We describe a massive PTE case of a 73-year-old woman with unusual clinical manifestations.

**Key Words:** Pulmonary Embolism; Paraclinic; Managment

### Introduction

Pulmonary emboli (PE) is a life-threatening disease with an estimated 600,000 episodes and 100,000-200,000 deaths per year in the U.S. There are numerous deaths caused by undiagnosed massive pulmonary embolism [1] complicated by an approximately 30% mortality rate of untreated PE [1, 2]. Although there is a high prevalence of PE, it is still hard to diagnose and has a wide range of clinical manifestations [2, 3].

Massive pulmonary emboli (PE) has been defined as a PE associated with systolic blood pressure (<90 mmHg or a drop in systolic blood pressure of ≥ 40mmHg from baseline for a period >15 min) and cardiogenic shock (tissue hypoperfusion and hypoxia [1].

### Cases

A 73-year-old woman with right leg swelling, pain, and slightly shortness of breath was admitted to our hospital with suspicion of deep vein thrombosis (DVT). There was no significant

evidence of diabetes melitus, hypertension, cerebrovascular accident, or cardiovascular risk factors in the patient's past medical history. Vital signs were stable on physical examination (blood pressure=100/60, heart rate=64/min, respiratory rate=16/min, O<sub>2</sub> saturation=93%). Lung auscultation was normal. In comparison with the left lower extremity, the right lower extremity had pain, edema and some discoloration up to the thigh. A venous Doppler examination suggested right femoral venous thrombosis which was extended to common iliac vein; thereby, anticoagulant therapy started. Chest-x-ray was normal. ECG revealed Q wave in lead III and aVF lead, and inverted T wave in lead V1-V6 (Fig. 1). To roll out PTE (considering slightly shortness of breath), echocardiography was performed, which confirmed RV dilatation and sever dysfunction. Pulmonary CT angiography showed a clot resulting in complete blockage of the left pulmonary artery (LPA) and partial obstruction of the right pulmonary artery (RPA) (Fig. 2).

©2015 Journal of Surgery and Trauma

Tel: +985632381203

Fax: +985632440488

Po Bax 97175-379

Email: jsurgery@bums.ac.ir

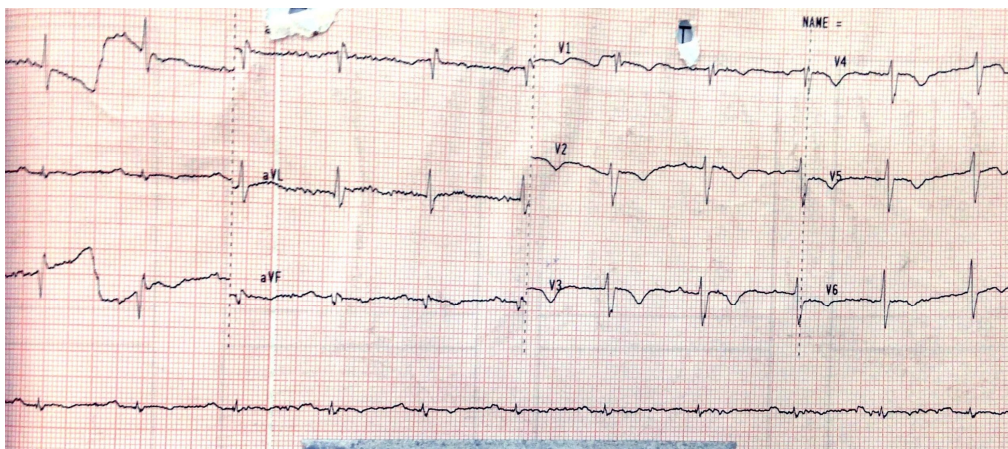


✉ Correspondence to:

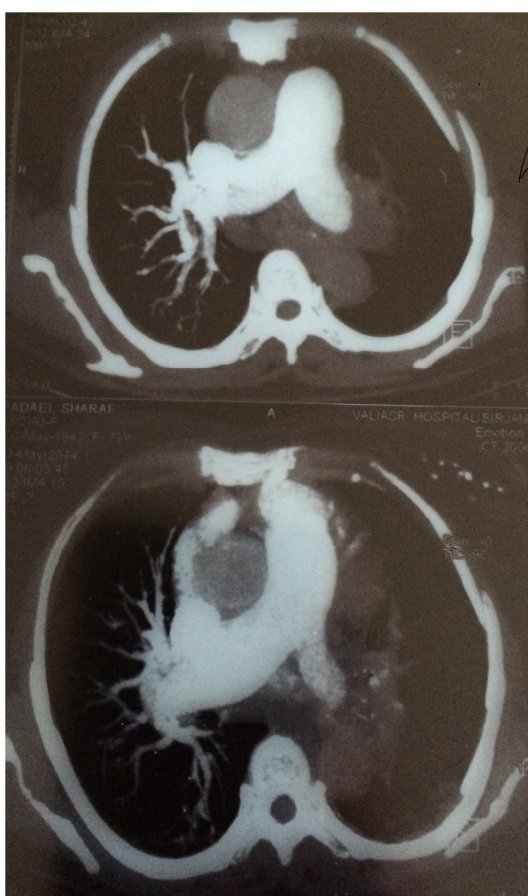
Mahmood Hosseinzadeh Maleki, Associated Professor, Birjand CardioVascular Diseases Research Center, Department of Cardiovascular Surgery, Birjand University of Medical Sciences, Birjand, Iran;

Telephone Number: 0985117284448

Email Address: mahmoodhosseinzadeh@yahoo.com



**Figure 1: Preoperative ECG**



**Figure 2: CT angiography of massive pulmonary embolism; LPA cut off due to deep vein thrombosis**



**Figure 3: Fresh clot of LPA and superior branch of RPA**

The patient underwent pulmonary embolectomy after replacement of IVC filter (Fig. 3). She was discharged from hospital 10 days after the operation in a good general condition and she is alive at 2-year follow-up.

## Discussion

PE has a wide range of clinical manifestations. In this case, we described a patient who had massive PTE according to paraclinical findings, though her vital signs were stable and there was no typical clinical manifestation.

A study done in 2007 by Akloy et al showed within a 10-month follow-up that 89% of the patients survived after surgical embolectomy treatment. In the authors' opinion, the reason for the high survival rate was liberalized criteria of acute pulmonary embolectomy, including anatomically extensive pulmonary embolism and concomitant moderate to severe right ventricular dysfunction despite preserved systemic arterial pressure [4].

There was no clinical signs in our case to be a candidate for embolectomy. However, because of the high pulmonary vascular bed involvement shown in CT scan and the right ventricle failure (> 50%), the patient became a candidate for surgical embolectomy.

In Goldhaber's study, it is claimed that the main cause of mortality among most patients undergoing surgery for pulmonary embolectomy is cardiogenic shock and multiple organ failure resulting in high mortality rate (around 50%) in surgical pulmonary embolectomy [5].

In Wood KE's study, PE mortality rate depends strictly on hemodynamic compromise, which ranges from less than 3% in normotensive patients without evidence of right ventricular dysfunction (RVD) to up to 30% in patients with shock and up to 20% in patients with cardiac arrest at presentation [6,7].

## Conclusions

It seems that revision of diagnostic and therapeutic criteria for PE as well as collaboration

between the cardiologist and the cardiac surgeon to determine candidature of patients for surgical pulmonary embolectomy can decrease mortality and morbidity of the patients. The difference between patients' mortality in different studies highlights the need for revision in criteria of massive PE and the surgical plan.

## References

1. Fedullo PF, Tapson VF. The evaluation of suspected pulmonary embolism. *New England Journal of Medicine*. 2003;349(13):1247-56.
2. Egermayer P. The mortality of untreated pulmonary embolism. *Chest*. 1996;110(1):303.
3. Tsapenko MV, Tsapenko AV, Comfere TB, Mour GK, Mankad SV, Gajic O. Arterial pulmonary hypertension in noncardiac intensive care unit. *Vasc Health Risk Manag*. 2008;4(5):1043-60.
4. Aklog L, Williams CS, Byrne JG, Goldhaber SZ. Acute pulmonary embolectomy. *Circulation*. 2002;105(12):1416-9.
5. Goldhaber SZ. Surgical pulmonary embolectomy. *Tex Heart Inst J*. 2013;40(1):5-8.
6. Wood KE. Major pulmonary embolism: review of a pathophysiologic approach to the golden hour of hemodynamically significant pulmonary embolism. *Chest*. 2002;121(3):877-905.
7. Masotti L, Mannucci A, Antonelli F, Maurini V, Testa R, Marchetti S, Landini G, Cappelli R. The risk-based treatment of acute pulmonary embolism. *J Clin Med Res*. 2009;31(1):1-7.