

CASE REPORT

Accidental discovery of a hydatid cyst with primary presentation in an unusual location: a case report

Samaneh Kouzegaran¹, Amir Sabertanha²✉

¹ Department of Pediatrics, Valiasr Hospital, Birjand University of Medical Sciences, Birjand, Iran;

² Department of Anesthesia, Birjand University of Medical Sciences, Imam Reza Hospital, Birjand, Iran.

Received: December 31, 2016 Revised: April 6, 2017 Accepted: , April 12, 2017

Abstract

A hydatid cyst is a zoonotic infection caused by the larval forms of mostly the *Echinococcus granulosus*. In humans, the most common site of cyst development is the liver (60%), followed by the lungs (20%), and much less commonly in other organs such as kidney, spleen, brain, and other soft tissues. The localization of cysts in muscles and subcutaneous is very rare. We report a case of 38-year-old female patient with a cystic shoulder mass turning out to be hydatid cyst on surgical exploration.

However, especially in non-endemic regions, the most diagnostic tool for an unusual presentation is the awareness of the physician. Surgical excision is the main modality of treatment. Also, complementary investigation to rule out other organs' involvement is necessary. During surgical interventions, all precautions antiscolicidal solutions along with meticulous surgical techniques go a long way in the prevention of recurrence of this disease.

Key Words: Cyst; Hydatid; Shoulder; Subcutaneous tissue

Introduction

A hydatid cyst is a zoonotic infection caused by the larval forms of mostly the *Echinococcus granulosus* (1, 2). Hydatid cyst disease is widespread throughout southern Europe, Asia, Australia, Africa, and the Middle East, and the main host is predominantly dogs. The location and the complications such as rupture and immunological reactions are the main source of the patient's symptoms (3). In humans, the most common site of cyst development is the liver (60%), followed by the lungs (20%), and much less commonly, in other organs such as kidney, spleen, brain, and other soft tissues (4). The subcutaneous infection may be primary or secondary to the liver or lung involvement. According to the study of Chevalier, the incidence rate of subcutaneous hydatid cysts regardless of whether it is primary or secondary

was 2% (5). While the subcutaneous hydatid cysts are very rare, high diagnostic suspicion is very important both to treat other organs that may be involved simultaneously and to avoid a diagnostic puncture in subcutaneous cystic lesions. In this report, we introduce a case of hydatid cyst with primary presentation of painful mass in shoulder.

Cases

A 38-year-old woman was admitted in Imam Reza Hospital affiliated with Birjand University of Medical Sciences with a history of mass found in her shoulder for two months. On physical examination, there was a mobile and painful mass, about 5*6 cm in size, palpated over her shoulder. Laboratory tests revealed that CBC and electrolytes were within normal ranges. Sedimentation rate was 55. A differential diagnosis of abscess, soft tissue tumor, and lipoma were considered. The

©2016 Journal of Surgery and Trauma

Tel: +985632381203

Fax: +985632440488

Po Box 97175-379

Email: jsurgery@bums.ac.ir



✉ Correspondence to:

Amir Sabertanha, Department of Anesthesia, Birjand University of Medical Sciences, Imam Reza Hospital, Birjand, Iran.;

Telephone Number: 098563222600

Email Address: amirsaber43@yahoo.com

diagnosis of shoulder hydatid cyst was not considered since this localization is very rare. Due to anatomic appearance of the lesion, MRI was performed. MRI demonstrated a solid structure close to the shoulder (Fig. 1). The patient underwent surgery for resection of the mass lesion. Surprisingly, after incision and dissection of skin and subcutaneous tissues, we encountered a hydatid cyst wall. Following irrigation of cyst with hypertonic salt solution, the cyst was excised (Fig. 2). Histopathological examination revealed necrosis and clusters of histiocyte, inflammatory cells and fibroelastic activity; scoleces were also found in the surgical specimen. Given the probability of other sites' involvement, investigations consisting of chest and abdominal

CT scan were performed after surgery. CT investigations demonstrated a cyst in the middle lobe of the right lung. There were a small cyst in the liver and one in the spleen. Thus, for the patient, cyst resection of the middle lobe of the right lung was performed. Given the small size of cysts in the spleen and liver, the patient was followed for 6 months and treatment was done with a 3-month course of large doses of albendazole postoperatively. The patient once received albendazole 400 mg orally twice a day with meals in cycles of 4 weeks separated by 2 weeks without drugs. Following investigations after 4 and 6 months were not accompanied with any evidence of recurrence in these locations.

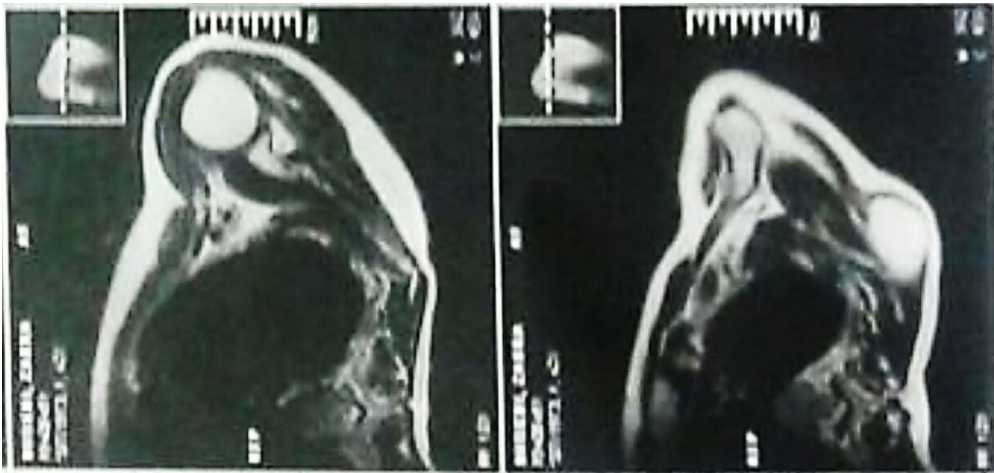


Figure 1: MRI showed a big mass (5 cm).



Figure 2- Hydatid cyst excised from the patient's shoulder

Discussion

Subcutaneous hydatid cysts may be primary or secondary. In secondary subcutaneous cysts, there is a primary organ involvement such as the liver, spleen or lung that may have been treated previously or not.

In cases with the first clinical presentation of subcutaneous involvement, it may cause a variety of diagnostic problems. In these patients, routine investigations are not usually effective for diagnosis. Although it seems that serological tests may be good aids in the diagnosis, usually serology alone is insufficient to diagnose hydatid cyst disease especially in patients with isolated soft tissue hydatid disease. Fine-needle aspiration cytology (FNAC) may be used as a primary modality for superficial diagnosis, it is discouraged however because of the risk of microscopic spillage during biopsy (6).

Sonography may be used to diagnose superficial swellings. The tissue hydatid cysts have a thin or thick wall with internal echoes caused by pericysts. Multiple echogenic foci due to hydatid sand may be evident giving the "snow storm" sign. Simple cysts do not demonstrate internal structure. On computed tomography scan, a well-defined cystic lesion with daughter cysts with or without septae or debris in it and no enhancement on intravenous contrast may be seen. MRI findings of hydatid cysts in the liver are well described, while the diagnosis in soft tissues is not well described (7-9). A low-intensity rim can be seen on both T1 and especially T2-weighted images. This rim is less developed in muscles. A cystic component may be seen with high-intensity signal without significant central uptake of paramagnetic contrast on T2-weighted images. Computed tomography or ultrasound-guided needle biopsies may also be helpful in diagnosis (10), but some authors do not recommend it because of the possibility of cyst rupture and anaphylactic reaction (11). However, especially in non-endemic regions, the most diagnostic tool for an unusual presentation is the awareness of the physician.

Conclusions

Subcutaneous *Echinococcus* infestation is a rare but important entity that is more frequently seen in rural areas. In cases with the first clinical presentation of subcutaneous involvement, it may cause a variety of diagnostic problems. However, the most diagnostic tool for an unusual presentation is the awareness of the physician. Surgical excision is the main modality of treatment.

Conflict of interest

The authors declare no conflict of interest.

References

1. Kazakos C, Galanis V, Verettas D-A, Polychronidis A, Simopoulos C. Primary hydatid disease in femoral muscles. *Journal of international medical research*. 2005;33(6):703-6.
2. Casero RD, Costas MG, Menso E. An unusual case of hydatid disease: localization to the gluteus muscle. *Clinical infectious diseases*. 1996;23(2):395-.
3. Yilmaz S, Gulcek M, Demirtas Y, Turan S. An unusual cause of mass in the shoulder: A primary hydatid cyst. *International journal of shoulder surgery*. 2014;8(2):58.
4. Agarwal S, Shah A, Kadhi SKM, Rooney RJ. Hydatid Bone Disease of the Pelvis: A Report of Two Cases and Review of the Literature. *Clinical orthopaedics and related research*. 1992;280:251-5.
5. Chevalier X, Rhamouni A, Bretagne S, Martigny J, Larget-Piet B. Hydatid cyst of the subcutaneous tissue without other involvement: MR imaging features. *AJR American journal of roentgenology*. 1994;163(3):645-6.
6. Ramadier J. *Revue de Chirurgie Orthopédique et Réparatrice de l'Appareil Moteur-90th anniversary. Revue de chirurgie orthopedique et reparatrice de l'appareil moteur*. 1980;67(3):161-3.
7. RASK MH, Lattig GJ. Primary intramuscular hydatidosis of the sartorius. *J Bone Joint Surg Am*. 1970;52(3):582-4.
8. Garcia-Diez A, Mendoza LR, Villacampa V, Cozar M, Fuertes M. MRI evaluation of soft tissue hydatid disease. *European radiology*. 2000;10(3):462-6.
9. Guthrie J, Lawton J, Chalmers A. Case report: the MR appearances of primary intramuscular hydatid disease. *Clinical radiology*. 1996;51(5):377-9.
10. Filice C, Di Perri G, Strosselli M, Pirola F, Brunetti E, Dughetti S, et al. Parasitologic findings in percutaneous drainage of human hydatid liver cysts. *Journal of infectious diseases*. 1990;161(6):1290-5.
11. Özkoç G, Akpınar S, Hersekli MA, Özalay M, Tandoğan R. Primary hydatid disease of the quadriceps muscle: a rare localization. *Archives of orthopaedic and trauma surgery*. 2003;123(6):314-6.