Journal of Surgery and Trauma 2016; 4(1-2): 7-10.

www.jsurgery.bums.ac.ir

ORIGINAL ARTICLE

The use of combined 3.5 LCP unicortical plate and nail fixation in proximal tibia fractures and prevention of valgus and anterior angulation

Reza Abdi[1]✉, Moein Aboobakri[2]

[1] *Assistant Professor, Department of Pediatric Orthopedics, Faculty of Medicine, Birjand University of Medical Sciences, Birjand, Iran*

[2] *Student of Medicine, Student Research Committee, Birjand University of Medical Sciences, Birjand, Iran*

Received: January 1, 2017 ***Revised: February 17, 2017*** ***Accepted: April 4, 2017***

Abstract

Introduction: Intramedullary nailing (IMN) of high tibia fracture has some mechanical and biological advantages over the other form of fixation. However, valgus, apex anterior malalignment and anterior displacement of proximal fragment commonly occur after isolated IMN fixation of proximal high tibia fracture. The purpose of this study is to determine the effectiveness of using 3.5-mm locking compression plate (LCP) with unicortical screws combined with IMN fixation to maintain the difficult reduction and prevent any displacement after classic nail insertion.

Methods: This cross-sectional study was performed between 2010 and 2012, thirty-three open or closed tibia fractures involving the high proximal tibia metaphysis were operated using combined 3.5 mm LCP unicortical plate with the classic reamed intramedullary nailing technique. The clinical and radiological results of the study were collected on the basis of the time to union, nonunion, malunion, degree of angulations at the fracture site, and infection. Follow-up ranged from 24 to 36 months (mean 28 months).

Results: The union rate was 100% on radiographs at 3.38 months postoperatively. No complications such as malunion, delayed union, implant failure, prominent valgus, anterior angulation malalignment, or postoperative deep infection occurred.

Conclusions: Although prominent malalignment occurs after IM nailing of proximal one-third tibia fractures, we can avoid it by using the medially inserted 3.5 LCP unicortical plate. The results are good even in open fracture type one or two.

Key Words: Nail; Tibia,Intramedullary; Proximal; Fracture; Fixation

Introduction

Open fracture and/or comminuted fracture of proximal one-third of tibia have frequently proved problematic, and the choice between plating or Intramedullary nailing (IMN) is a matter of debate.

Intramedullary fixation of tibia fracture has some mechanical and biological advantages over the other form of fixation. However, valgus, apex anterior malalignment, and anterior displacement of proximal fragment commonly occur after isolated intramedullary fixation of proximal tibia

©**2016 Journal of Surgery and Trauma**

Tel: +985632381203
Fax: +985632440488
Po Bax 97175-379
Email: jsurgery@bums.ac.ir

✉**Correspondence to:**
Reza Abdi , assistant professor of pediatric orthopaedics
birjand university of medical sciences - - Emam Reza hospital, Birjand, Iran ;
Telephone Number: +985632226777
Email Address: reza1352abdi@gmail.com

[Downloaded from jsurgery.bums.ac.ir on 2026-11-27]

Figure 1: Malreduction of segmental tibia fracture after isolated IMN fixation

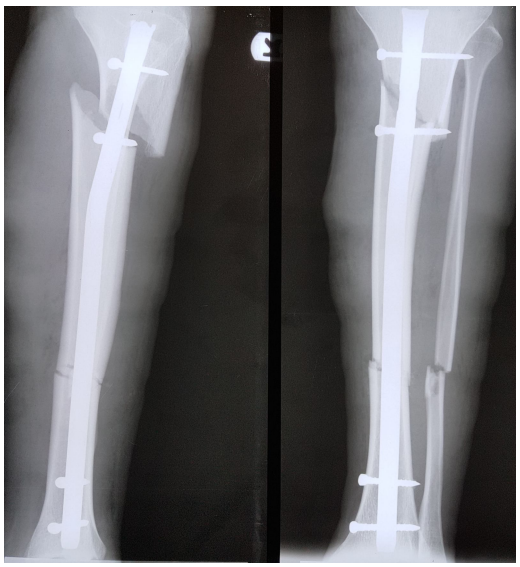

fracture (1-4) (Fig. 1).

Nevertheless, there is some evidence that using 3.5-mm LCP or DCP plates with unicortical screws combined with nailing can maintain the difficult reduction and prevent any displacement after nail insertion (5, 6). Nonetheless, there is a paucity of research about this technique.

This article describes the technique and results of the permanent 3.5 mm LCP unicortical plate fixation before nail insertion in proximal tibia fracture.

Methods

This cross-sectional study was performed between 2010 and 2012, thirty-three tibia fractures involving the high proximal metaphysis were operated using 3.5-LCP unicortical plates combinedki with classic reamed IMN technique by one senior trauma surgeon. The protocol of the study was approved by the Institutional Ethics Committee under the identifier IR.BUMS.REC.1394. 212. The inclusion criteria were displaced closed or open (Gustilo Anderson types I and II) displaced tibial proximal metaphyseal fractures.

Synthesis universal nail with one or two proximal transverse locking bolt(s) and 5- or 6-hole 3.5-mm LCP plate based on the fracture obliquity was used. The diameter of the nail was 10 or 11 mm based on the tibial canal diameter.

We used open reduction and permanent 3.5-LCP unicortical plate fixation of proximal tibial fracture before rimming fragments in 33 proximal one-third tibial fractures.

If the fracture was open medially (Gustilo Anderson types I and II), we used the plate through the wound after debridement without extensive soft tissue stripping. Almost always, the open wounds were medial whereby we applied the unicortical plate medially.

If the fracture was closed, we applied the plate upon the periosteal tissue with 4-5 cm medial proximal tibia incisions.

Because of the thin proximal metaphyseal cortex, we used LCP plate and locking screws. The jump distances between the threads in the locking screw is shorter than the cortical screw so more threads remain in the thin metaphyseal cortex, and more stability of plate fixation has been achieved.

Often, we used the 5-hole plate and two screws at either side of the fracture. However, in the comminuted or long oblique fracture, we used the 6-hole plate and three unicortical locking screws at either side of the fracture without soft tissue striping of the fragments.

IMN fixation of the fractures with medial parapatellar approach (not through patellar tendon) was accomplished routinely after plate fixation.

The clinical and radiological results of the study were collected on the basis of the time to union, nonunion, malunion, degree of angulations at the fracture site, and infection.

Follow-up ranged from 24 to 36 months (mean 28 months). All patients were assessed according to the malalignment, union and infection



periodically.

[Downloaded from jsurgery.bums.ac.ir on 2026-11-27]

Figure 2: Combined IMN and unicortical plate in the right open (Gustilo type I distal) tibial segmental fracture.

The ethics committee of Birjand University of Medical Sciences, Birjand, Iran, approved the study (approval code Ir.bums.REC.1394.212).

Results

Thirty-one patients were male and two were female. All patients had traffic accidents. The mean patient age was 34.3 (20-65) years. Most of the patients (n=20) were open, i.e., Gustilo-Anderson class type one or two (15 type I and 5 type II), while the remaining were closed. Among type I open fracture group, three cases had segmental metaphyseal-diaphyseal fracture (Fig. 1) .

The union rate was 100% on radiographs at 3.38 months (3 to 5 months) postoperatively. No complications such as implant failure, prominent valgus, anterior angulation malalignment, or postoperative deep infection occurred. However, two patients had superficial infections that were cured with oral antibiotics.

Mean valgus angulation at the fracture site was 2.61 (SD: 3.5 degree) without measurable anterior angulation at final follow-up.

Discussion

Among the frequent consequences of intramedullary fixation of proximal one-third of the tibial fracture are valgus, apex anterior malalignment, and anterior displacement of proximal fragment (1-4). A distal Herzog bend has a tendency to create a wedge effect, pushing the distal fragment posteriorly (4, 7). Malreductions of 5 degrees or more in proximal tibial fractures using isolated IMN is well documented. The incidences of malreduction rates range from 3% to 100% (8, 9).

However, various methods have been introduced to avoid malalignment after nailing of one-third proximal tibial fractures. Yet, isolated plating still remains as the standard method of fixation.

Meanwhile, blocking screws or supplemental plate fixation when combined with IMN can achieve stable, well-aligned fixation (6, 8-11). However, there are few clinical trials to show a clear advantage with plating and nailing of proximal tibial fractures (4, 12).

In 1997, Mattews described the anterior unicortical buttress plating before nail placement and in combination with unreamed intramedullary nailing to avoid valgus malalignment (13).

In 2005, Dunbar used dynamic compression plate placed through the open wound in type III open tibial shaft fractures before intramedullary nailing (6).

In 2006, Nork used provisional plate with IMN in open and closed proximal tibial fractures and reported acceptable alignment in approximately 92% of the cases at a mean 19-month follow-up period (5).

There is a paucity of evidence about the plate fixation before IMN of proximal tibial fracture. Nonetheless, all of them recommend the method (2, 5, 6, 11, 13, 14).

Plating of closed or open fractures of proximal tibia before IMN allows to avoid displacement of fragments after nail insertion. Plates are especially useful in situations where techniques such as blocking screws are contraindicated, e.g., osteoporosis, severe comminution, articular extension, etc. (4, 11).

Also, percutaneous supplemental plate fixation without soft tissue stripping can be used during closed fractures (4, 11) .

We used open reduction and permanent 3.5-LCP unicortical five- or six-hole plate fixation of proximal tibial fracture without soft tissue striping of fragments before rimming of fragments in 33 proximal one-third tibial fracture. IMN insertion was through classic medial parapatellar approach.

Follow-up ranged from 24 to 36 months. Mean valgus angulation at the fracture site was 2.61(SD: 3.5 degree) without measurable anterior angulation at last follow-up. The union rate was 100% on radiographs. No complications such as implant failure, prominent valgus or anterior angulation malalignment or postoperative deep infection occurred.

Conclusions

In summary, although prominent malalignment occurs after IMN of proximal one-third tibial fractures, we can avoid it by using medially inserted 3.5 LCP unicortical plate. The results are good even in the case of open fracture type one or two.

This study is based on retrospective evidence and clinical trials are needed to definitively assess and compare the results of various fixation procedures in tibial proximal metaphyseal fractures.

Acknowledgment

The authors thank participated patients and Imam Reza Hospital staff in the general operating room and surgical wardfor their contribution to this study.

[Downloaded from jsurgery.bums.ac.ir on 2026-11-27]

Conflict of interest

The authors declare no conflict of interest.

References

1. Freedman EL, Johnson EE. Radiographic analysis of tibial fracture malalignment following intramedullary nailing. Clinical orthopaedics and related research. 1995 Jun(315):25-33.
2. Kim KC, Lee JK, Hwang DS, Yang JY, Kim YM. onal unicortical plating with reamed intramedullary nailing in segmental tibial fractures involving the high proximal metaphysis. Orthopedics. 2007 Mar;30(3):189-92.
3. Lang GJ, Cohen BE, Bosse MJ, Kellam JF. Proximal third tibial shaft fractures. Should they be nailed? Clinical orthopaedics and related research. 1995 Jun(315):64-74.
4. Tejwani N, Polonet D, Wolinsky PR. Controversies in the intramedullary nailing of proximal and distal tibia fractures. The Journal of the American Academy of Orthopaedic Surgeons. 2014 Oct;22(10):665-73.
5. Nork SE, Barei DP, Schildhauer TA, et al. Intramedullary nailing of proximal quarter tibial fractures. Journal of orthopaedic trauma. 2006 Sep;20(8):523-8.
6. Dunbar RP, Nork SE, Barei DP, Mills WJ. Provisional plating of Type III open tibia fractures prior to intramedullary nailing. Journal of orthopaedic trauma. 2005 Jul;19(6):412-4.
7. Henley MB MM, Tencer AF. Influences of some design parameters on the biomechanics of the unreamed tibial intramedullary nail. J Orthop Trauma. 1993;7(4):311-9.
8. Krettek C, Stephan C, Schandelmaier P, Richter M, Pape HC, Miclau T. The use of Poller screws as blocking screws in stabilising tibial fractures treated with small diameter intramedullary nails. The Journal of bone and joint surgery British volume. 1999 Nov;81(6):963-8.
9. Krettek C, Miclau T, Schandelmaier P, Stephan C, Mohlmann U, Tscherne H. The mechanical effect of blocking screws ("Poller screws") in stabilizing tibia fractures with short proximal or distal fragments after insertion of small-diameter intramedullary nails. Journal of orthopaedic trauma. 1999 Nov;13(8):550-3.
10. Ricci WM, O'Boyle M, Borrelli J, Bellabarba C, Sanders R. Fractures of the proximal third of the tibial shaft treated with intramedullary nails and blocking screws. Journal of orthopaedic trauma. 2001 May;15(4):264-70.
11. Liporace FA, Stadler CM, Yoon RS. Problems, tricks, and pearls in intramedullary nailing of proximal third tibial fractures. Journal of orthopaedic trauma. 2013 Jan;27(1):56-62.
12. Lindvall E, Sanders R, Dipasquale T, Herscovici D, Haidukewych G, Sagi C. Intramedullary nailing versus percutaneous locked plating of extra-articular proximal tibial fractures: comparison of 56 cases. Journal of orthopaedic trauma. 2009 Aug;23(7):485-92.
13. Matthews DE MR, Freeland AE. Anterior unicortical buttress plating in conjunction with an undreamed interlocking intramedullary nail for treatment of very proximal tibial diaphyseal fractures. Orthopedics. 1997;20(7):647-8.
14. Benirschke SK HM, Ott JW. Proximal one-third tibial fracture solutions. Orthopaedic Transactions. 1995;18:1055-6.

[Downloaded from jsurgery.bums.ac.ir on 2026-11-27]