

ORIGINAL  
ARTICLE**A retrospective epidemiologic study on upper extremity tumors  
in Firozgar Hospital**Seyed Hamzeh Mousavie<sup>1</sup>, Shahram Nazerani<sup>2✉</sup>, Jalil Shoa Alhasani<sup>3</sup>,  
Ali Reza Negahi<sup>1</sup>, Pooya Derakhshan<sup>4</sup><sup>1</sup> Assistant Professor of General Surgery, Department of Surgery, Iran University of Medical Sciences, Rasool akram Hospital, Tehran, Iran<sup>2</sup> Professor of General Surgery, Department of Surgery, Iran University of Medical Sciences, Rasool akram Hospital, Tehran, Iran<sup>3</sup> Department of Surgery, Iran University of Medical Sciences, Rasool akram Hospital, Tehran, Iran<sup>4</sup> Assistant Professor of Anesthesiology, Department of Anesthesiology, Iran University of Medical Sciences, Rasool akram Hospital, Tehran, Iran

Received: February 5, 2017

Revised: June 10, 2017

Accepted: July 3, 2017

**Abstract****Introduction:** Epidemiologic data of upper extremity tumors are still few and sometimes conflicting. In our department, hand surgeons manage these tumors. Good documentation of patients' information permitted us to make an epidemiologic study on the tumors of the upper extremity operated in our department.**Methods:** We retrospectively studied all the cases of upper extremity tumors operated from 1992 to 2012. The required files were collected from the hospital's databank and the pathology report from the registry of the department of histology.**Results:** The mean age of patients was 37.91 years (from 3 to 83 years). The series included 100 patients (60 women and 40 men). Tumors concerned soft tissues in 78 cases (78%), bone in 18 cases (18%), and skin in 4 cases. Nearly all the malignant hand tumors were found in men (5 males, one female).**Conclusions:** The data are comparable to other published studies. Upper extremity tumors are more prevalent in females (60%). The prevalence of bone tumors (18%) in our study is greater than other studies (from 1.6% to 11.4%) and the prevalence of skin tumors is lower (4%). Except for skin tumors where recruitment modalities are more variable, this series seems to be a good reflection of the prevalence of the different types of hand and wrist tumors.**Key Words:** Upper extremity, Bone tumor, Skin tumor, Osteosarcoma, Lipoma**Introduction**

There are different types of upper extremity tumors most of which are benign (1). They can originate from skin, subcutaneous tissue, tendons,

nerves, vascular tissue and bone (2, 3). Except for coetaneous malignant tumors, other malignant tumors of the hand are rare where only one case has been reported (1). Squamous cell carcinoma (SCC) gives up to 58 to 90 percent of hand

@2016 Journal of Surgery and  
Trauma  
Tel: +985632381203  
Fax: +985632440488  
Po Bax 97175-379  
Email: jsurgery@bums.ac.ir

**✉ Correspondence to:**

Shahram Nazerani, Professor of General Surgery, Department of Surgery, Iran University of Medical Sciences, Rasool akram Hospital, Tehran, Iran;  
Telephone Number: +989121112216  
Email Address: snazeranimd@gmail.com

malignant tumors and is 5 times more common in males (1-4).

Mixed tumors occur commonly in the salivary glands and the skin. Mixed tumors of soft tissues were recognized as a separate entity only recently, and there are a limited number of case reports to date (5).

Upper extremity sarcomas in children are very uncommon. Rhabdomyosarcoma is the most common soft tissue tumor in childhood. According to a survey, 16 percent of rhabdomyosarcoma cases can occur in the hand (6). Giant cell tumors of the hand are very rare, and only 2% of the reported cases occur in this site (7). In addition, leiomyoma is rare. Since 1960 to 2009, just 160 cases of hand leiomyoma have been reported in the UK (8). Only 5 to 15 percent of Osteoid osteoma cases, which was first described in 1935 by Jaffe, occur in the wrist and hand (9).

Angioleiomyomas are benign, solitary, smooth muscle tumors that can arise anywhere in the body. They originate from the tunica media layer of vessel walls and are uncommon in the hand. The majority of these tumors in the hand were reported as arising from the veins; only a few cases were reported to arise from the arteries of the hand (10). Lipomas are rare in the upper extremity but are now considered common among soft tissue tumors of the hand (11, 12). We decided to study patients with upper extremity soft tissue tumor epidemiologically and determine their pathologic subtypes. This study is registered in the ethics committee of Iran University of Medical Sciences with the following code: IR.IUMS.REC.1390.90001057345.

## Methods

We included in this descriptive retrospective study all the patients who referred to Firozgar Hospital of Tehran with upper extremity tumor. The demographic characteristics of 100 patients, who were admitted and operated in the hospital between 1992 and 2012, were recorded.

All the data such as sex, age, pathological reports, and site of tumor were gathered. The collected data were analyzed with SPSS 14.0 (SPSS Inc., USA) and expressed as the mean±SD or the frequency of patients.

## Results

Between 1992 and 2012, 120 patients were operated; however, there were only 100 patients whose complete record with all the data, especially pathological report, was available. Of these 100, 60

were females and 40 males, with the mean age of 37.91 years (range 3 to 83). The most prevalent tumors were synovial cyst (28%), glomus tumor (16%), and hemangioma (10%) (Figure 1). Tumors comprised of soft tissue in 78 cases (78%), bone in 18 cases (18%), and skin in 4 cases (Figure 2). Six percent of the cases had malignant tumors including 3% SCC, 1% leiomyosarcoma, 1% fibrosarcoma, and 1% osteosarcoma.

## Discussion

Our data are comparable to those from other studies. Since 1992 to 2012, in a twenty years' period, 42,590 patients were operated in the general and orthopedic surgery departments of Firozgar Hospital. A total of 100 cases or 0.235% was operated for upper extremity tumors. This finding shows the rare incidence of these tumors (12). The mean age of tumor presentation (37.91) is identical to other studies (5). Similar to previous studies, upper extremity tumors are more prevalent in females (60%). The prevalence of bone tumors (18%) is higher than those in other studies (from 1.6 to 11.4%), while the prevalence of skin tumors is lower (4%) (5, 7, 9). However, in line with previous findings, soft tissue is the most common source (78%). Prevalence of malignancy (6%) is higher than other studies (7). Therefore, from all the patients who were operated in this period, just 0.014% had malignant tumors of upper extremity, three percent of which originated from skin, implying that most of upper extremity tumors originate from this tissue layer.

Also, with the exception of one case, other five malignant cases occurred in male patients. This finding suggests that malignant tumors of upper extremity are more prevalent in males. We found that while our patients' tumors are more benign especially in soft tissue, but malignancy of bone tissue in our patients is more than other studies, so we conclude that we should schedule more studies with larger sample sizes and focus on etiological studies about malignant upper extremity tumors.

**Conflict of Interest:** None

## References

1. Canale ST, Beaty JH. Campbell's Operative Orthopaedics E-Book. Elsevier Health Sciences; 2012 Oct 29.
2. Charles BF, Dana K, Timothy R, David L, John G, Raphael E. Schwartz's principles of surgery. Lal G, Clark HO Thyroid, parathyroid, adrenal McGraw

Hill Company, Ninth Edition, Newyork. 2010:1343-408.

3. Gebhardt MC. Sarcomas of the upper extremity in children. J Pediatr Orthop. 2010 Mar 1;30:S27-30.

4. Klenke FM, Wenger DE, Inwards CY, Rose PS, Sim FH. Giant cell tumor of bone: risk factors for recurrence. Clin Orthop Relat Res. 2011 Feb 1;469(2):591-9.

5. Kransdorf MJ. Benign soft-tissue tumors in a large referral population: distribution of specific diagnoses by age, sex, and location. AJR Am J Roentgenol. 1995 Feb;164(2):395-402.

6. Kulkarni AR, Haase SC, Chung KC. Leiomyoma of the hand. Hand. 2009 Jun;4(2):145-9.

7. Lohman RF, Nabawi AS, Reece GP, Pollock RE, Evans GR. Soft tissue sarcoma of the upper extremity. Cancer. 2002 Apr 15;94(8):2256-64.

8. Nadar MM, Bartoli CR, Kasdan ML. Lipomas of the

hand: a review and 13 patient case series. Eplasty. 2010;10.

9. Saikia KC, Bhuyan SK, Goswami S, Bora A. Rare site giant cell tumors: report of two cases on phalanges of the finger and review of literature. J Orthop Traumatol. 2009 Dec 1;10(4):193-7.

10.Sforzo CR, Scarborough MT, Wright TW. Bone-forming tumors of the upper extremity and Ewing's sarcoma. Hand Clin. 2004 Aug 1;20(3):303-15.

11.Shafi M, Hattori Y, Doi K. Angioleiomyoma of distal ulnar artery of the hand. Hand. 2010 Mar;5(1):82-5.

12.Shimosawa H, Susa M, Honma T, Hiraishi E, Sakihara H. Soft tissue mixed tumor of the hand. Rare Tumors . 2009 Dec 28;1(2).

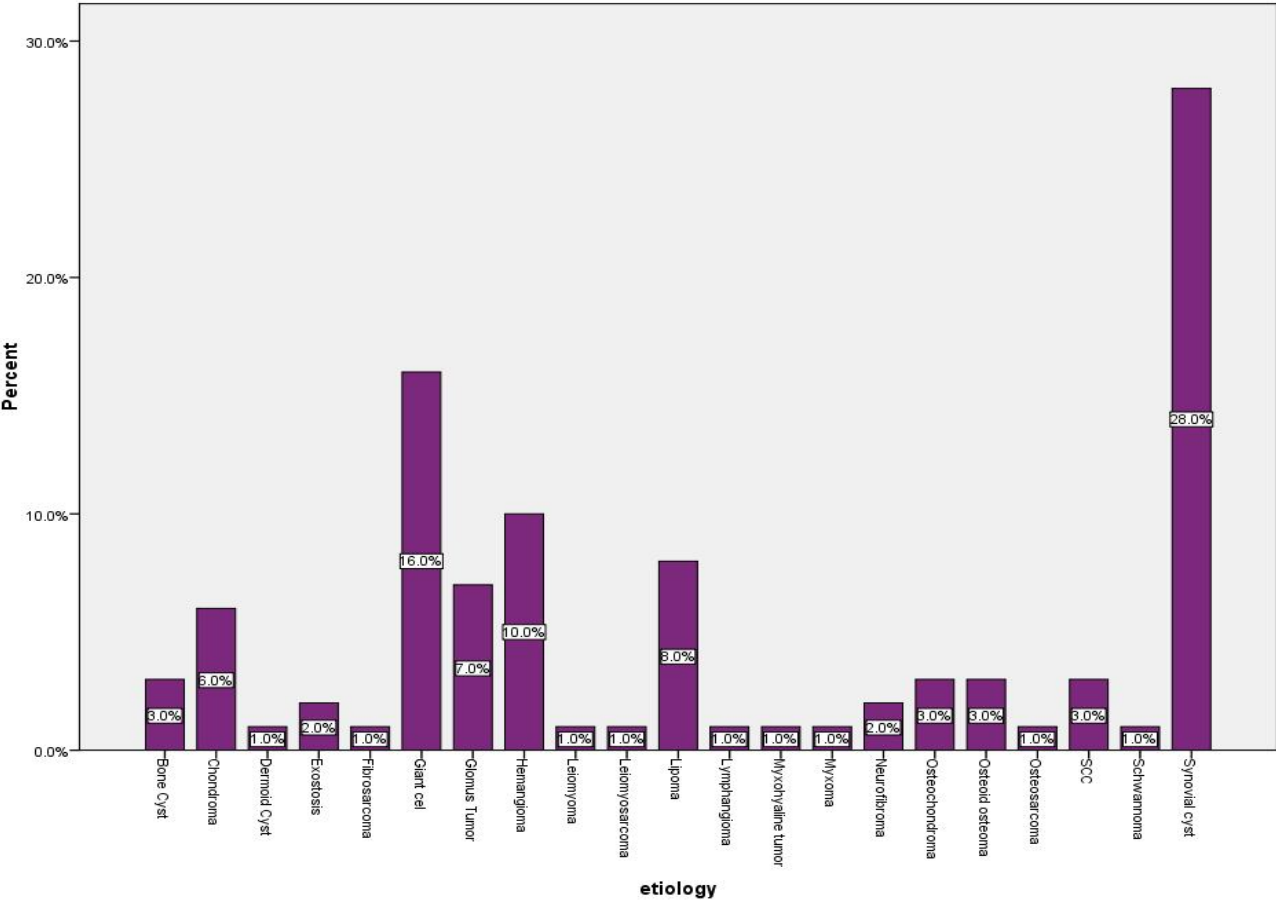


Figure 1: Histogram of tumor prevalence

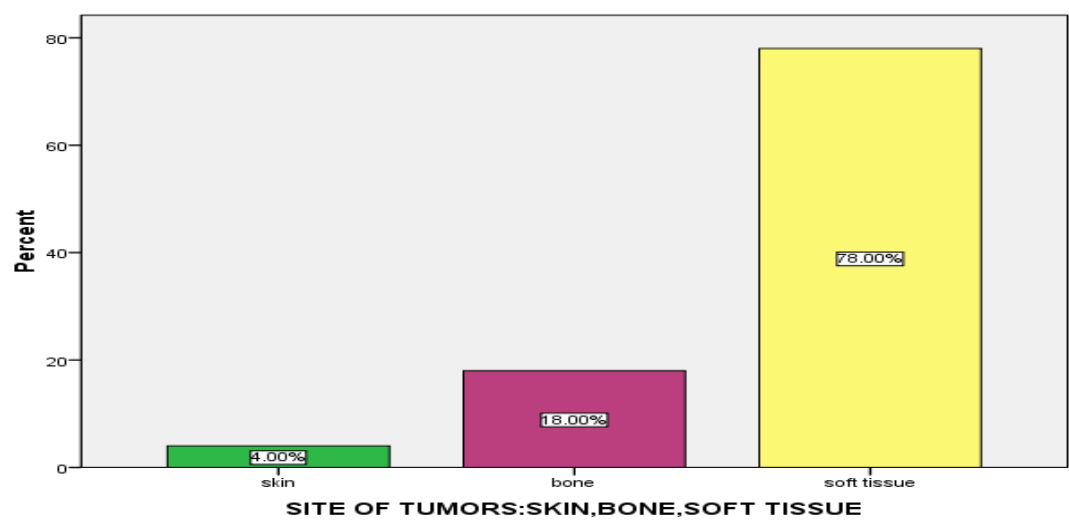


Figure 2: Histogram of tumor site