

# CASE REPORT

## Misdiagnosis of Ocular Leech Infestation

Seyyed Abbas Hosseinirad<sup>1</sup>✉, Gholamhossein Yaghoubi<sup>2</sup>, Behrouz Haidari<sup>1</sup>

<sup>1</sup> Assistant Professor, Department of Ophthalmology, Faculty of Medicine, Birjand University of Medical Sciences, Birjand, Iran

<sup>2</sup> Professor, Department of Ophthalmology, Faculty of Medicine, Birjand University of Medical Sciences, Birjand, Iran

Received: May 6, 2017

Revised: August 2, 2017

Accepted: August 16, 2017

### Abstract

Leeches are segmented worms belonging to Phylum Annelida and make up the subclass Hirudinea. Leeches have been historically used in medicine to suck blood from patients. Ocular infestation with leech is rare, moreover it is often misdiagnosed. In this report, we describe 2 patients with continuous bright ocular bleeding after swimming in a pool, and pseudo iris prolapse in a child after trauma with a wooden piece who immediately washed his face in a stream. Ocular leech infestation must be ruled out in children with a history of contamination or swimming in rural pool or streams.

**Key Words:** Ocular; Infection; Leeches

### Introduction

Leeches are segmented worms belonging to Phylum Annelida and make up the subclass Hirudinea<sup>1</sup>. Most leeches tend to live in fresh water environments; however, some species can be found in terrestrial and marine environments<sup>2</sup>. They have two suckers, one at each end. Most leeches are hematophagous as they are predominantly blood suckers that feed on blood from animals. Leeches have been historically used in medicine to suck blood from patients<sup>3</sup>. Although ocular infestation with leeches is rare, several case reports have made it important due to unusual ocular symptoms. In this report, we describe 2 patients with continuous bright ocular bleeding after swimming in a pool, and pseudo iris prolapse in a child after trauma with a wooden piece who immediately washed his face in a stream.

### Cases

The first case was an 8-year-old boy presented

to the emergency room of Vali-asr Hospital of Birjand, Iran on July 2<sup>nd</sup>, 2013, suffering from ocular bleeding since the day before. His father stated that his symptoms had started when the child was swimming in a small pool near their home. There was no history of blunt or sharp trauma to his eyes. History for coagulopathy disorder was negative. Visual acuity was 20/20 in both eyes. Slit lamp biomicroscopy of the right eye showed continuous hemorrhage from the ocular surface. We found a large mobile foreign body attached to the supratemporal conjunctiva (Fig. 1).

There was no view of hyphema or intraocular inflammation. Post-segment examination including indirect ophthalmology was normal. This large foreign body was an alive leech sucking blood from bulbar conjunctiva. After instillation of tetracaine eye drop into inferior fornix, the leech was grasped with a tying forceps and pressed to detach from conjunctiva. After a few seconds, the leech's suckers were removed from the patient's eye. Chloramphenicol and betamethasone eye drops

©2017 Journal of Surgery and Trauma

Tel: +985632381203

Fax: +985632440488

Po Box 97175-379

Email: jsurgery@bums.ac.ir



✉ Correspondence to:

Seyyed Abbas Hosseinirad, Assistant Professor, Department of Ophthalmology, Faculty of Medicine, Birjand University of Medical Sciences, Birjand, Iran;

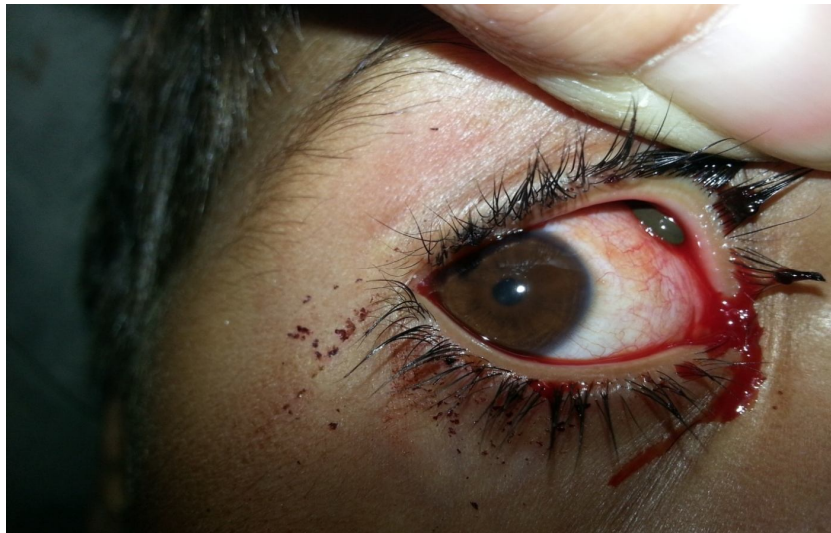Telephone Number: +989151615021

Email Address: ahrad2@yahoo.com

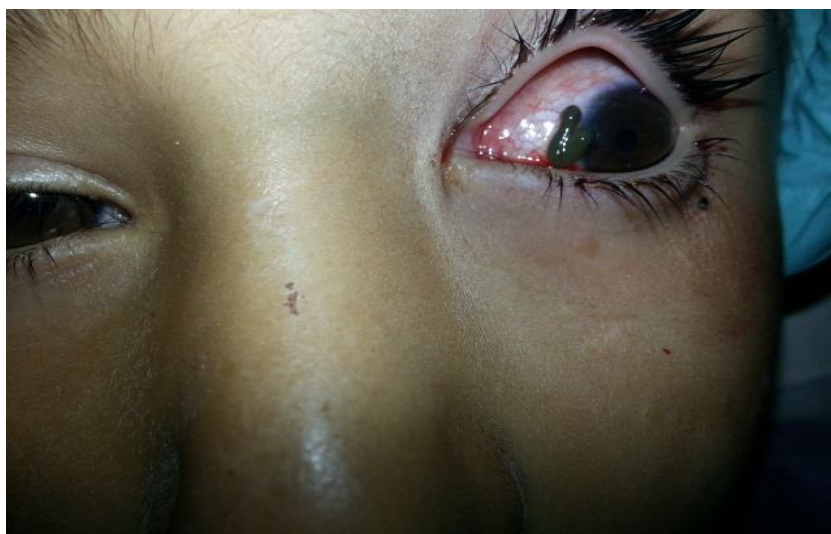
(every 6 hours) were prescribed. On the next day, the patient was visited. There was no symptom in the right eye and only slight subconjunctival hemorrhage was noted at the site of leech attachment.

The next case was a 9-year-old boy referring to our department by a general physician with diagnosis of globe rupture and iris prolapse (Fig. 2). There was a history of quarrel with his classmates and he said that one of his friends throw a piece of wood toward his left eye. There was no decrease in visual acuity of his left eye, and slit lamp biomicroscopy revealed a large green mass near the nasal limbus very similar to iris prolapse. However, it was

understood that the globe was intact and the anterior chamber, pupil, lens, and anterior vitreous examination were in normal range. In fact, this foreign body was an alive leech attached to limbus while sucking blood from the bulbar conjunctiva. Meticulous history of this child revealed that after trauma, he started to bleed from the wound of his left eye. Then he went to wash his face in stream water, where the leech attached to his eye. Similar to the previous case, after instillation of lidocaine eye drop to inferior fornix, the leech was grasped with a tying forceps and removed from the eye. The day after, there was no bleeding and ocular symptoms.



**Figure 1: Bloody tear and hidden leech at superior fornix**



**Figure 2: Leech attached at limbus similar to iris prolapsed**

## Discussion

Leeches can attach to the mucosal surfaces such as the nasal cavity<sup>4</sup>, oropharynx<sup>5</sup>, and the eye<sup>6,7</sup>. Ocular infestation with leeches is rare where unusual symptoms make the correct diagnosis difficult in some cases. Katbob describes a case of leech infestation with profuse ocular surface bleeding after washing face in stream water. Lewis<sup>7</sup> also reported an adult ocular leech infestation during a trekking expedition to the Borneo jungle. He removed the leech after direct application of cooking salt to the leech and gentle traction with forceps due to the unavailability of the topical anesthetic drops.

Khodabande also reported a case of adult ocular leech infestation. Chief complaint of his case was bloody tear. He was a farmer in a rural society and after washing his face in stream water, a leech attached to the inferotemporal bulbar conjunctiva.

Rubi reported another case of ocular leech infestation in a 67-year-old man. His chief complaint was red eye, ocular discomfort and sensation of something moving in his right eye. Like other cases, his symptoms started when he washed his face in stream water.

When Wei-Li presented a case of ocular infestation, he initially misdiagnosed it as conjunctival pigmented nevus. In his case, there was no hemorrhage and the patient had visited two doctors before going to the author while suffering from red eye, slight pain, and occasional foreign body sensation for one week. Diagnosis of previous physicians was conjunctival nevus.

Several methods of leech removal have been introduced, but in our cases, instillation of tetracaine eye drops was enough for the removal.

## Conclusions

Ocular leech infestation can masquerade several ocular conditions such as globe rupture and iris prolapse, bloody tear, conjunctival nevus, and subconjunctival hemorrhage. This can be confusing

for medical students and junior physicians for correct diagnosis of leech infestation.

Although ocular leech infestation is rare, it must not be ruled out in patients with a history of swimming in rural pools or washing face in stream water if they have such bizarre symptoms.

## Conflict of Interest

The authors declare no conflict of interest.

## References

1. Buchsbaum R, Buchsbaum M, Pearse J, Pearse V. Animals without backbones: an introduction to the invertebrates. University of Chicago Press; 2013.
2. Fogden SC, Proctor J. Notes on the feeding of land leeches (*Haemadipsazeylanica* Moore and *H. picta* Moore) in Gunung Mulu National Park, Sarawak. *Biotropica*. 1985;17(2):172-4.
3. Payton B. History of medicinal leeching and early medical references. *Neurobiology of the Leech*. 1981:27-34.
4. Chow CK, Wong SS, Ho AC, Lau SK. Unilateral epistaxis after swimming in a stream. *Hong Kong Med J*. 2005;11(2):110-2.
5. Estambale BB, Knight R, Chung R. Haematemesia and severe anaemia due to a pharyngeal leech (*Myxobdella africana*) in a Kenyan child: a case report. *Trans R Soc Trop Med Hyg*. 1992;86(4):458.
6. Alcelik T, Cekic O, Totan Y. Ocular leech infestation in a child. *Am J Ophthalmol*. 1997;124(1):110-2.
7. Katbob A, Ghassemifar Roozitalab MH. Bloody tears caused by ocular leech infestation. *Asian J ophthalmol*. 2006;8:164-5
8. Lewis G, Coombes A. Adult ocular leech infestation. *Eye (Lond)*. 2006;20(3):391-2.
9. Rubi Dey DO, Dey S. Ocular leech infestation. *Arch Iran Med*. 2010;13(5):440-2.
10. Li WW, Shen T, Jiang J. Ocular leech infestation initially misdiagnosed as conjunctival pigmented nevus. *Int J Ophthalmol*. 2013;6(4):557-8.