



Case Report

Utilizing amniotic membrane in the treatment of sever forehead skin avulsion on a 2-year-old boy

Mehrdad Shahraki <sup>1</sup> , Mohammad Rasool Asadi <sup>2</sup> , Sadra Amirpour Haradasht <sup>3</sup>

<sup>1</sup> Assistant professor, Oral and Maxillofacial Surgery Department, School of Dentistry, Zahedan University of Medical Sciences, Zahedan, Iran

<sup>2</sup> Dental Student, School of Dentistry, Zahedan University of Medical Sciences, Zahedan, Iran

<sup>3</sup> Maxillofacial Resident, Department of Oral and Maxillofacial Surgery, School of Dentistry, Zahedan University of Medical Sciences, Zahedan, Iran

**Corresponding author:**

Tel: +989114704715

Email: [sadrahadasht@gmail.com](mailto:sadrahadasht@gmail.com)

---

**Abstract**

Amniotic membrane, an effective substitute in reconstructing soft tissue defects, facilitates wound healing, and scar reduction, and contributes to skin beauty enhancement. This transparent membrane rich in growth factors, cytokines, and matrix proteins facilitates tissue repair. Its utilization in medicine, including ophthalmology and plastic surgery, significantly improves treatment outcomes. In the present study, a case of severe soft tissue injury reconstruction in a two-year-old child is reported. The use of amniotic membrane for reconstructing skin injuries and traumas in the forehead area improves wound healing, reduces scarring, and enhances beauty outcomes. This approach is one of the effective methods in managing facial traumatic injuries in children, with the ability to accelerate wound healing, reduce scarring, improve patients' quality of life, and enhance beauty outcomes.

**Keywords:** Amniotic Membrane, Forehead, Pediatric, Skin, Facial Surgery

---

**Citation:** Shahraki M, Mohammad Rasool Asadi, AmirPour Haradasht S. Utilizing amniotic membrane in the treatment of sever forehead skin avulsion on a 2-year-old boy. J Surg Trauma. 2024; 12(1): 33-37.

*Received: June 7, 2024*

*Revised: June 26, 2024*

*Accepted: July 22, 2024*

---

## Introduction

Soft tissue injuries to the forehead can be challenging to reconstruct due to the complex anatomy and visibility of the area (1). Traditional methods of repair often result in unsightly scars and poor cosmetic outcomes. However, recent advancements in regenerative medicine have introduced amniotic membranes as a promising alternative for soft tissue reconstruction (2,3). The amniotic membrane is a thin, transparent membrane surrounding the fetus during pregnancy. It is rich in growth factors, cytokines, and extracellular matrix proteins that promote tissue regeneration and wound healing (3,4). In recent years, amniotic membrane has gained popularity in various medical fields, including ophthalmology, dermatology, and plastic surgery, for its ability to enhance wound healing and reduce scarring. When used in forehead soft tissue laceration reconstruction, the amniotic membrane offers several advantages over traditional methods. Firstly, it provides a natural setting for cell proliferation, promoting faster wound closure and reducing the risk of infection. Additionally, its anti-inflammatory properties help minimize swelling and discomfort post-operatively (4,5). Furthermore, amniotic membranes have been shown to improve cosmetic outcomes by reducing scar formation and promoting more natural-looking skin regeneration. Its transparent nature allows for better integration with surrounding tissues, resulting in a seamless appearance once the wound has healed (6,7). This paper examines the application of amniotic membranes in reconstructing severe skin avulsion in a 2-year-old boy, suggesting its potential to advance facial reconstruction methods for pediatric patients. Through this case study, we aim to illustrate the profound impact of this technique and its implications for future clinical practice.

## Case

We present the case of a 2-year-old male child who was admitted to the Maxillofacial Surgery department of Zahedan University of Medical Sciences following a traumatic incident resulting in a severe forehead skin avulsion injury.

The patient had sustained the injury from a household accident, leading to a significant loss of skin tissue on the forehead region. The exposed area

extended from the hairline to the mid-eyebrow level, exposing underlying structures such as muscle and subcutaneous tissue. The complexity of the injury raised concerns regarding functional and aesthetic reconstruction in this young patient. Upon initial evaluation, the patient was found to be in stable condition with no other associated injuries.

The extent of the forehead skin avulsion injury was carefully assessed, revealing the challenges associated with traditional reconstructive methods due to the unique characteristics of pediatric facial tissues. Initial debridement and suturing are indicated for specific lacerations where the wound edges align (Figure 1).

Given the critical nature of the injury and the importance of achieving optimal outcomes, innovative approaches using regenerative techniques were considered to address the extensive soft tissue loss. In light of recent advances in regenerative medicine, a decision was made to employ an amniotic membrane for the reconstruction of the severe forehead skin avulsion injury in the 2-year-old boy (Figure 2).

The amniotic membrane, sourced from a reputable tissue bank, was meticulously prepared and applied to the exposed area following thorough debridement and irrigation.

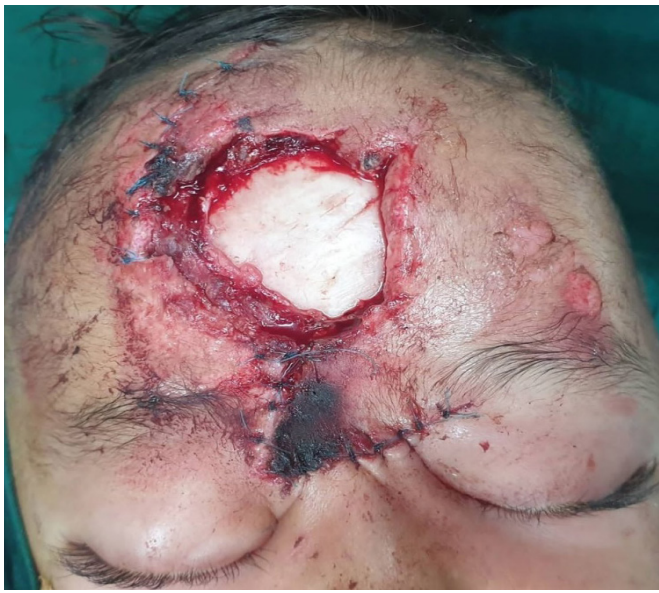Leveraging the regenerative properties of amniotic membranes, including their anti-inflammatory, anti-scarring, and wound-healing capabilities, was deemed crucial in promoting tissue regeneration and facilitating optimal wound closure. Following the application of the amniotic membrane, the patient demonstrated promising progress in the healing process (Figure 3).

Over the next 12 weeks, gradual re-epithelialization and tissue regeneration were observed, leading to the restoration of the natural contour of the forehead region. The use of amniotic membranes played a pivotal role in promoting efficient wound healing, minimizing scar formation, and reducing the risk of functional impairment. Six months post-accident, the patient's wound showed satisfactory healing (Figure 4).

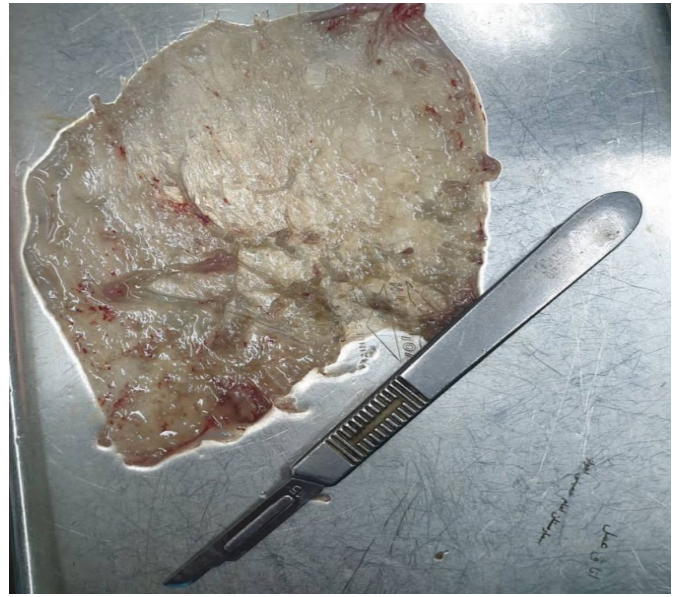
Subsequent follow-up assessments revealed excellent cosmetic outcomes, with minimal scarring and satisfactory aesthetic results. This method of facial reconstruction offers a less intrusive and highly efficient solution for severe skin avulsions. This case report was conducted as part of a research

study to investigate the clinical and demographic characteristics of patients with facial trauma in the

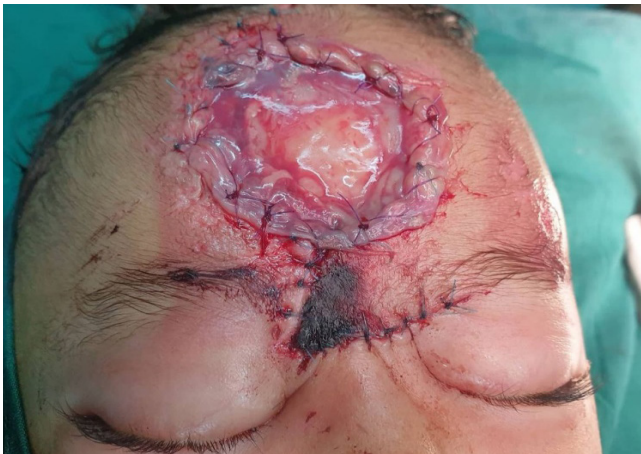emergency department of Zahedan Khatam-al-Anbia Hospital in 1402 (IR.ZAUMS.REC.1402.356).



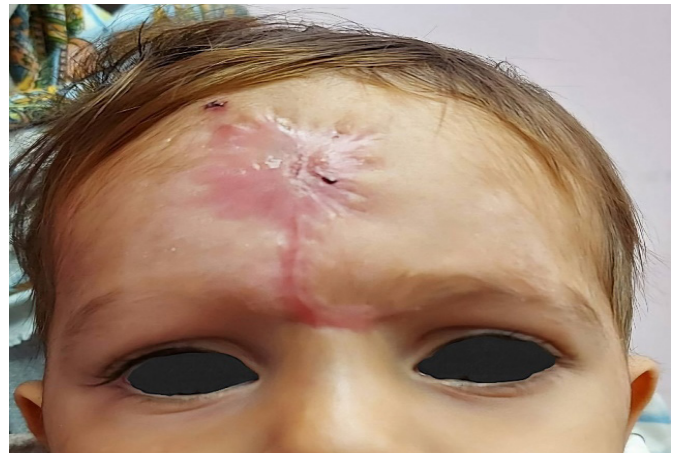**Figure 1.** Patient's forehead Injury



**Figure 2.** Amniotic Membrane



**Figure 3.** Utilization of amniotic membrane for severe soft tissue reconstruction in the forehead area



**Figure 4.** Six months post-reconstruction of the area

## Discussion

This report demonstrates that the use of amniotic membranes in managing severe forehead skin defects in pediatric patients holds incredible potential. The properties of the amniotic membrane not only aid in wound healing but also yield aesthetically pleasing results and desirable functional outcomes (6,8). Severe injuries to the structures of the forehead pose significant challenges due to the intricate anatomy and critical aesthetic considerations of the face (9).

Traditional treatment options include skin grafting, local flaps, or primary closure, but these can lead to suboptimal functional and aesthetic outcomes. Reconstruction using amniotic membrane has emerged as a promising alternative, utilizing the unique properties of amniotic membrane to enhance wound healing and minimize scarring (10). Amniotic membrane reconstruction is a surgical technique that utilizes the amniotic membrane, the innermost layer of the placenta, to promote healing and tissue



regeneration in various areas of the body. . This technique has gained significant interest in recent years due to the unique properties of the amniotic membrane. Amniotic membranes can be used in facial reconstruction surgeries, especially after trauma or burns, to improve wound healing and minimize scarring. It's particularly beneficial in areas with delicate or complex anatomy like the forehead, due to its ability to promote tissue regeneration while preserving aesthetics (11). Compared to skin grafting, it should be noted that skin grafts only provide coverage and reconstruction of the skin area without muscle regeneration, which can result in cosmetic deficits (due to tissue depression) and functional impairments (due to muscle absence) (3, 12). When compared to local flaps, despite their high success rates due to the preservation of vascular supply, local flaps have limited ability to replace the lost dermal tissue. Although local flaps match well with the surrounding skin due to their similar color and structure, a concern with this method is the creation of structural deficits elsewhere in the individual's body (7, 13, 14).

Some advantages of amniotic membrane reconstruction compared to traditional treatment options are as follows:

1. Improved wound healing and regeneration
2. Reduced inflammation and scarring
3. Lower risk of infection
4. Potential for improved functional and aesthetic outcomes (15).

Overall, amniotic membrane reconstruction offers a promising approach for wound healing and tissue regeneration across various medical specialties. As research continues, its applications and effectiveness are likely to expand further.

## Conclusion

The use of amniotic membranes for reconstructing severe forehead skin defects in a two-year-old boy demonstrates a significant advancement in the management of facial trauma injuries in children. Utilizing amniotic membranes in reconstructing soft tissue forehead injuries is considered an exciting advancement in reconstructive medicine. The ability of the amniotic membrane to expedite wound healing, reduce scar formation, and enhance aesthetic outcomes has made it an attractive option

for both patients and surgeons. By harnessing the properties of stem cells within this membrane, surgeons can achieve superior results with reduced risk of complications and improved aesthetic outcomes, thus enhancing results and quality of life. Further research and exploration of innovative methods, such as the use of amniotic membranes, are essential.

## Acknowledgement

The authors express their gratitude to the Department of Oral & Maxillofacial Surgery, Faculty of Dentistry, Zahedan University of Medical Sciences. We extend our sincere appreciation to the respected patients and staff of the operating room of Khatam-al-Anbia Hospital's maxillofacial surgery department.

## Conflict of Interest

There is no conflict of interest to be declared.

## References

1. Kretlow JD, McKnight AJ, Izaddooost SA. Facial soft tissue trauma. *Semin Plast Surg.* 2010;24(4):348-356.
2. Jay RM, Huish JP, Wray JH. Amniotic membrane in clinical medicine: History, current status, and future use. In: Mooradian DL, editor. *Extracellular Matrix-derived Implants in Clinical Medicine*: Woodhead Publishing; 2016.P.151-176.
3. Loeffelbein DJ, Rohleder NH, Eddicks M, Baumann CM, Stoeckelhuber M, Wolff K-D, et al. Evaluation of Human Amniotic Membrane as a Wound Dressing for Split-Thickness Skin-Graft Donor Sites. *Biomed Res Int.* 2014;(1):572183.
4. Kesting MR, Wolff KD, Nobis CP, Rohleder NH. Amniotic membrane in oral and maxillofacial surgery. *Oral and maxillofacial surgery.* 2014;18(2):153-164.
5. Odet S, Louvrier A, Meyer C, Nicolas FJ, Hofman N, Chatelain B, et al. Surgical application of human amniotic membrane and amnion-chorion membrane in the oral cavity and efficacy evaluation: Corollary with ophthalmological and wound healing experiences. *Front Bioeng Biotechnol.* 2021;9:685128.

6. Fitriani N, Wilar G, Narsa AC, Mohammed AFA, Wathoni N. Application of Amniotic Membrane in Skin Regeneration. *Pharmaceutics*. 2023;15(3):748.
7. Schmiedova I, Dembickaja A, Kiselakova L, Nowakova B, Slama P. Using of Amniotic Membrane Derivatives for the Treatment of Chronic Wounds. *Membranes*. 2021;11(12):941.
8. Castellanos G, Bernabé-García Á, Moraleda JM, Nicolás FJ. Amniotic membrane application for the healing of chronic wounds and ulcers. *Placenta*. 2017;59:146-153.
9. Finger PT, Jain P, Mukkamala SK. Super-thick amniotic membrane graft for ocular surface reconstruction. *American Journal of Ophthalmology*. 2019;198:45-53.
10. Zhang Q, Chang C, Qian C, Xiao W, Zhu H, Guo J, et al. Photo-crosslinkable amniotic membrane hydrogel for skin defect healing. *Acta Biomaterialia*. 2021;125:197-207.
11. Song M, Wang W, Ye Q, Bu S, Shen Z, Zhu Y. The repairing of full-thickness skin deficiency and its biological mechanism using decellularized human amniotic membrane as the wound dressing. *Materials Science and Engineering: C*. 2017;77:739-747.
12. Niedzielska I, Obszyński Ł, Bąk M, Niedzielski D. The Role of Full-Thickness Skin Grafts in Patient's Rehabilitation after Maxillectomy and Midface Defects. *Journal of clinical medicine*. 2022;11(13):3608.
13. Redondo P. Simplifying Forehead and Temple Reconstruction: A Narrative Review. *Journal of clinical medicine*. 2023;12(16):5399.
14. Ebrahimi A, Nejadsarvari N. Upper forehead skin reconstruction with h-flap. *J Cutan Aesthet Surg*. 2013;6(3):152-154.
15. Tanaka TS, Demirci H. Cryopreserved ultra-thick human amniotic membrane for conjunctival surface reconstruction after excision of conjunctival tumors. *Cornea*. 2016;35(4):445-450.