



Case Report

Successful management report of COVID-19 with unusual symptoms after heart surgery

Shima Heydari¹ , Ahmad Amouzeschi² 

¹ Assistant Professor of Internal Medicine, Department of Internal Medicine, School of Medicine, Birjand University of Medical Sciences, Birjand, Iran

² Professors of Cardiovascular Surgery, Department of Cardiology, School of Medicine, Cardiovascular Diseases Research Center, Birjand University of Medical Sciences, Birjand, Iran

Corresponding Author:

Tel: +989153318619

Email: shimaheydari@bums.ac.ir

Abstract

COVID-19 is a pandemic and general health urgency with global concern which is rapidly spreading with the new sign. A 72-years-old man with diagnosis of myocardial infarction is transferred to the operating room for the coronary artery bypass surgery. The coronavirus-2019 test and the other diagnostic methods related to it were done and the result was negative. He returned to the hospital with hypotension two months after surgery. At first, the surgeon thought that these symptoms were related to the side effects of the cardiac medicines, so stopped taking and decreased the dose of those medicines. However, the hypotension persisted while the patient complained of anorexia, dizziness, and nausea. Considering the fact that the patient's daughter was a health care worker who suffered from COVID-19, chest High-Resolution CT (HRCT) was conducted showing multi-focal peripheral consolidations in both lungs purposing viral pneumonia. Consequently, the patient was isolated. COVID-19 Polymerase Chain Reaction (PCR) was checked, which turned out to be positive and confirmed the diagnosis. Patients received intensive care in the hospital for six days and were discharged in good general condition to pass the rest of the isolation period at home. It is recommended according to the common symptoms of the coronavirus-2019 disease and the side effects of the cardiac patients' medicines, such as vertigo, nausea, and vomiting, that these symptoms, in the case of these symptoms' occurrence for the patients of coronary artery bypass surgery, can be resulted from the coronavirus-2019 disease, not from the medicine effects.

Keywords: COVID-19, Heart Surgery, Symptoms

Citation: Heydari SH, Amouzeschi A. Successful management report of COVID-19 with unusual symptoms after heart surgery. *J Surg Trauma*. 2022;10(3):125-127.

Received: January 29, 2022

Revised: May 15, 2022

Accepted: May 22, 2022

Introduction

Late in 2019, some pneumonia-related cases were reported in China. In early 2020, the World Health Organization (WHO) named the responsible virus the novel coronavirus (2019-nCoV) and soon announced it as a pandemic and general health urgency with global concern and officially named this disease COVID-19. The disease is rapidly spreading, and about 450.000.000 patients have suffered from this disease resulting in more than 6.000.000 mortality. The most common presentation of this disease includes fever, cough, and dyspnea(1). Also, headache, nausea, vomiting, and shivering are other symptoms of this disease. Though, these symptoms may present with diverse severities based on the underlying disease, age, and cardiovascular

diseases. Our reported case is an old man suffering from diabetes and cardiovascular disease who has undergone CABG and caught the new disease just two months after CABG, though, thanks to early diagnosis and treatment, the patient was discharged to continue his isolation at home.

Case

A 72-year-old man with a two-year history of diabetes mellitus was presented with retrosternal pressuring pain. Laboratory tests revealed a very high troponin level (>40.000). Coronary angiography identified severe three-vessel coronary artery disease, and thus he underwent coronary artery bypass graft(CABG). During surgery Diagonal, Left Anterior Descending (LAD), Obtuse marginal (OM1), (OM2), and (OM3) grafts were performed for the patient. He was discharged six days later in good general condition. ASA (80 mg daily), Plavix (75 mg daily), atorvastatin (40 mg daily), losartan($\frac{1}{2}$ bid), and carvedilol (6.25 mg $\frac{1}{2}$ bid) was prescribed for him. Two months later, the patient

was referred to the hospital with a hypotension presentation(85/70mm Hg). First, the losartan was discontinued, yet hypotension persisted. Three days afterward, carvedilol was also discontinued temporarily, though the hypotension persisted while the patient complained of anorexia, dizziness, and nausea. Considering the fact that the patient's daughter was a health care worker who suffered from COVID-19, chest HRCT was conducted showing multi-focal peripheral consolidations in both lungs purposing viral pneumonia (including COVID-19) Figure(1). Consequently, the patient was isolated. COVID-19 PCR was checked, which turned out to be positive, and also venous Blood Gas (VBG)PO₂ and SO₂ were 18mmhg and under 60percentconfirmed the diagnosis. Patients received intensive care in the hospital for six days and were discharged in good general condition to pass the rest of the isolation period at home. Kaletra and excessive consumption of warm drinks were prescribed. Also, cardiovascular medications such as antiplatelet (Plavix), etc. continued.

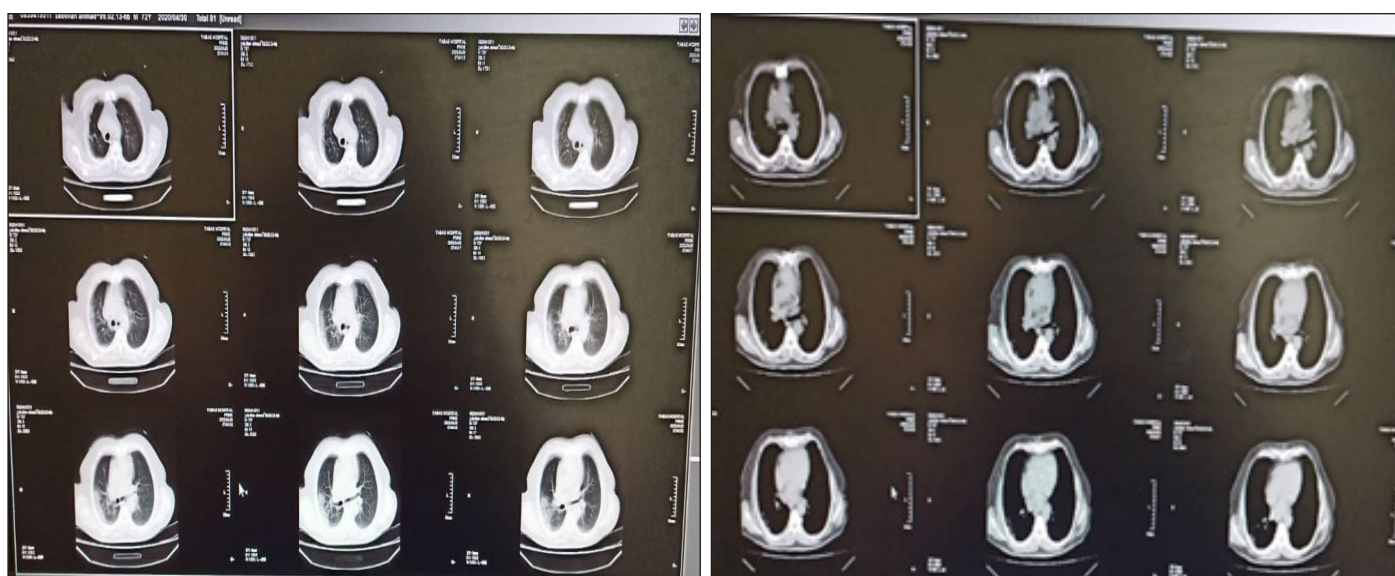


Figure 1. Chest CT shows multifocal peripheral consolidations in both lungs

Discussion

COVID-19 is rapidly spreading all over the world, while no specific treatment has been established, giving priority to disease prevention. Underlying diseases such as cardiovascular diseases and hypertension, as well as the male gender, intensify the disease presentations. Cardiovascular diseases

make these patients more prone to myocardial infarction, finally requiring CABG(2).

We designed a special protocol for patients undergoing CABG in our hospital which most importantly include COVID-19 PCR test for all patients, reducing patients waiting for CABG to less than 24 hours before going to the operation

room, receiving nursing care, and all post-CABG procedures in intensive care units without patient transfer to cardiac wards. Previous studies showed that lack of considering each part of this protocol, such as not taking the COVID-19 PCR-test or the long waiting time of patients before going to the operation room, was associated with patient mortality(3).

Male gender, old age, and underlying disease are the risk factors for this disease, which all were present in our reported case. Losartan and carvedilol are essential for MI treatment(4). However, in this patient because of hypotension, the dose of drugs decreased but hypotension was persistent. On other hand, because the patient's covid 19 test was positive and the patient's symptoms improved with the treatment of this disease, we didn't find other causes for this hypotension. Vascular thrombosis is another complication of this disease, which may lead to acute pulmonary embolism (PE), deep-vein thrombosis, ischemic stroke, myocardial infarction, or systemic arterial embolism (5). This complication was stated as a new complication of COVID-19 in a study with 5 patients less than 50 years(aging 33 to 49) years with cerebral infarction, thus recommending standard doses of thromboprophylaxis for these patients(6). The risk of this complication is relatively low among CABG patients since they routinely receive antiplatelet drugs after CABG.

Conclusion

Given that dizziness, nausea and anorexia are side effects of medications such as losartan and carvedilol in patients underwent coronary artery bypass graft and on the other hand, these symptoms are common in between coronavirus disease patients, all patients who have these symptoms after surgery should be suspected of having the coronavirus disease. Another important point is that

the COVID-19 disease is associated with several complications, it seems that some complications, including vascular thrombosis, are less common among CABG candidates due to routinely taking antiplatelet agents; thus, these patients may undergo surgery considering the related protocols, yet further studies with higher sample sizes are recommended.

Conflict of interest

The author declares there is no conflict of interest.

References

1. Çalıca Utku A, Budak G, Karabay O, Güçlü E, Okan HD, Vatan A. Main symptoms in patients presenting in the COVID-19 period. *Scott Med J*. 2020;65(4):127-132.
2. Jortveit J, Halvorsen S, Kaldal A, Pripp AH, Govatsmark RES, Langørgen J. Unsatisfactory risk factor control and high rate of new cardiovascular events in patients with myocardial infarction and prior coronary artery disease. *BMC Cardiovasc Disord*. 2019;19(1):1-9.
3. Uddin M, Nagarajan K, Nikolaidis N, editors. A case of postoperative Covid-19 infection after cardiac surgery: lessons learned. *The Heart Surgery Forum*; 2020;23(2). doi: 10.1532/hst.3011
4. Tian S, Liu H, Liao M, Wu Y, Yang C, Cai Y, et al., editors. Analysis of Mortality in Patients With COVID-19: Clinical and Laboratory Parameters. *Open Forum Infect Dis*. 2020;7(5):152.
5. Klok F, Kruip M, Van der Meer N, Arbous M, Gommers D, Kant K, et al. Incidence of thrombotic complications in critically ill ICU patients with COVID-19. *Thrombosis research*. 2020;191:145-147.
6. Oxley TJ, Mocco J, Majidi S, Kellner CP, Shoirah H, Singh IP, et al. Large-vessel stroke as a presenting feature of Covid-19 in the young. *N Engl J Med*. 2020;382(20):60. DOI: 10.1056/NEJMc2009787