Journal of Surgery and Trauma 2019; 7(3):103-105.
jsurgery.bums.ac.ir

CASE REPORT

A rare case of branchial cleft cyst

Batool Alsadat Sajadi Nejad[1], Mahmoud Ganjifard[2]

[1] *Assistant Professor, Department of Ear, Nose, and Throat Surgery, Faculty of Medicine, Birjand University of Medical Sciences, Birjand, Iran*

[2] *Assistant Professor, Department of Anesthesiology, Faculty of Medicine, Birjand University of Medical Sciences, Birjand, Iran*

Received: February 08, 2018 ***Revised: February 10, 2019*** ***Accepted: March 12, 2019***

Abstract

Branchial cleft cyst abnormalities account for approximately 20% of the congenital neck and head abnormalities. There are four types of branchial cleft cyst. The incidence rates of types I, II, III, and IV are 8%, 95%, 2%, and 1-4 %, respectively, with just 100 reported cases. Type IV is reported very rarely in previous investigations; however, the patient in this survey suffered from type IV. In addition, one of the differential diagnoses of the thoracic inlet masses can be considered the branchial cyst type IV, which can occur in the fifth decade without any presentation. In spite of the results obtained from previous studies regarding the incidence of this condition on the second to fourth decades of life, this case occurred in the fifth decade of a female's life. Branchial cleft cysts are diagnosed using MRI and CT scans; however, CT scan was utilized in this case report. Surgery is the choice treatment for branchial cleft. Moreover, the incidence rate of the relapse is scarce implying the remaining of a piece of tract's epithelial lining which is more common in the patients who suffered from an infectious lesion.

Key words: Branchial Arch, Branchial Cleft, Branchial Cyst

Introduction

Despite the fact that Branchial cleft cyst is a rare disorder, it is believed to be the second head and neck congenital abnormality in children (1). Hunczovsky described branchial cleft for the first time in 1785 (2). The branchial cleft cyst may originate form the first, second, and third branchial arch remnants; however, most of the time, it grows from the second arch and emerges in the anterior neck triangle, which is located in the one third region top the Sternocleidomastoid muscle (1). The branchial cleft cyst appears unilaterally and progresses slowly. It is thought to be a soft tissue that emerges in the lateral side of the neck (1). Approximately, 60% of these kinds of cysts would appear in the left part of the neck (1). This disease is not associated with gender; however, according to the evidence, it has been reported in females more than males, though, on the contrary, some believe that 60% of this disease would happen in males (1, 3). Based on the anatomical position and size of the mass, symptoms, such as dysplasia, dysphonia, and dyspnea may be demonstrated in this condition (4). The incidence rates of types I, II, III, and IV are 8%, 95%, 2%, and 1-4%, respectively, with just 100 reported cases. Type IV is reported very rarely in previous studies; however, the patient in this survey suffered from branchial cleft cyst type IV (5).

Cases

A 50-year-old female suffering from a mass above the left clavicle for many years presented with slight pain. She mentioned no voice changes or breathing disorders. In addition, she did not report any similar symptoms in her family history. No

@2019Journal of Surgery and Trauma
Tel: +985632381203
Fax: +985632440488
Po Box 97175-379
Email: jsurgery@bums.ac.ir

Correspondence to:
Batool Alsadat Sajadi Nejad, Assistant Professor, Department of Ear, Nose, and Throat Surgery, Faculty of Medicine, Birjand University of Medical Sciences, Birjand, Iran;
Telephone Number: +09158671186
Email Address: setayesh0083@gmail.com

[Downloaded from jsurgery.bums.ac.ir on 2024-04-29]
[DOI: 10.32592/Jsurgery.2019.7.3.105]

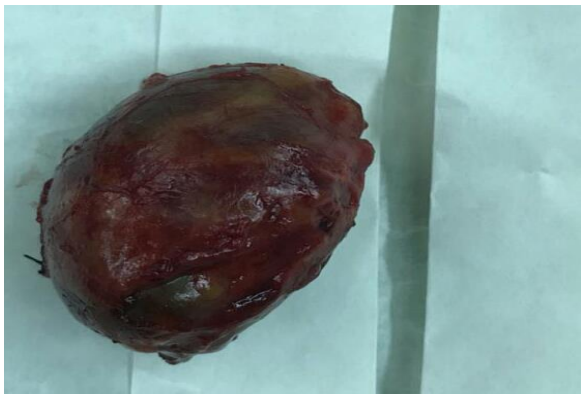

Figure 1: Removed bronchial cleft cyst

abnormalities were detected in nose, pharynx, and larynx examination and there were no specific issues in the neck radiography requiring tracheal tube assessment. Ultrasound imaging and CT scan did not show any signs of cystic mass thyroid and lymph node, and thyroid was normal utterly. Furthermore, a 37×43×54 mm mass was observed in the left anterior of the neck, parallel to the thyroid. The patient was a candidate for surgery and after the induction of general anesthesia, lateral part of the neck was dissected using an incision. The lateral part of the septum cyst, Internal Jugular vein mass, vagus and accessory nerves, carotid arteries, and superior thyroid artery were detected and removed from the deep tissue against the carotid sheath. Samples were inserted into 10% formalin and sent for pathological analysis (Figure 1). Homeostasis was done and drainage was implanted. The pathological analysis revealed branchial cyst features and the patient was under medical supervision for about 1 year and no complications have been observed up to present.

Discussion

Branchial cleft cyst abnormalities account for approximately 20% of congenital head and neck abnormalities (6). Anomalies of branchial arch presumably present as a cyst, cartilaginous sinus, fistula, and remainders with the clinical and radiological patterns and presentations depending on the location of archery involvements. Bilateral cysts account for 2-3% of the cases (6). The incidence rate of this anomaly is not sex-dependent and there is no difference between males and females in this regard (1). Cyst or fistula shows a branchial anomalous in the anterior, bottom, or lateral parts of the neck. The branchial cleft cyst usually presents in the second through fourth decades of life; however, in this case, the patient was 50 years old (7). A fistula usually would open up from the drainage of secretions or purulent structure in anterior sternocleidomastoid muscle in childhood and would be detected in the bottom third of the neck. Nevertheless, the cyst will be often distinguished as a painless and compressed neck mass in the youth and adults which may enlarge due to the infection (7, 8).

Four types of branchial cleft cyst are as follows

Type I is often superficial and located on the anterior surface of the sternocleidomastoid deep into the platysma; however, it is not connected to the carotid sheath. The incidence rate is reported to be 8%.

Type II is the most common type of this anomaly (95%) and placed at the attachment of the anterior branchial cleft cyst and the sternocleidomastoid muscle. Moreover, it is posteriorly near the submandibular gland as well as near and lateral to the carotid sheath.

Type III would spread between the bifurcation of the internal and external carotid arteries to larynx wall and it hardly ever happens.

Type IV occurs deep in the carotid sheath and is located in the larynx mucosal space and would open to the larynx. This type of cyst emerges as a lateral neck mass, abscess, and acute upper thyroiditis; therefore, some authors suggest that the possible existence of branchial arch anomalies should be considered in all thyroiditis cysts (6). The patient, in this case, suffered from type IV branchial cleft.

The MRI and CT scan are among the techniques to distinguish branchial cleft cysts. In this case, the CT scan was employed with contrast (9). Moreover, total resection, which was performed in this case, is the choice to cure the branchial cleft cyst due to the risk of an infectious and life-threatening abscess.

Additionally, in case of infectious cysts, it has been reported to be kept under antibiotic therapy as the first-line treatment followed by surgery after reductions in inflammation (8). Moreover, the incidence rate of the relapse is scarce implying the remaining of a piece of tract's epithelial lining which is more common in the patients who suffered from infectious lesions.

Conclusions

Branchial cleft cyst anomalies account for approximately one-fifth of the congenital neck and head abnormalities. Out of these abnormalities, type IV is rare; however, it can be presented with an abscess or inflammation; therefore, consideration, examination, and clinical explanation can be helpful

[Downloaded from jsurgery.bums.ac.ir on 2024-04-29]

[DOI: 10.32592/Jsurgery.2019.7.3.105]

in this regard. Moreover, one of the differential diagnoses of the thoracic inlet masses can be the branchial cyst type IV, which can occur in the fifth decade without any presentation according to our experience in this case. Nevertheless, previous studies revealed the incidence of this disorder in the second through fourth decades of life. The main treatments for this disease include the whole cyst removal and medical follow-ups after surgery which are essential for early diagnosis of potential relapse.

Conflict of Interest

There is no conflict of interests to be declared.

References

1. Panchbhai AS, Choudhary MS. Branchial cleft cyst at an unusual location: a rare case with a brief review. Dentomaxillofac Radiol. 2012; 41(8):696-702. PMID: 22116133 DOI: 10.1259/dmfr/59515421
2. Boringi M, Bontha SC, Kaur M, Shireen A. Branchial cleft cyst-a case report with review of literature. J Orofacial Sci. 2014; 6(2):125. DOI: 10.4103/0975-8844.143058
3. Vijay Choudhary S, Khadakkar S, Vishwas Harkare V, Rakesh Dhoke P, Sandeep Dhote K, Parvez Kamal N. Type III second branchial cleft cyst. Int J Head Neck Surg. 2012; 3:112-4.
4. Bocchialini G, Bozzola A, Daleffe F, Ferrari L, Castellani A. Unusually rapid development of a lateral neck mass: diagnosis and treatment of a branchial cleft cyst. A case report. Int J Surg Case Rep. 2017; 41:383-6. PMID: 29545997 DOI: 10.1016/j.ijscr.2017.10.065
5. Patel AB, Hinni ML. Case report the fourth branchial complex anomaly: a rare clinical entity. Case Rep Otolaryngol. 2011; 2011:958652. PMID: 22937376 DOI: 10.1155/2011/958652
6. Adams A, Mankad K, Offiah C, Childs L. Branchial cleft anomalies: a pictorial review of embryological development and spectrum of imaging findings. Insights Imaging. 2016; 7(1):69-76. PMID: 26661849 DOI: 10.1007/s13244-015-0454-5
7. Choo MJ, Kim YJ, Jin HR. A case of second branchial cleft cyst with oropharyngeal presentation. J Korean Med Sci. 2002; 17(4):564-5. PMID: 12172058 DOI: 10.3346/jkms.2002.17.4.564
8. Shenoy NS, Tiwari C, Gandhi S, Dwivedi P, Shah H. Anomalies of branchial cleft: our experience and review of literature. Int Surg J. 2017; 4(10):3234-7. DOI: 10.18203/2349-2902.isj20174108

[Downloaded from jsurgery.bums.ac.ir on 2024-04-29]

[DOI: 10.32592/Jsurgery.2019.7.3.105]