

CASE REPORT

Assessment of human cartilage regeneration in a patient with knee osteoarthritis using autologous adipose-tissue-derived stem cells and Platelet-rich plasma: a case study

Mahdieh Ghiasi¹✉, Sahar Farzaneh², Mohammad Bigdelo³

¹Razi Drug Research Center, Iran University of Medical Sciences, Tehran, Iran

²PhD Candidate of Development Biology, Department of Biology, Parand Branch, Islamic Azad University, Parand, Iran

³Department of Surgery, Qom University of Medical Sciences, Qom, Iran

Received: October 16, 2019

Revised: January 07, 2020

Accepted: January 15, 2020

Abstract

Cartilage regenerative pharmaceutical agents have received considerable attention due to their ability to inhibit disease progression in osteoarthritis (OA). The use of adipose-derived stem cells (ADSCs) has been suggested as a reliable method for OA treatment owing to their potential to differentiate into several cell lines and their self-renewal and repair capacity. The present study aimed to assess ADSCs in combination with platelet-rich plasma (PRP) in the treatment of a patient with knee OA.

A 53-year-old man with OA was selected for this treatment. The human abdominal subcutaneous adipose sample was obtained from the patient with knee OA. Stem cells were obtained from adipose tissue of abdominal origin by digesting lipoaspirate tissue with collagenase. ADSCs were cultured in Dulbecco's Modified Eagle Medium (DMEM) supplemented with 10% fasting blood sugar (FBS). Moreover, ADSCs were expanded and characterized by flow cytometry. These stem cells, along with PRP and calcium chloride, were injected into the right knee. Pre-treatment and post-treatment magnetic resonance imaging (MRI) scans, physical therapy, and pain score data were then analyzed.

MRI revealed significant positive changes demonstrating probable cartilage regeneration in the patient. Along with MRI evidence, the measured physical therapy outcomes, subjective pain, and functional status all improved. Therefore, it can be concluded that autologous ADSC injection, in conjunction with PRP, is a promising minimally invasive therapy for osteoarthritis of human knees.

The present clinical case report demonstrated that a combination of percutaneous injection of autologous ADSCs and PRP may be able to regenerate cartilage in human knee OA.

Key words: Pharmacology, Stem cells, Therapeutic use, Tissue engineering

Introduction

Arthritis is a common disease which originates from cartilage damage and affects approximately 250 million people around the world. Older people are commonly more susceptible to this disease, and injuries are the most common causative agents of osteoarthritis (OA) in younger and middle-aged people (1). The use of conventional treatment methods, such as arthroscopic lavage and

debridement techniques can temporarily ease the pain; nonetheless, these methods are incapable of restoring the primary function of cartilage (2). Moreover, there are many challenges in autologous chondrocyte implantation (ACI) for cartilage repair, such as donor site damage and cell limited life span after transplantation. To surmount these problems, some new therapeutic methods, such as regenerative medicine, have been emerged to repair the damaged cartilage tissue (3).

©2020 Journal of Surgery and Trauma

Trauma

Tel: +985632381203

Fax: +985632440488

Po Bax 97175-379

Email: jsurgery@bums.ac.ir

✉ Correspondence to:

Mahdieh Ghiasi, Razi Drug Research Center, Iran University of Medical Sciences, Tehran, Iran;

Telephone Number: +989127512731

Email Address: mahdieh.ghiasi@yahoo.com

Regenerative medicine is defined as an interdisciplinary field aiming to repair damaged tissues and restore their proper function using stem cells and bioactive factors. The success of this interdisciplinary science lies in selecting suitable cells and growth factors (4).

As a suitable cell source, Mesenchymal stem cells (MSCs) have been explored as a new therapeutic approach for cartilage and bone diseases and injuries due to their special abilities to differentiate into various numerous cell categories, as well as high healing ability (5). MSCs have been isolated from numerous human tissues, including bone marrow, adipose, and synovial tissues. In addition, due to the lack of human leukocyte antigen (HLA) class II expression, MSCs can also maintain immunomodulatory activity in vivo leukocyte antigen (6). Pre-clinical studies have confirmed the success and efficacy of using MSCs for cartilage and bone repair in an animal model. Moreover, MSCs-based therapy has been recognized as a promising alternative for cartilage-bone disease, especially OA. Even a limited number of clinical studies have pointed to the efficacy of MSCs for OA treatment. Adipose tissue-derived stem cells (ADSCs) which are generally similar, though not identical, to MSCs have been used in many clinical trials to treat various diseases, such as early-stage OA. Most of these experiments demonstrated positive clinical results; therefore, ADSCs were decided to be tested as a targeted cell source in the present study (7).

Apart from being an appropriate source of cells, growth factors are one of the basic compounds of regenerative medicines. As evidenced by the results of using single growth factors, it is suggested to use a combination of growth factors in regenerative medicine. Platelet-rich plasma (PRP) which is a blood-derived product with diverse growth factors is suggested as a new strategy for the treatment of various diseases, such as OA. PRP therapy is a safe alternative to surgery in mild to moderate cartilage, ligament, and certain muscle injuries. Patients with decreased functionality and chronic pain who may not be candidates for surgery can benefit from PRP since this therapy is more cost-effective and offer a shorter recovery period (8,9).

The current study aimed to evaluate ADSCs in combination with PRP to treat a patient with knee OA.

Cases

A 53-year-old man with knee OA was selected for this practice. He suffered from stage 3 OA, pain,

and inflammation and was incapable of doing his daily activities.

Treatment and experimental protocol

Isolation and passage of adipose-derived Mesenchymal stem cells

The current study was confirmed by the ethics committee of the academic center for education, culture, and research, Qom branch (No. 03-312). Human ADSCs isolation was performed according to previous protocols by Ghiassi et al. (10). In a nutshell, after the obtaining of informed consent, ADSCs were isolated from cutaneous adipose tissue of the patient during abdominal surgery. After washing with sterile phosphate-buffered saline (PBS), adipose tissue was cut into pieces as small as possible (~1 mm³ pieces). Tissue pieces were washed twice with sterile PBS and placed in a solution of 1.5 mg/mL collagenase type I and incubated for 45-60 min at 37°C. Cell suspensions were centrifuged at 1800 rpm for 8 min; thereafter, the pellet was re-suspended in the growth medium. Subsequently, the growth medium was exchanged every other day until the cultures reached 85-90% confluence. Cultures were passaged weekly using 0.25 (wt/vol) trypsin-EDTA solution, and the suspension was centrifuged at 1800 rpm for 10 min. To this end, T75 cm² cell culture plates were used to culture and expand ADSCs up to three passages (11).

Flow Cytometry

Flow cytometry was performed according to the previous study (10). In brief, an anti-human CD73 monoclonal antibody (Abcam, Cambridge, USA), CD90 (Abcam, Cambridge, USA), CD105 (Abcam, Cambridge, USA), and CD34 (Abcam, Cambridge, USA) were used. Following primary antibody labeling, cells were labeled with fluorescent isothiocyanate or phycoerythrin with 1:10,000 dilutions. The analysis was performed with 10,000 cells per sample and the positive expression was defined as the level of fluorescence greater than 99% of the corresponding unstained cell sample (Figure 1).

Microbial analysis of cultured adipose-derived stem cells

The samples were commonly harvested for sterility tests whenever ADSCs were trypsinized upon sub-culture. The tests were carried out in all of the consecutive cultures. At least 10-15 ml of specimens was used for sterility tests, and both supernatant and cells were obtained for microbiological testing after trypsinization. All the obtained solutions were cultured in antimicrobial

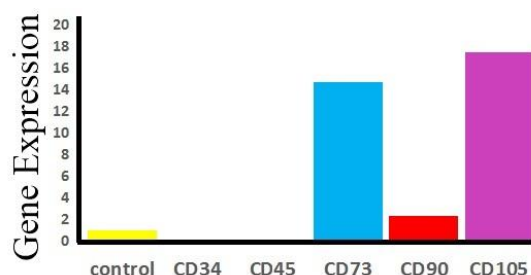


Figure 1: Immunophenotypic and gene expression of human adipose-derived stem cells (HADSCs) at passage 3. Human adipose-derived stem cells surface markers. By flow cytometry, typical human adipose-derived stem cell surface markers are displayed in CD73, CD90, CD105, and CD34 as a negative marker.

free media before sampling for microbiological testing.

The detection of bacterial, fungal, and yeast contamination was carried out using standard culture-based sterility testing in accordance with the pharmacopoeial standards (Pharmaceutical Inspection Co-operation Scheme, 2002; European Pharmacopeia, 2004a, b; US Food and Drugs Administration, 2006). Specimens were cultured on three different media groups which included blood agar (Oxoid Ltd, Hampshire, UK) at 35°C, Eosin methylene blue agar (Oxoid Ltd, Hampshire, UK) at 35°C, and Müller-Hinton agar (BioMe'rieux, Marcy-L'Etoile, France) at 35°C (Figure 2). The fluid media were checked daily to ensure the early detection of contamination and take appropriate measures as soon as the first signs of contamination became apparent. The fluid media were observed daily for the development of turbidity. The turbid cultures were Gram-stained and the broth was subcultured to select agar plates based on the microbial morphology observed in the Gram stain; subsequently, the microorganisms were identified. In the present study, mycoplasma detection was carried using the polymerase chain reaction (PCR). The target gene was 16S rRNA of mycoplasma (11) obtained using the primers [GPO-1 5'-ACTCCTACGGGAGGCAGCATAG and MGS0 5'-TGCACCATCTGTCACTCTGTAAACCTC-3']. The PCR reaction consisted of 5 µl of template DNA, 1 µl of each primer (forward and reverse), 2.5 µl of PCR buffer (10X), 0.75 µl MgCl₂ (50mM concentration), 0.5 µl of dNTP mixture (10mM), 0.4 µl of Taq Enzyme, and 14 µl of double-distilled sterile deionized water. The thermocycler was programmed for 40 cycles at 93°C for 20 s, 60°C for 20 s, and finally 72°C for 30 s. The PCR products were analyzed by agarose gel electrophoresis and visualized by UV-transilluminator after ethidium bromide staining (Figure 2 D) (12).

Preparation of platelet-rich plasma

PRP was prepared from the patient's peripheral

blood in silicone tubes containing sodium citrate 3.8% at a ratio of 9/1, followed by centrifugation at 1800 rpm for 15 min. The number of platelets was determined by a Sysmex counter system. The obtained product is usually divided into three layers: the base, red, contains erythrocytes; the middle, white thin ring, contains leukocytes and inflammatory cytokines; and plasma at the top, platelets and growth factors. The top layer was considered PRP and activated by a 10% solution of CaCl₂ (13).

Injection of adipose tissue-derived stem cells combined with platelet-rich plasma

In the present study, intra-articular injection of 25×10⁶ autologous ADSCs combined with PRP and Calcium chloride was performed following the arthroscopy procedure. The arthroscopic surgery was performed, and medial and lateral articular cartilaginous were explored interiorly, partially excised, and smoothened in a special technique to keep the structure of the cartilage (Figure 2E). This aims at minimally trimming the inferior part of the injured area of the cartilage, maintaining the scaffold and the shape of the meniscus. The intra-articular tube was then applied, incision was sutured, and crepe bandage was applied. The ADSCs solution was then injected via tube, and the tube was then removed. Finally, hinged knee support was applied.

Clinical Outcome

The obtained results pointed to the positive long-term results of ADSCs/PRP injection and its effectiveness in knee OA and had. Our preliminary analysis also demonstrated that stage 4 OA of the knee was improved following ADSCs/PRP injection. Moreover, ADSCs/PRP injection significantly improved Western Ontario and McMaster Universities Osteoarthritis Index (WOMAC) and visual analog scale (VAS) scores during the entire 18-month study period. Magnetic resonance imaging (MRI) showed that the regenerated

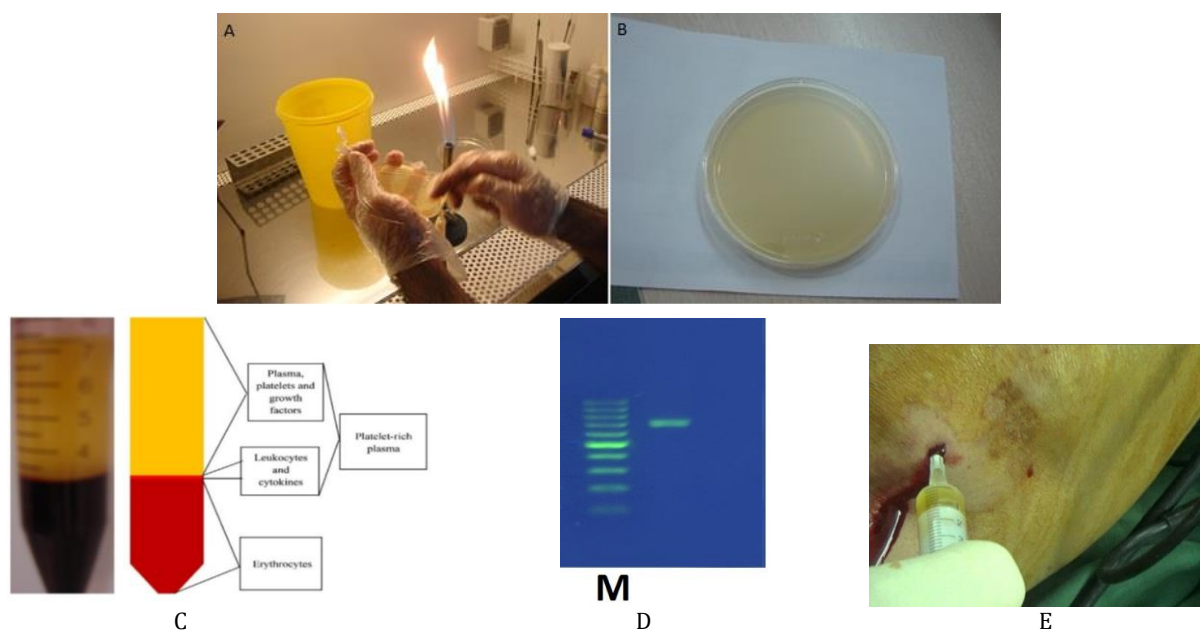


Figure 2: Microbial analysis of cultured adipose-derived stem cells (A). The Polymerase chain reaction (PCR) test using GPO-1 and MGS0 primers (B): cultured adipose-derived stem cells: (sterile water) (Agarose 1.5% and TBE 0.5 × buffer), (C) Schematic illustration of the components of blood and platelet-rich plasma, (D) Column M: DNA ladder 100bp (Fermentas). Lanes 1: positive control (DNA of mycoplasma arginine), (E) Articular injection of platelet-rich plasma into the patient's knee

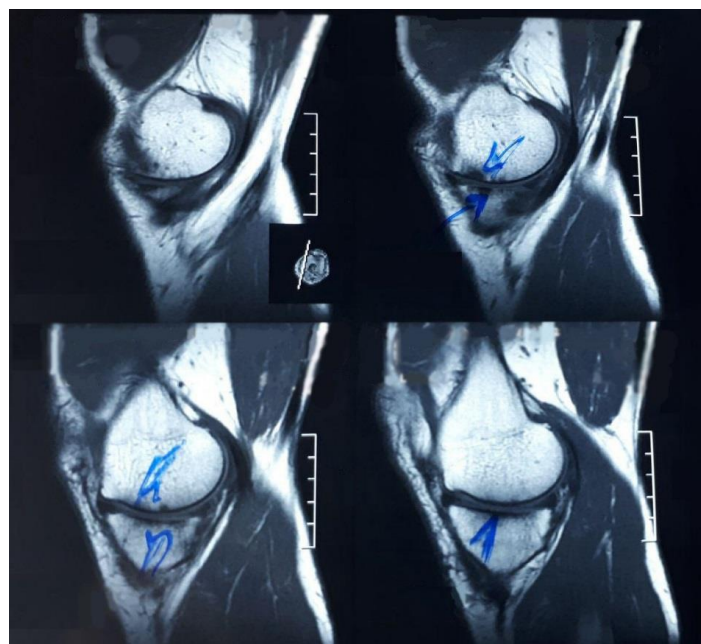


Figure 3: Magnetic resonance imaging (MRI) scanning before (Up) and after (Down) treated with Adipose tissue-derived stem cells /Platelet-rich plasma

cartilage layer of the patient treated with ADSCs/PRP was thicker 18 months after the procedure (Figure 3). Furthermore, no adverse effects were observed in the treated patient. Consequently, it can be concluded that ADSCs/PRP injection may be an effective treatment for

stage 3 OA of the knee (Table1).

Discussion

OA is one of the most common diseases in adult individuals characterized by joint pain and dysfunction due to joint degeneration. The

Table1: Effect of autologous adipose-tissue-derived stem cells and Platelet-rich plasma on human cartilage regeneration in the patient with knee osteoarthritis. Data are presented as mean±SD; P<0.05.

	N	Mean±SD	95% confidence interval		P-value
			Min	Max	
VAS-base (base)	5	7.8±0.83	6.761149	8.838851	0.001
VAS-1 (three months after the injection)	5	5.2±0.83	4.161149	6.238851	
VAS- base (base)	5	7.8±0.83	6.761149	8.838851	
VAS-2 (six months after the injection)	5	3.2±0.83	2.161149	4.238851	0.000
VAS-1 (three months after the injection)	5	5.2±0.83	4.161149	6.238851	
VAS-2 (six months after the injection)	5	3.2±0.83	2.161149	4.238851	
	N	Mean±SD	95% confidence interval		P
			Min	Max	
Womac-base (base)	5	70.8±4.20	65.57615	76.02385	0.0001
Womac -1 (three months after the injection)	5	45.4±4.61	39.66948	51.13052	
Womac- base (base)	5	70.8±4.20	65.57615	76.02385	
Womac -2 (six months after the injection)	5	22.6±2.07	20.02523	25.17477	0.0004
Womac -1(three months after the injection)	5	45.4±4.61	39.66948	51.13052	
Womac -2 (six months after injection)	5	22.6/2.073	20.02523	25.17477	

VAS: Visual analog scale, Womac: Western Ontario and McMaster Universities Osteoarthritis Index

common risk factors for OA include aging, obesity, joint injury, and genetics. (14). Analgesics and Nonsteroidal anti-inflammatory drugs (NSAIDs) are widely used for this painful condition; nonetheless, these techniques carry their own side effects, such as gastrointestinal and cardiovascular diseases. Accordingly, the scientific and mechanical communities suggest using less invasive approaches to prevent OA development and progression. Some researchers have reported the use of intra-articular (IA) injections of MSCs in the knee joint to treat OA (15).

Bansal et al. who used ADSCs and PRP for OA treatment demonstrated that MSCs transplantation resulted in the improvement of pain, joint mobility, and physical disability. In the same vein, Peter et al. indicated a significant improvement in WOMAC and VAS scores, as well as Standard MRI assessment in patients using autologous adipose-derived stromal vascular fraction cells for OA of the knee (16).

The present study assessed autologous MSCs in combination with PRP injection in patients with stage 3 OA of the knee and the obtained results showed an improvement in WOMAC and VAS scores, as well as MRI assessment. Therefore, it is suggested that this method be used for pain reduction in knee OA as a safe and feasible therapy. Furthermore, The combination of autologous MSCs and PRP can be used as an alternative to corticosteroid injections and physiotherapy.

Conclusions

Therefore, the current study presented the most effective methods for the repair of

osteochondral lesions of the knee in terms of strength and cellular survival.

Acknowledgments

The authors' deepest appreciation goes to the staff of Avaye mahd cell Iranian company for their patience and encouragement in different stages of the current research project.

Conflict of Interest

The authors declare that they have no conflict of interest regarding the publication of the current article.

References

1. Litwic A, Edwards MH, Dennison EM, Cooper C. Epidemiology and burden of osteoarthritis. *Br Med Bull.* 2013; 105:185-99. [PMID: 23337796](#) [DOI: 10.1093/bmb/lds038](#)
2. Felson DT. Arthroscopy as a treatment for knee osteoarthritis. *Best Pract Res Clin Rheumatol.* 2010; 24(1) 47-50. [PMID: 20129199](#) [DOI: 10.1016/j.berh.2009.08.002](#)
3. Krajewska-Włodarczyk M, Owczarczyk-Saczonek A, Placek W, Osowski A, Wojtkiewicz J. Articular cartilage aging-potential regenerative capacities of cell manipulation and stem cell therapy. *Int J Mol Sci.* 2018; 19(2):E623. [PMID: 29470431](#) [DOI: 10.3390/ijms19020623](#)
4. Christ GJ, Saul JM, Furth ME, Andersson KE. The pharmacology of regenerative medicine. *Nader Pharmacol Rev.* 2013; 65(3):1091-133. [PMID: 23818131](#) [DOI: 10.1124/pr.112.007393](#)
5. Bharti D, Shivakumar SB, Subbarao RB, Rho GJ.

- Research advancements in porcine derived mesenchymal stem cells. *Curr Stem Cell Res Ther.* 2016; 11(1):78-93. [PMID: 26201864](#) [DOI: 10.2174/1574888x10666150723145911](#)
6. Gao F, Chiu SM, Motan DA, Zhang Z, Chen L, Ji HL, et al. Mesenchymal stem cells and immunomodulation: current status and future prospects. *Cell Death Dis.* 2016; 7:e2062. [PMID: 26794657](#) [DOI: 10.1038/cddis.2015.327](#)
 7. Paschos NK, Sennett ML. Update on mesenchymal stem cell therapies for cartilage disorders. *World J Orthop.* 2017; 8(12):853-60. [PMID: 29312843](#) [DOI: 10.5312/wjo.v8.i12.853](#)
 8. Qian Y, Han Q, Chen W, Song J, Zhao X, Ouyang Y, et al. Platelet-rich plasma derived growth factors contribute to stem cell differentiation in musculoskeletal regeneration. *Front Chem.* 2017; 5:89. [PMID: 29164105](#) [DOI: 10.3389/fchem.2017.00089](#)
 9. Masoudi E, Ribas J, Kaushik G, Leijten J, Khademhosseini A. Platelet-rich blood derivatives for stem cell-based tissue engineering and regeneration. *Curr Stem Cell Rep.* 2016; 2(1):33-42. [PMID: 27047733](#) [DOI: 10.1007/s40778-016-0034-8](#)
 10. Sheykhasan M, Qomi RT, Kalhor N, Mehdizadeh M, Ghiasi M. Evaluation of the ability of natural and synthetic scaffolds in providing an appropriate environment for growth and chondrogenic differentiation of adipose-derived mesenchymal stem cells. *Indian J Orthop.* 2015; 49(5):561-8. [PMID: 26538764](#) [DOI: 10.4103/0019-5413.164043](#)
 11. West CC, Murray IR, González ZN, Hindle P, Hay DC, Stewart KJ, et al. Ethical, legal and practical issues of establishing an adipose stem cell bank for research. *J Plast Reconstr Aesthet Surg.* 2014; 67(6):745-51. [PMID: 24529696](#) [DOI: 10.1016/j.bjps.2014.01.030](#)
 12. Cobo F, Cortés JL, Cabrera C, Nieto A, Concha A. Microbiological contamination in stem cell cultures. *Cell Biol Int.* 2007; 31(9):991-5. [PMID: 17452110](#) [DOI: 10.1016/j.cellbi.2007.03.010](#)
 13. do Amaral RJ, da Silva NP, Haddad NF, Lopes LS, Ferreira FD, Filho RB, et al. Platelet-rich plasma obtained with different anticoagulants and their effect on platelet numbers and mesenchymal stromal cells behavior in vitro. *Stem Cells Int.* 2016; 2016:7414036. [PMID: 27340410](#) [DOI: 10.1155/2016/7414036](#)
 14. Loeser RF, Goldring SR, Scanzello CR, Goldring MB. Osteoarthritis: a disease of the joint as an organ. *Arthritis Rheum.* 2012; 64(6):1697-707. [PMID: 22392533](#) [DOI: 10.1002/art.34453](#)
 15. Kong L, Zheng LZ, Qin L, Ho KK. Role of mesenchymal stem cells in osteoarthritis treatment. *J Orthop Translat.* 2017; 9:89-103. [PMID: 29662803](#) [DOI: 10.1016/j.jot.2017.03.006](#)
 16. Fodor PB, Paulseth SG. Adipose derived stromal cell (ADSC) injections for pain management of osteoarthritis in the human knee joint. *Aesthet Surg J.* 2016; 36(2):229-36. [PMID: 26238455](#) [DOI: 10.1093/asj/sjv135](#)