

CASE REPORT

Surgical excision of a large gingival pyogenic granuloma using diode laser: A case report

Soheila Darmiani¹ 

¹Assistant Professor of Endodontic, School of Dentistry, Birjand University of Medical Sciences, Birjand, Iran

Received: April 06, 2020

Revised: May 18, 2020

Accepted: June 20, 2020

Abstract

Pyogenic granuloma (PG) is a common tumor-like growth observed in response to local irritation, trauma, or hormonal disturbances. It is among the frequently encountered oral lesions occurring at the gingiva. Surgical excision and removal of the underlying cause is the preferred method of treatment. Scalpel, cryosurgery, and laser are used in order to remove this lesion. Currently, different lasers are used for the surgery of PG, which include Carbon dioxide; Neodymium-doped yttrium aluminum garnet; Diode; Erbium-doped yttrium aluminum garnet; and Erbium, chromium-doped yttrium, scandium, gallium and garnet. This case report aims to briefly review clinical and radiographic findings of PG along with a detailed discussion on its management through a 980-nm diode laser.

Key words: Diode lasers, Excisional surgery, Pyogenic granuloma

Introduction

Pyogenic granuloma (PG) is the benign, soft, usually solitary, and non-neoplastic vascular proliferation of the skin and oral cavity. It has been pertaining by a diversity of other names, such as granuloma pediculatum benignum, pregnancy tumor, vascular epulis, and Crocker and Hartzell's disease. The term "PG" or "granuloma pyogenicum" was stated by Hartzell in 1904. This non-neoplastic reactive lesion is commonly occurring in the oral cavity as a response to trauma, chronic local irritation, and hormonal disturbances (1). The term pregnancy tumor is also used when it occurs in pregnant women. Clinically, the PG presents as a pedunculated or sessile growth with a smooth or lobulated surface. The lesion may vary from red to pink in color depending upon the maturity of the lesion, and the surface may be ulcerated. The most common intra-oral site of the occurrence is the gingiva, especially the maxillary anterior region.

Extra-gingivally, the lesion may be found on the lower lip, tongue, palate, and buccal mucosa. The

PG of the upper lip is a rare occurrence (2, 3). Surgical excision is the treatment of choice (4). After surgical excision of gingival lesions, it is recommended to curettage the underlying tissue (5) and perform an excision with 2 mm margins at its clinical periphery and a full thickness up to the periosteum or to the causative agent. Any foreign body, calculus, or defective restoration should be removed as part of the excision (6).

Laser technology is being widely used in dentistry. Moreover, its ability to perform precise incisions, better hemostasis, and less invasive procedures with less discomfort to patients have made it a preferred treatment option for several soft tissue lesions (7). The advantages of laser surgery, compared to conventional surgical methods, include the maintenance of sterile conditions, a good estimation of cutting depth, reduction in the number of operative instruments, often no need for suturing or bandages, pain reduction both intra- and postoperatively, promotion of wound healing, as well as fewer scars, staff, and less amount of time. A number of

©2020 Journal of Surgery and
Trauma

Tel: +985632381203

Fax: +985632440488

Po Bax 97175-379

Email: jsurgery@bums.ac.ir

✉ Correspondence to:

Soheila Darmiani, Assistant Professor of Endodontics, School of Dentistry, Birjand University of Medical Sciences, Birjand, Iran;

Telephone Number: +989370554413

Email Address: soheiladarmiani@yahoo.com

lasers have been successfully used to treat PG, such as Neodymium-doped yttrium aluminum garnet, Carbon dioxide laser, Erbium-doped yttrium aluminum garnet (Er:YAG), and the Diode laser (8). This case report presents a successful application of diode laser in the context of a large PG.

Cases

A 42-year-old addicted male with no medical history presented with a painless gingival growth that appeared 9 months ago. Intraoral examination revealed a solid and lobulated mass with a diameter of approximately 2×1.5 cm in the marginal, buccal, and palatal gingiva of the anterior maxillary region. It was pink in color and bled spontaneously (Figure 1). A digital panoramic radiograph revealed no osseous involvement (Figure 2). Due to the excessive bleeding tendency observed during clinical examination, a 980-nm diode laser was chosen as a minimally invasive procedure to excise the lesion. After local

anesthesia, the lesion was excised with a 980-nm diode laser using an initiated 600µm diameter fiber optic tip in contact and continuous mode with 1 W setting. It was ensured that the lesion was completely excised by trimming up the remnants of the soft tissue adjacent to the tooth to prevent the recurrence of the lesion. (Figure 3 a, b).

Histological examination with hematoxylin and eosin staining revealed high vascular proliferation and inflammatory granulomatous tissue with infiltration of lymphocytes, plasma cells, and neutrophils along with the areas of fibrous connective tissue. The lesion was covered by ulcerated stratified squamous epithelium without atypia (Figure 4). These features confirmed the diagnosis of PG (7). After the total excision of the lesion, the patient denied scaling, root planing, and restoration of his dental caries. Due to the recovery, the patient did not seek follow-up. Informed consent was obtained from the above-described patient regarding the use of any clinical, radiographical, and other diagnostic data or photographs for academic or publication purposes.

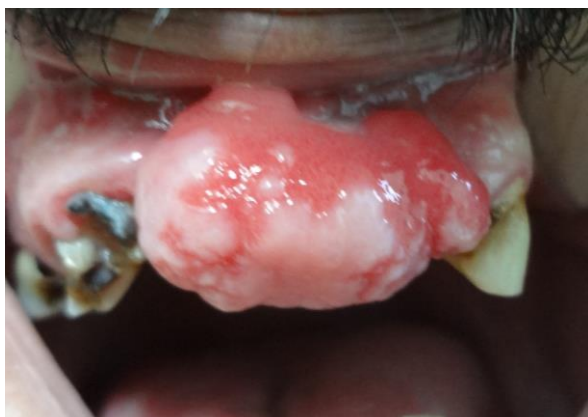

Figure 1: Clinical picture of the lesion between the teeth 13 and 23

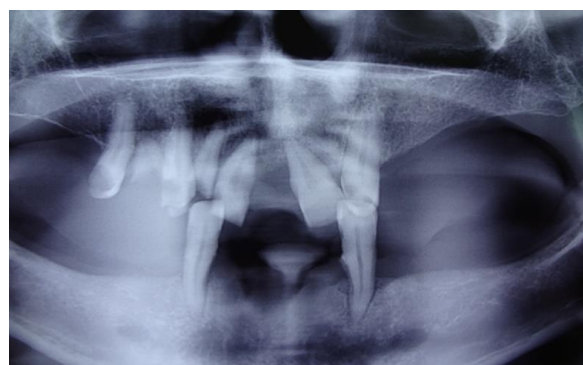
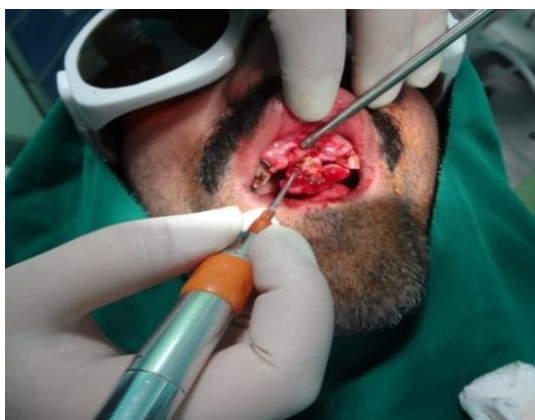
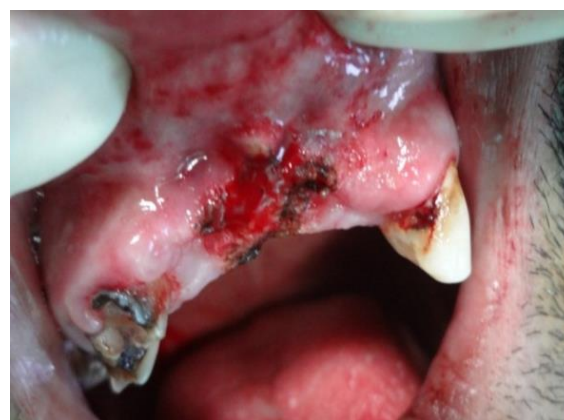Figure 2: Panoramic radiograph showing no osseous involvement



a



b

Figure 3: a) View of surgery using diode laser
b) After total excision of the lesion with a 980-nm diode laser

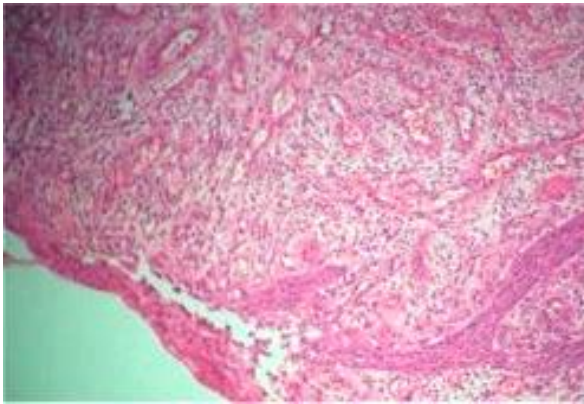


Figure 4: Histologic section of the growth

Discussion

Oral PG is a common reactive lesion. Females are more frequently affected than males, especially in their second decade due to the increased levels of circulating hormones. Oral PGs have a strong predilection for the gingiva with up to 70% of all cases occurring in this site alone. In the present case, the lesion appeared on the marginal, buccal, and palatal gingiva of the maxillary anterior region. Clinically, the PG is a smooth or lobulated exophytic lesion with small and erythematous papules on a pedunculated or sessile base. It bleeds easily and grows rapidly; moreover, its size rarely exceeds 2.5 cm and is generally asymptomatic and painless (2). The surface is often covered by the yellow fibrinous membrane and is ulcerated and friable due to masticatory trauma. Depending on the age of the lesion, the color of the surface ranges from pink to red or purple (3). Young PGs have higher vascularity and hyperplastic granulation tissue, whereas older PGs have more collagen. Microbial agents, such as streptococci and staphylococci, may play a role in the etiopathogenesis of this lesion as they infect minor trauma sites during the healing process; furthermore, vascular overproduction and tumor-like hyperplasia appear as a response. In the present case, poor oral hygiene (dental calculus) and different severe caries were the major predisposing factors. Differential diagnosis mainly includes vascular tumors, including haemangioma, oral fibroma, peripheral giant cell granuloma, peripheral ossifying fibroma, or neoplastic lesions, such as Kaposi sarcoma, metastatic carcinoma, and other malignant tumors. Drug-induced gingival enlargement is sometimes noticed in Nifedipine users. This is a pale pink and generalized fibrotic event involving a large portion of the upper and lower gingiva with a pebbly surface.

The diode laser is manufactured from solid

semi-conductor crystals by aluminum (800 nm) or indium (900 nm), gallium, and arsenic. The coherent laser beam at these particular wavelengths penetrates deep into the mucosa and is highly attenuated by the pigmented tissue, and at the same time is poorly absorbed by the dental hard tissues. Therefore, surgery can be safely performed in this regard. These lasers can also stimulate fibroblastic proliferation at low energy (7, 8).

Akbulut et al. stated that diode lasers are useful for oral soft tissue surgical procedures since their specific wavelength (810-980 nm) is absorbed by water and also other chromophores, such as melanin and oxyhemoglobin (9). Similarly, Asnaashari et al. after reporting the removal of a pediatric PG using a diode laser, concluded that lasers would minimize discomfort both during and after surgery (10). Accordingly, the laser can be considered a first choice despite periodontal surgery due to fast reaction, a little bleeding, and better repair (9, 10).

In a study conducted by Kocaman et al., neodymium-doped yttrium aluminum garnet (power output 4W, energy 100 mJ, frequency 40 Hz, pulsed emission mode) was used in order to eliminate the PG. They also concluded that the use of laser in the treatment of PG reduced bleeding during surgery with a consequent reduction in operating time, promoted rapid postoperative hemostasis, and better patient acceptance (11).

In the same vein, Aras et al. has evaluated the patients regarding pain severity during the first three hours after surgery. The results revealed that those in the Er:YAG laser group had a higher degree of pain, compared to those in the diode laser group (12). Karahas suggests that laser frenectomy provides a better patient perception of success than that observed when using conventional surgery. However, in our study, we have not encountered any reports of pain from the patient (13).

In the current study, diode laser was selected as the treatment of choice because of the excessive size of the lesion (~2×1.5cm), which is significantly larger than many laser-operated PG cases in the literature.

Conclusions

Excisional surgery is the preferred treatment method for oral PG. The application of laser can be considered an effective and safe treatment option for the excision of this lesion with minimal invasion and different clinical advantages, such as reduced

pain and time of wound healing, as well as less bleeding.

Conflict of Interest

The author has no conflict of interest to declare.

References

- Dal Prá KJ, Bernabé DG, Miyahara GI, Biasoli ER, Crivelini MM, Tjioe KC. Extra-gingival pyogenic granuloma displacing teeth. *J Craniofac Surg*. 2017; 28(2):e185-6. [PMID: 27755424](#) [DOI: 10.1097/SCS.0000000000003122](#)
- Jafarzadeh H, Sanatkhan M, Mohtasham N. Oral pyogenic granuloma: a review. *J Oral Sci*. 2006; 48(4):167-75. [PMID: 17220613](#) [DOI: 10.2334/josnusd.48.167](#)
- Banjar A, Abdrabuh A, Al-Habshi M, Parambil M, Bastos P, Abed H. Labial pyogenic granuloma related to trauma: a case report and mini-review. *Dent Traumatol*. 2019; 36(4):446-51. [PMID: 31869498](#) [DOI: 10.1111/edt.12537](#)
- Robinson HB, Miller AS. *Color atlas of oral pathology*. Philadelphia: Lippincott; 2000. P. 163.
- Patil K, Mahima VG, Lahari K. Extralingival pyogenic granuloma. *Indian J Dent Res*. 2006; 17(4):199-202. [PMID: 17217217](#) [DOI: 10.4103/0970-9290.29864](#)
- Kamal R, Dahiya P, Puri A. Oral pyogenic granuloma: various concepts of etiopathogenesis. *J Oral Maxillofac Pathol*. 2012; 16(1):79-82. [PMID: 22434943](#) [DOI: 10.4103/0973-029X.92978](#)
- Bansal V, Konidena A, Mann AK, Farooq F. Diode laser excision of pyogenic granuloma: a case report. *J Dent Lasers*. 2019; 13(2):52-5. [DOI: 10.4103/jdljdl.8.19](#)
- Andreadis D, Lazaridi I, Anagnostou E, Pouloupoulos A, Panta P, Patil S. Diode laser assisted excision of a gingival pyogenic granuloma: a case report. *Clin Pract*. 2019; 9(3):1179. [PMID: 31579498](#) [DOI: 10.4081/cp.2019.1179](#)
- Akbulut N, Kursun ES, Tumer MK, Kamburoglu K, Gulsen U. Is the 810-nm diode laser the best choice in oral soft tissue therapy? *Eur J Dent*. 2013; 7(2):207-11. [PMID: 24883028](#) [DOI: 10.4103/1305-7456.110174](#)
- Asnaashari M, Zadsirjan S. Application of laser in oral surgery. *J Lasers Med Sci*. 2014; 5(3):97-107. [PMID: 25653807](#)
- Kocaman G, Belduz N, Erdogan C, Ozbek E, Sadik E, Kara C. The use of surgical Nd:YAG laser in an oral pyogenic granuloma: a case report. *J Cosmet Laser Ther*. 2014; 16(4):197-200. [PMID: 24689434](#) [DOI: 10.3109/14764172.2014.910078](#)
- Aras MH, Göregen M, Güngörmüş M, Akgül HM. Comparison of diode laser and Er:YAG lasers in the treatment of ankyloglossia. *Photomed Laser Surg*. 2010; 28(2):173-7. [PMID: 19743963](#) [DOI: 10.1089/pho.2009.2498](#)
- Kara C. Evaluation of patient perceptions of frenectomy: a comparison of Nd:YAG laser and conventional techniques. *Photomed Laser Surg*. 2008; 26(2):147-52. [PMID: 18341414](#) [DOI: 10.1089/pho.2007.2153](#)