

ORIGINAL  
ARTICLE

## Long-term cinnamon consumption improves postoperative recovery of liver resection surgery in aged rats

Mohammad Dastjerdi<sup>1</sup>, Samaneh Nakhaee<sup>2</sup> , Masoumeh Asakri<sup>1</sup>, Fereshteh Bayat<sup>1</sup>,Khadijeh Farrokhfall<sup>3</sup> <sup>1</sup>Student Research Committee, Birjand University of Medical Sciences, Birjand, Iran<sup>2</sup>Medical Toxicology and Drug Abuse Research Center, Birjand University of Medical Sciences, Birjand, Iran<sup>3</sup>Cardiovascular Research Center, Birjand University of Medical Sciences, Birjand, Iran

Received: April 07, 2020

Revised: May 03, 2020

Accepted: May 11, 2020

## Abstract

**Introduction:** Aging is associated with organ function failure and affects medical/surgical treatments. Free radicals are considered among the most common causes of senescence. Liver damage frequently occurs as a result of aging. Cinnamon (*Cinnamomum zeylanicum*) is one of the well-known spices in the world with antioxidant and hepatoprotective effects. The aim of this study was to evaluate the effect of cinnamon consumption on recovery from partial hepatectomy.

**Methods:** This experimental study was conducted on 32 male Sprague-Dawley rats (12 weeks old) randomly divided into two equal groups of experimental and control. The experimental group received a diet with cinnamon (1% by weight) for 45 weeks, while the control group had a normal diet. Both groups were subjected to partial hepatectomy (30% of the total liver weight) after 45 weeks. Blood collection and weighting were performed prior to hepatectomy, as well as 2, 10, and 28 days after the operation. The concentrations of nitric oxide metabolites (NOx), malondialdehyde (MDA), insulin, and glucose were assayed in the serum. Kruskal Wallis and Mann-Whitney tests were used to compare the mean values between the experimental groups. All analyses were performed in GraphPad Prism software (version 5) at a significance level of < 0.05.

**Results:** The results showed that cinnamon consumption prevented postoperative weight loss. Furthermore, cinnamon significantly lowered serum MDA concentration 48 h after hepatectomy. It also significantly decreased weight loss due to partial hepatectomy on the 2<sup>nd</sup> day of the surgery. Furthermore, there was a significant increase in serum NOx level following cinnamon consumption on the 2<sup>nd</sup> and 28<sup>th</sup> days of the surgery. However, cinnamon had no effect on serum glucose and insulin concentrations.

**Conclusions:** As the findings indicated, cinnamon improved postoperative outcomes after hepatic resection in rats by attenuating oxidative stress and nitric oxide content. Therefore, this spice might be considered a useful dietary recommendation for elderly patients with hepatic resection.

**Key words:** Aging, *Cinnamomum zeylanicum*, Hepatectomy, Postoperative complications

## Introduction

Aging is triggered by adverse systemic reactions that take place as a result of the elevation of inflammatory markers (e.g., cytokines, chemokine,

and reactive oxygen species [ROS]), as well as the decline of antioxidant enzyme levels (1). The liver is known for its complex physiology and rapid regenerative potential. This organ has a wide range of activities, including detoxification, protein

©2020 Journal of Surgery and Trauma

Tel: +985632381203

Fax: +985632440488

Po Bax 97175-379

Email: jsurgery@bums.ac.ir

✉ Correspondence to:

Khadijeh Farrokhfall, Cardiovascular Research Center, Birjand University of Medical Sciences, Birjand, Iran;

Telephone Number: +989155610021

Email Address: kfarrokhfall@yahoo.com

synthesis, and production of compounds, which are required for the digestion process. Age-related changes in hepatic structure may significantly affect liver morphology, as well as its physiology and oxidative capacity (2).

Oxidative stress plays a negative role in all forms of major surgeries by deteriorating the surgical outcomes and recovery (3). Regarding this, the control of oxidative stress is a vital measure for convenient recovery following the implementation of major surgical procedures (4), including liver resection (5). Various therapeutic strategies with different degrees of efficiency have been utilized for reducing oxidative stress in surgery (6). An important technical part during liver resection is vascular inflow occlusion, which can be accomplished by the placement of a tourniquet around the portal vein or hepatic artery branches. This measure reduces blood loss, which reportedly increases postoperative morbidity and mortality as a result of the activation of oxidative stress signaling pathways (7). Furthermore, in this condition, large quantities of nitric oxide (NO) are generated due to the activation of inducible nitric oxide synthase (iNOS), which, in turn, facilitates the achievement of better outcomes. However, this may sometimes worsen the condition (8).

Cinnamon (*Cinnamomum zeylanicum*) is an herb that has been used for medical purposes for a long time. The dried skin powder of this herb is used as a spice and flavoring agent in various foods, pastries, and cakes (9). Cinnamon is a rich source of cinnamic acid, cinnamaldehyde, cinnamyl alcohol, linalool, safrole, lebmone, tannin, coumarin, flandrenone, mannitol, and a variety of flavonoids, including chalcone (10). In a clinical trial, Askari et al. revealed that cinnamon can significantly contribute to the reduction of fasting blood sugar, total cholesterol, triglycerides, alanine aminotransferase, aspartate aminotransferase, gamma glutamine transpeptidase, and C-reactive protein (11).

The results of a similar study showed that cinnamon bark extract powder can improve blood glucose and insulin indices via increasing the rate of glucose uptake by various body cells and lowering the oxidative stress levels (12). Flavonoids present in cinnamon have been revealed to be responsible for the antioxidant properties of this herb (13). Flavonoids are claimed to have protective effects against free radicals, inducing the lipid peroxidation of living cell membranes (14). Based on the evidence, both surgery and aging are associated with impaired oxidative balance. Regarding this, the present study was conducted to investigate the effect of

cinnamon, as a hepatoprotective agent improving oxidative/nitrosative stress, on recovery from liver resection surgery in old Sprague-Dawley rats.

## Methods

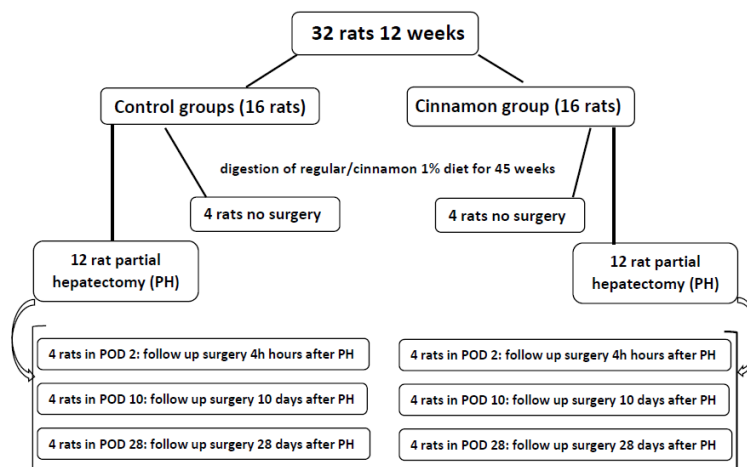
### 2-1. Animals and diet

For the purpose of the study, 32 male Sprague-Dawley rats aged 12 weeks were purchased from the Research Center of Experimental Medicine, Birjand University of Medical Sciences (BUMS), Birjand, Iran. The animals were kept in appropriate laboratory conditions with 12:12 h light:dark cycle at 24°C, with free access to water and food. The experiment was performed according to the standard ethical guidelines for animal experimentation. Furthermore, the study was approved by the Institutional Ethics Committee of BUMS (No. IR-BUMS.REC:1397.195).

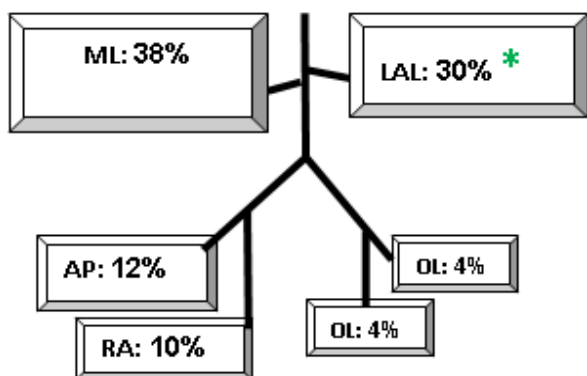
The rats were randomly divided into two equal groups of control and cinnamon. The animals in the control group were subjected to a standard laboratory animal diet (Javaneh Khorasan, Iran). On the other hand, the experimental rats were treated with a cinnamon-enriched diet 1% (w/w) for 45 weeks. Cinnamon (1% by weight w/w) was added to the rat food that was purchased from the Javaneh Khorasan Company, Mashhad, Iran. The cinnamon concentration was determined with respect to the maximum allowable dose of cinnamon in human (15) and the maximum cinnamon dose measured for rats (16). In case of animal death, the same rat was replaced.

Four rats from each group were subjected to blood collection, while the remaining 12 cases were subjected to the left hepatic lobe dissection (30% of the liver weight was removed) at 57 weeks old. The rats were also weighed before liver resection, as well as after this procedure at three time points, namely the 2<sup>nd</sup>, 10<sup>th</sup>, and 28<sup>th</sup> days of the surgery. The design of the study is illustrated in Figure 1.

Liver resection was carried out in accordance with Higgins methodology for hepatectomy with some modifications (17). In order to perform this procedure, the rats were anesthetized with pentobarbital (60 mg/kg). The surgery was carried out at 9-12 a.m. under aseptic conditions. During the liver resection, the rats were subjected to transverse abdominal incision in a supine position to facilitate access to the liver. The base of the left anterior hepatic lobe (Figure 2) was first ligated and then dissected (30% of the liver was removed). Subsequently, the hepatic tissue was dissected from the areas between the coronary ligaments, as well as the middle, left lobe and gastrohepatic



**Figure 1: Flowchart of study design**  
PH: partial hepatectomy, POD: postoperative day



**Figure 2: Anatomy of the liver in rats**  
ML: middle lobe, LAL: left anterior lobe, RA: right anterior lobe, RP: right posterior lobe, OL: omental lobe

parts, which remained intact.

Liver resection was carried out with great care to avoid any damage to the liver tissue. Once the base of the left anterior lobe was shut off by a ligature, the liver was restored to its presurgical anatomic position to avoid the suction of blood from the portal vein. When the ligature was knitted, and the resection was accomplished, the remaining parts of the hepatic parenchyma was carefully checked for clear blood and lack of congestion to make sure that the ligature did not stand too low and would not cause any partial obstruction in one of the main hepatic veins or even in the inferior vena cava. The abdomen incision was closed using a two-layer closure with stitches of 0.4 nylon sutures.

After the surgery, the rats were orally fed with ibuprofen (30 mg/kg) using a gavage (18) and then transferred to a transparent box. They were kept under a heating lamp until complete recovery from anesthesia. During this period, the animals were

cared for by the direct observation of the researcher. In the next step, four hepatectomized rats in each group were selected on the 2<sup>nd</sup>, 10<sup>th</sup>, and 28<sup>th</sup> days postoperation. Their blood samples were collected from the heart under anesthesia with sodium pentobarbital (60 mg/kg). The blood samples were then centrifuged at 5,000 rpm for 10 min at 4°C to obtain serum. The collected sera were stored at -20°C for further assessment.

## 2-2. Serum biochemical measurement

### 2-2-1. Serum nitrate/nitrite measurement

Serum concentrations of NO<sub>x</sub> were measured by the Griess reaction as previously described (19). In brief, serum samples were deproteinized by zinc sulfate (15 mg/mL) and centrifuged at 10,000 g for 10 min. The NO<sub>x</sub> concentration was established based on the standard curve (constructed 0-80 μmol sodium nitrate).

### 2-2-2. Measurement of serum malondialdehyde

The levels of thiobarbituric acid (TBA)-reactive substances as the byproduct of lipid peroxidation were determined in the collected sera based on reaction with TBA. The samples were incubated with TBA and phosphoric acid for 30 min at 90-100°C. After the addition of methanol, the mixture was vigorously shaken. The absorbance of the resultant pink product was measured spectrophotometrically at 535 nm (20).

### 2-2-3. Other biochemical assays

The measurement of the insulin level was accomplished using the ELIZA kit (Insulin; Mercodia, Sweden). In addition, the serum glucose level was assayed by the glucose oxidase method (Pars Azemun Co., Iran).

### 2-3. Statistical analysis

Nonparametric Kruskal-Wallis and Mann-Whitney U tests were used to compare the mean values between the experimental groups. In all the tests, a p-value less than 0.05 was considered statistically significant. All analyses were performed in GraphPad Prism software (version 5).

## Results

Throughout the study, all animals remained alive without any fatality. Initial body weight was comparable among the investigated animals (220±15 g).

### 3-1. Restoration of postoperative weight loss after cinnamon consumption

The liver resection was performed under an aseptic condition. The intra- and inter-group comparison of the postoperative body weight with the preoperative value in each time point (i.e., 2, 10, and 28 days after the surgery) was indicative of a change in body weight following the surgery. In this regard, the body weight was decreased in the control and experimental groups on the 2<sup>nd</sup> day of the operation. However, this reduction was more significant in the experimental group, compared to that in the control group. For instance, the rate of weight loss in the control group was estimated at 10% in comparison to 5% in the experimental group 2 days after liver resection (Figure 3).

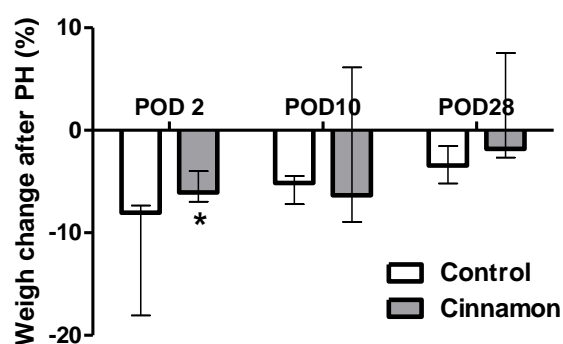
### 3-2. Attenuation of systemic oxidative stress as a result of plasma malondialdehyde decrement induced by cinnamon

The serum malondialdehyde (MDA; as a peroxidation index) was measured in the experimental group. Based on the results, the consumption of cinnamon for 45 weeks led to the

improvement of the oxidative condition. In addition, liver resection raised oxidative stress in the control group, compared to that in the experimental group. In addition, the cinnamon-treated rats exhibited a significant decrease in the MDA level on the 2<sup>nd</sup> day of liver resection ( $P < 0.05$ ; Table 1). Cinnamon induced antioxidant activities within a short time after the surgery, thereby contributing to postoperative recovery.

### 3-3. Elevation of postoperative plasma nitrite/nitrate (%control) and decline of basal plasma nitrite/nitrate following cinnamon consumption

As the results indicated, long-term cinnamon ingestion reduced the concentration of serum NO metabolites ( $P < 0.05$ ; Table 1). The rate of



**Figure 3:** Weight changes following liver resection in the research groups (Weight was measured both before the surgery and 2, 10, and 28 days after liver resection (POD2, POD10, and POD28) at the end of the 45<sup>th</sup> week (4 rats in each group). Results are reported as median (interquartile range). Statistical comparison between the groups was made using the Mann-Whitney U test [ $*p < 0.05$  POD2 control vs. cinnamon POD2].)

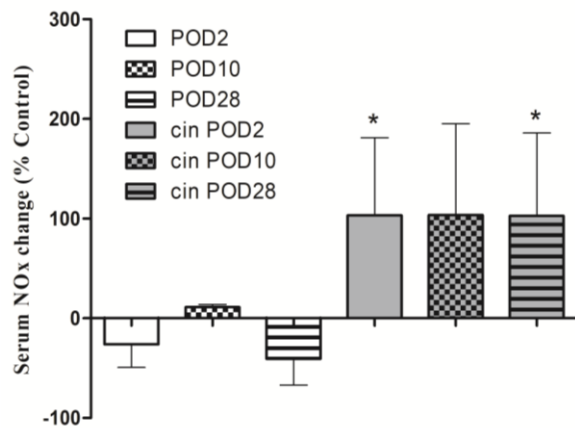
PH: partial hepatectomy

**Table 1:** Various serum biochemical parameters in the research groups

Groups	Variable (median±IQR)			
	FPG (mg/dl)	Insulin (pmol/l)	NOx (μmol/l)	MDA (μmol/l)
Control	94.89 [93.76, 96.88]	91.70 [39.93, 132.9]	88.70 [78.35, 104.5]	2.36 [1.88, 2.55]
Cinnamon	89.73 [86.77, 94.48]	133.5 [20.48, 343.2]	58.22 [34.04, 66.95]#	1.58 [1.0, 2.39]
POD 2	91.37 [87.12, 93.25]	173.4 [98.61, 247.2]	68.65 [40.56, 97.13]	3.74 [3.61, 4.59]
POD 10	90.69 [90.14, 92.68]	98.43 [64.82, 222.9]	88.65 [89.06, 113.6]	4.09 [3.24, 5.54]
POD 28	89.22 [87.57, 93.25]	52.24 [4.839, 83.87]	37.06 [27.61, 89.09]	3.29 [2.65, 4.03]
cin POD2	92.40 [89.27, 99.09]	160.8 [124.9, 199.0]	99.48 [87.56, 105.1]	2.99 [2.35, 3.55]*
cin POD10	90.44 [88.85, 95.01]	99.01 [81.52, 331.0]	94.58 [90.74, 101.8]	2.44 [2.27, 3.21]
cin POD28	93.87 [89.61, 96.25]	50.03 [8.918, 103.5]	90.73 [87.78, 112.4]	3.56 [2.62, 4.12]
P-value	0.3360	0.1226	0.0345	0.0068

Statistical comparison between the groups was made using the Kruskal-Wallis test. One to one comparison in each time point was performed by the Mann-Whitney U test. Values are displayed as median (interquartile range), with 4 cases per group.

NOx: nitrite+nitrate, MDA: malondialdehyde, FPG: fasting plasma glucose, POD (2, 10, and 28): 2, 10, and 28 days after partial (30%) hepatectomy ( $*p < 0.05$  significant vs. POD2, #  $p < 0.05$  significant vs. control)



**Figure 4: Effect of aging and cinnamon consumption on serum NOx (nitrate+nitrite; % control) 2, 10, and 28 days after partial hepatectomy (30%) in the research groups (NOx was calculated as the percentage increase (positive values) and decrease (negative values) of aging 2, 10, and 28 days after liver resection, compared to the control rats at the end of the 54<sup>th</sup> week (4 rats in each group). The results are reported as median (interquartile range). Statistical comparisons were made using the Mann-Whitney U test at a \*p-value of < 0.05 [aging+cinnamon treatment postoperatively vs. aging at the same time points])**

postoperative NOx variation was compared between the two groups at each time point (i.e., 2, 10, and 28 days postoperation). The results revealed a decrease in the postoperative plasma NOx in the control group. However, regarding the experimental group, the level of this compound underwent a significant elevation postoperatively. The inter-group comparison of plasma NOx variation at each time point demonstrated that cinnamon consumption significantly increased the postoperative plasma NOx level, compared to that in the controls, 2 and 28 days postsurgery ( $P < 0.05$ ; Figure 4).

## Discussion

The results of the present study were indicative of the significant effect of cinnamon consumption on weight loss compensation due to liver resection 48 h after the surgery. Weight loss and protein catabolism following surgical operations are parts of body defense against trauma (21). Poor nourishment results in the prolongation of convalescence and delay of wound healing. However, it is impossible to meet the body demands for nitrogen to replace what is lost in the catabolic phase of the postoperative period. Furthermore, the actual need for nitrogen and

indispensable amino acids increases with aging in animals (22). Cinnamon has been reported to increase the lean body mass or protein content in adult rats (23) and humans (24). Accordingly, it can restore the negative nitrogen balance/weight loss occurring due to surgery.

As the findings of the present study indicated, cinnamon consumption maintained oxidative balance in the rats undergoing liver resection by attenuating MDA. This herb facilitated the initiation of physiological responses to stress both during and after the surgical procedure. Surgical stress compromises a series of inflammatory reactions that, in turn, induce oxidative stress. Oxidative stress is defined as a situation in which the production of reactive oxygen/nitrogen species exceeds the mechanisms required for their scavenging/detoxification. Oxidative stress is an integrated part of the surgical stress response. Oxidative stress per se may be associated with postoperative complications, such as sepsis, pulmonary edema, liver failure, and increased mortality. Oxidative stress can induce negative impacts on major surgical procedures, including liver resection (5). This negative effect is particularly pronounced with aging (25).

Cinnamon facilitates the maintenance of the homeostatic mechanism during the surgery, thereby preventing multiorgan failure and increased mortality postoperation. The improvement of oxidative condition is a highly helpful measure in surgical geriatric patients. Antioxidant capacity decreases during the post-liver resection period (5). Moreover, severe postoperative complications are reportedly associated with a marked inflammatory response to surgery (8). The consumption of antioxidants, including cinnamon, could maintain oxidative balance within a healthy range (8). Proteins are the major targets of oxidative injuries (26). The anti-inflammatory property of polyphenols, as the major constituents of cinnamon, contributes to better recovery and nitrogen balance maintenance after the surgery. Some supplements, such as polyphenols, can be helpful owing to their antioxidant properties and higher protein efficiency.

Cinnamon exhibits superoxide dismutase-like (SOD) activities. To the best of our knowledge, no study has investigated cinnamon consumption as an agent for pharmacological preconditioning or complementary therapy for liver surgery yet. However, many studies have addressed the anti-inflammatory and antioxidant effects of cinnamon on hepatotoxicity (27), hepatocellular carcinoma (28), and other liver injury models (29, 30). In



these studies, cinnamon has been reported to have beneficial effects by reducing MDA or NO and inducing SOD activity. The hepatoprotective effect of cinnamon is attributed to the free radical-scavenging activities of its polyphenol compounds. Moreover, curcumin is reported to be a rich source of polyphenols, attenuating inflammation and oxidative stress 24 h (31) and 7 days after partial hepatectomy in male Sprague-Dawley rats (32).

Cinnamon can also facilitate the improvement of liver regeneration. Better recovery from liver resection surgery in cinnamon-treated rats can be attributed to its composition and related properties. As previously stated, cinnamon is composed of a rich source of polyphenol and has positive effects on the lean body mass. Therefore, this spice can induce positive effects on surgical outcomes by restoring oxidative damage.

As the findings of this indicated, cinnamon intake for 45 weeks lowered plasma NO<sub>x</sub> level since this herb acts as NO; therefore, it eliminates the need for NO production in vivo. Nevertheless, NO level increased in the rats treated with cinnamon, while it decreased in the control rats due to liver resection. In a study, NO production was reported to increase after liver resection (33). Furthermore, there is evidence regarding the improvement of liver regeneration in the rats subjected to hepatectomy as a result of L-arginine, as a precursor for NO (34). However, NO production, chiefly hepatic NO (2), is impaired by aging (35). Nitric oxide is synthesized from L-arginine substrate following the activation of NO synthase enzyme (NOS). There are three main forms of NOS, namely endothelial NOS (type III), neuronal NOS (type I), and inducible NOS (type II). After liver resection, inducible NOS is upregulated and acts as a mediator for other inflammatory molecules involving in liver repair (33). It can be concluded that following cinnamon consumption, NO can be synthesized in young animals, similar to that in adult animals. This seems to induce an impressive effect on the function of the hepatocytes.

## Conclusions

The findings of the present study revealed that cinnamon improved recovery from the liver resection surgery among rats by attenuating oxidative stress and modulating the nitric oxide level.

## Acknowledgments

The authors appreciate the Research Deputy of

BUMS for granting the permission to use the Animal Laboratory of the Experimental Medicine Center of BUMS.

## Funding

This paper is based on an M.D. thesis submitted by Mohammad Dastjerdi, which was fully supported by BUMS (grant No. 455669).

## Conflict of Interest

There is no conflict of interest.

## References

1. Franceschi C, Bonafè M, Valensin S, Olivieri F, De Luca M, Ottaviani E, et al. Inflamm-aging: an evolutionary perspective on immunosenescence. *Ann N Y Acad Sci.* 2000; 908(1):244-54. PMID: [10911963](#) DOI: [10.1111/j.1749-6632.2000.tb06651.x](#)
2. Hunt NJ, Kang SW, Lockwood GP, Le Couteur DG, Cogger VC, et al. Hallmarks of aging in the liver. *Computat Struct Biotechnol J.* 2019; 17:1151-61. PMID: [31462971](#) DOI: [10.1016/j.csbi.2019.07.021](#)
3. Kucukakin B, Gogenur I, Reiter RJ, Rosenberg J. Oxidative stress in relation to surgery: is there a role for the antioxidant melatonin? *J Surg Res.* 2009; 152(2):338-47. PMID: [18262562](#) DOI: [10.1016/j.jss.2007.12.753](#)
4. Tsuchiya M, Shiimoto K, Mizutani K, Fujioka K, Suehiro K, Yamada T, et al. Reduction of oxidative stress a key for enhanced postoperative recovery with fewer complications in esophageal surgery patients: Randomized control trial to investigate therapeutic impact of anesthesia management and usefulness of simple blood test for prediction of high-risk patients. *Medicine (Baltimore).* 2018; 97(47):e12845. PMID: [30461602](#) DOI: [10.1097/MD.00000000000012845](#)
5. Schwarz C, Fitschek F, Bar-Or D, Klaus DA, Tudor B, Fleischmann E, et al. Inflammatory response and oxidative stress during liver resection. *PLoS One.* 2017; 12(10):e0185685. PMID: [29045432](#) DOI: [10.1371/journal.pone.0185685](#)
6. Rosenfeldt F. Oxidative stress in surgery. In: Laher I, editor. *Systems biology of free radicals and antioxidants.* Berlin: Springer; 2014.
7. van Riel WG, van Golen RF, Reiniers MJ, Heger M, van Gulik TM. How much ischemia can the liver tolerate during resection? *Hepatobiliary Surg Nutr.* 2016; 5(1):58-71. PMID: [26904558](#) DOI: [10.3978/j.jssn.2304-3881.2015.07.05](#)
8. Senoner T, Schindler S, Stattner S, Öfner D, Troppmair J, Primavesi F. Associations of oxidative stress and postoperative outcome in liver surgery with an outlook to future potential therapeutic

- options. *Oxid Med Cell Longev*. 2019; 2019:3950818. [PMID: 30906502](#) [DOI: 10.1155/2019/3950818](#)
9. Assadollahi V, Parivar K, Roudbari NH, Khalatbary AR, Motamedi M, Ezatpour B, et al. The effect of aqueous cinnamon extract on the apoptotic process in acute myeloid leukemia HL-60 cells. *Adv Biomed Res*. 2013; 2:25. [PMID: 23977653](#) [DOI: 10.4103/2277-9175.108001](#)
  10. Ballin NZ, Sørensen AT. Coumarin content in cinnamon containing food products on the Danish market. *Food Control*. 2014; 38:198-203. [DOI: 10.1016/j.foodcont.2013.10.014](#)
  11. Askari F, Rashidkhani B, Hekmatdoost A. Cinnamon may have therapeutic benefits on lipid profile, liver enzymes, insulin resistance, and high-sensitivity C-reactive protein in nonalcoholic fatty liver disease patients. *Nutr Res*. 2014; 34(2):143-8. [PMID: 24461315](#) [DOI: 10.1016/j.nutres.2013.11.005](#)
  12. Hosseini S, Shojaei S, Hosseini S. The effects of cinnamon on glycemic indexes and insulin resistance in adult male diabetic rats with streptozotocin. *Yafte*. 2015; 16(4):70-8.
  13. López JJ, Jardín I, Salido GM, Rosado JA. Cinnamtannin B-1 as an antioxidant and platelet aggregation inhibitor. *Life Sci*. 2008; 82(19-20):977-82. [PMID: 18433795](#) [DOI: 10.1016/j.lfs.2008.03.009](#)
  14. Czaplińska M, Czepas J, Gwoździński K. Structure, antioxidative and anticancer properties of flavonoids. *Postepy Biochem*. 2012; 58(3):235-44. [PMID: 23373409](#)
  15. Khan A, Safdar M, Khan MM, Khattak KN, Anderson RA. Cinnamon improves glucose and lipids of people with type 2 diabetes. *Diabetes Care*. 2003; 26(12):3215-8. [PMID: 14633804](#) [DOI: 10.2337/diacare.26.12.3215](#)
  16. Reagan-Shaw S, Nihal M, Ahmad N. Dose translation from animal to human studies revisited. *FASEB J*. 2008; 22(3):659-61. [PMID: 17942826](#) [DOI: 10.1096/fj.07-9574LSF](#)
  17. Higgins GM. Experimental pathology of the liver; I. Restoration of the liver of the white rat following partial surgical removal. *Arch Pathol*. 1931; 12:186-202.
  18. Lahoti A, Kalra B, Tekur U. Evaluation of the analgesic and anti-inflammatory activity of fixed dose combination: non-steroidal anti-inflammatory drugs in experimental animals. *Indian J Dent Res*. 2014; 25(5):551-4. [PMID: 25511049](#) [DOI: 10.4103/0970-9290.147071](#)
  19. Ghasemi A, Mehrazin F, Zahediasl S. Effect of nitrate and L-arginine therapy on nitric oxide levels in serum, heart, and aorta of fetal hypothyroid rats. *J Physiol Biochem*. 2013; 69(4):751-9. [PMID: 23568620](#) [DOI: 10.1007/s13105-013-0251-x](#)
  20. Farrokhfall K, Khoshbaten A, Zahediasl S, Mehrani H, Karbalaei N. Improved islet function is associated with anti-inflammatory, antioxidant and hypoglycemic potential of cinnamaldehyde on metabolic syndrome induced by high tail fat in rats. *J Functional Foods*. 2014; 10(Suppl C):397-406. [DOI: 10.1016/j.jff.2014.07.014](#)
  21. Stein TP, Buzby GP. Protein metabolism in surgical patients. *Surg Clin North Am*. 1981; 61(3):519-27. [PMID: 7256512](#) [DOI: 10.1016/s0039-6109\(16\)42434-5](#)
  22. Baldwin JK, Griminger P. Nitrogen balance studies in aging rats. *Exp Gerontol*. 1985; 20(1):29-34. [PMID: 3996486](#) [DOI: 10.1016/0531-5565\(85\)90006-3](#)
  23. Lopes BP, Gaique TG, Souza LL, Paula GS, Kluck GE, Atella GC, et al. Cinnamon extract improves the body composition and attenuates lipogenic processes in the liver and adipose tissue of rats. *Food Funct*. 2015; 6(10):3257-65. [PMID: 26237537](#) [DOI: 10.1039/c5fo00569h](#)
  24. Liu Y, Cotillard A, Vatie C, Bastard JP, Fellahi S, Stévant M, et al. A dietary supplement containing cinnamon, chromium and carnosine decreases fasting plasma glucose and increases lean mass in overweight or obese pre-diabetic subjects: a randomized, placebo-controlled trial. *PLoS One*. 2015; 10(9):e0138646. [PMID: 26406981](#) [DOI: 10.1371/journal.pone.0138646](#)
  25. Rosenfeldt F, Wilson M, Lee G, Kure C, Ou R, Braun L, et al. Oxidative stress in surgery in an ageing population: Pathophysiology and therapy. *Exp Gerontol*. 2013; 48(1):45-54. [PMID: 22465624](#) [DOI: 10.1016/j.exger.2012.03.010](#)
  26. Dahl JU, Gray MJ, Jakob U. Protein quality control under oxidative stress conditions. *J Mol Biol*. 2015; 427(7):1549-63. [PMID: 25698115](#) [DOI: 10.1016/j.jmb.2015.02.014](#)
  27. Niknezhad F, Sayad-Fathi S, Karimzadeh A, Ghorbani-Anarkooli M, Yousefbeyk F, Nasiri E. Improvement in histology, enzymatic activity, and redox state of the liver following administration of Cinnamomum zeylanicum bark oil in rats with established hepatotoxicity. *Anat Cell Biol*. 2019; 52(3):302-11. [PMID: 31598360](#) [DOI: 10.5115/acb.18.180](#)
  28. Aly SM, Fetaih HA, Hassanin AA, Abomughaid MM, Ismail AA. Protective effects of garlic and cinnamon oils on hepatocellular carcinoma in albino rats. *Anal Cell Pathol (Amst)*. 2019; 2019:9895485. [PMID: 31781479](#) [DOI: 10.1155/2019/9895485](#)
  29. Haidari F, Mohammadshahi M, Abiri B, Zarei M, Fathi M. Cinnamon extract supplementation improves inflammation and oxidative stress induced by acrylamide: an experimental animal study. *Avicenna J Phytomed*. 2019; 10(3):243-52. [DOI: 10.22038/AJP.2019.13899](#)
  30. Moselhy SS, Ali HK. Hepatoprotective effect of cinnamon extracts against carbon tetrachloride

- induced oxidative stress and liver injury in rats. *Biol Res.* 2009; 42(1):93-8. [PMID: 19621136](#) [DOI: /S0716-97602009000100009](#)
31. Seehofer D, Schirmeier A, Bengmark S, Cho SY, Koch M, Lederer A, et al. Curcumin attenuates oxidative stress and inflammatory response in the early phase after partial hepatectomy with simultaneous intraabdominal infection in rats. *J Surg Res.* 2010; 159(1):497-502. [PMID: 19321178](#) [DOI: 10.1016/j.jss.2008.12.006](#)
  32. Toydemir T, Kanter M, Erboga M, Oguz S, Erenoglu C. Antioxidative, antiapoptotic, and proliferative effect of curcumin on liver regeneration after partial hepatectomy in rats. *Toxicol Ind Health.* 2013; 31(2):162-72. [PMID: 23299190](#) [DOI: 10.1177/0748233712469658](#)
  33. Carnovale CE, Ronco MT. Role of nitric oxide in liver regeneration. *Ann Hepato.* 2012; 11(5):636-47. [PMID: 22947523](#)
  34. Kurokawa T, An J, Tsunekawa K, Shimomura Y, Kazama S, Ishikawa N, et al. Effect of L-arginine supplement on liver regeneration after partial hepatectomy in rats. *World J Surg Oncol.* 2012; 10(1):99. [PMID: 22651848](#) [DOI: 10.1186/1477-7819-10-99](#)
  35. Sverdlov AL, Ngo DT, Chan WP, Chirkov YY, Horowitz JD. Aging of the nitric oxide system: are we as old as our NO? *J Am Heart Assoc.* 2014; 3(4):e000973. [PMID: 25134680](#) [PMCID: PMC4310385](#) [DOI: 10.1161/JAHA.114.000973](#)