




CASE REPORT

Surgical restorative treatment of periodontal disease related to external cervical root resorption: A case report

Shima Bijari¹ , Sediqe Ebrahimipour¹  

¹Assistant Professor, Department of Endodontics, Faculty of Dentistry and Dental Research Center, Birjand University of Medical Sciences, Birjand, Iran

Received: April 30, 2020

Revised: May 20, 2020

Accepted: July 19, 2020

Abstract

The occurrence of external cervical root resorption (ECRR) is rare. Herein, we report a case of extensive ECRR in the coronal third of the distal root of a mandibular right molar with food impaction and periapical radiolucency. The distal root was perforated and damaged due to delayed treatment. The resorptive defect was debrided, and the defect was restored with conventionally setting restorative glass-ionomer cement. Postoperative follow-up revealed complete healing.

Key words: External cervical resorption, Endodontic retreatment, Glass-Ionomer cement, Surgery

Introduction

Root resorption might be classified as internal or external resorption based on its location in relation to the root surface. External root resorption (ERR) can be further classified into transient apical breakdown, surface resorption, external inflammatory resorption, external replacement resorption, and external cervical resorption (ECR) (1). The ECR is one of the least understood types of external resorption. The ECR is the loss of dental hard tissue as a result of odontoclastic action usually initiating on the cervical region of the root surface of the teeth.

The ERR leads to reversible/irreversible loss of cementum, dentin, and bone. It occurs in both vital and pulpless teeth (2). Physiological and pathological ERR are the two types of ERR. Physiological root resorption is associated with primary teeth and a normal process because it leads to the exfoliation of the primary teeth (3). The ECR is an aggressive type of ERR that occurs on the surface of the root below the epithelial attachment and coronal aspect of the supporting

alveolar process.

Various predisposing factors are related to ECR, such as intra-coronal bleaching, orthodontic treatment and surgery, transplanted teeth, trauma, bruxism, guided tissue regeneration (GTR) (4), periodontal treatment (5), and injury and stimulation by sulcular microorganisms in the adjacent marginal tissues (6). Belanger and Coke (7) defined the term "idiopathic root resorption" as cases of root resorption where an etiological factor cannot be observed. Idiopathic ERR can occur in the apical region or cervical part of the root (8). The ECR is commonly painless and is diagnosed in routine radiologic examinations (9).

It is important to differentiate ECR from subgingival caries. The ECR feels sticky on probing and does not present with the pink spot (1). The base of an ECR defect will feel hard and result in a scraping sound when probed (10). Probing the ECR defect and/or associated periodontal pocket will cause significant bleeding of the highly vascular resorptive tissue (11). Once the granulation tissue has been removed from an ECR lesion, the cavity walls will feel hard and mineralized on probing.

©2020 Journal of Surgery and Trauma

Tel: +985632381203
Fax: +985632440488
Po Bax 97175-379
Email: jsurgery@bums.ac.ir

✉ Correspondence to:

Sediqe Ebrahimipour, Assistant Professor, Department of Endodontics, Faculty of Dentistry and Dental Research Center, Birjand University of Medical Sciences, Birjand, Iran;
Telephone Number: +98915344038
Email Address: sdent22@gmail.com

The edges of the cavity usually appear sharp and narrow.

Early lesions might be radiolucent; however, more advanced lesions might have a mottled appearance caused by the osseous nature of the advanced lesion (2). The treatment depends on the severity, location, perforation of the root canal system by the defect, and restorability of the tooth. Several treatment regimens have been suggested in the literature, depending on the nature of the ECR lesion, usually based on isolated case reports. These regimens include intentional replantation (12), GTR (13), treatment of the ECR lesion by an internal approach only (14), and forced orthodontic eruption (15).

Essentially, the treatment involves early diagnosis, complete removal of the resorptive tissue, and restorative treatment.

The three following options are considered for the treatment:

- 1) no treatment with eventual extraction when the tooth becomes symptomatic;
- 2) immediate extraction;
- 3) endodontic retreatment, periradicular surgery, and restoration (16)

To date, various materials have been introduced to seal the resorptive defect, such as mineral trioxide aggregate (MTA), glass-ionomer cement (GIC), calcium-enriched mixture (CEM), amalgam, and gutta-percha (17). Among these, MTA and CEM cement are unique biomaterials with proved cementogenic/osteogenic activities in histologic evaluation (18, 19). Therefore, the present case report presents the surgical management of the mandibular first molar with ECR using GIC.

Cases

A 38-year-old male patient complaining of mild pain in chewing and food impaction in the lower posterior portion of his jaw presented to the Department of Endodontics of Dentistry School in Zahedan University of Medical Sciences, Zahedan, Iran. The medical history of the patient was noncontributory. The dental history of the case revealed that he had undergone root canal treatment in tooth #19 2 years earlier.

The extraoral examination was unremarkable. The intraoral examination showed that tooth #19 was tender to percussion, and the buccal gingiva of the tooth was sensitive to palpation. Periodontal probing depths were within the normal limit at all sites of the tooth except the distobuccal surface with approximately 6-mm pocket depth, and bleeding on probing was obvious (Figure 1b). The

defect of the distal root structure was hard while sounding, and the tooth was not mobile.

Radiographic examination (Figure 1a) showed that tooth #19 received a poor endodontic treatment with the apical lesion of the mesial root, and there was a large defect with ragged or irregular margins in the cervical region of the distal root surface with a mottled appearance. The diagnosis was made as asymptomatic apical periodontitis with external cervical root resorption (ECRR) (11).

The possible treatment options were explained for the patient, and he was willing to maintain the tooth by any means. Therefore, endodontic retreatment for sealing the resorptive defect was planned. In addition, informed consent was obtained from the patient.

After administering local anesthesia (2% lidocaine with 1:80000 adrenaline; Daroupakhsh, Tehran, Iran), the tooth was isolated with a rubber dam, and the access cavity was prepared. Two mesial and distal root canals had been inadequately treated during the first treatment. A distobuccal canal was also missed. Root filling materials were removed from the root canals with the aid of the hand and rotary files. The working lengths of the root canals were determined using an electronic apex locator (Root ZX, Morita, Japan) and then confirmed with a digital radiograph (Figure 1c).

Root canal instrumentation was performed with Protaper rotary file system (Dentsply, Maillefer, Ballaigues, Switzerland). The S1, S2, F1, and F2 rotary files were employed up to the working length. The root canals were irrigated with normal saline solely during instrumentation due to the root canal perforation. Afterward, the root canals were dressed with calcium hydroxide-iodoform paste (Metapex; Meta-Biomed Ltd., Cheongju, Chungbuk, Korea) for 7 days and carnally sealed with a temporary filling material.

At the next appointment, after the administration of local anesthesia, calcium hydroxide was gently removed. The canals were flushed with normal saline, dried with paper points #30 (Ariadent, Iran), and filled with gutta-percha (#30/0.04 as a master cone; Ariadent, Iran) and AH Plus sealer (Dentsply DeTrey GmbH, Germany) by lateral compaction technique. As the defect was on the cervical area, surgical intervention was planned. A triangular full-thickness flap was reflected, and hemostasis was achieved. A large resorptive area with sharp borders in relation to the root canal was clearly observed in the surgical site containing granulation tissue that confirms the diagnosis (Figure 1d).

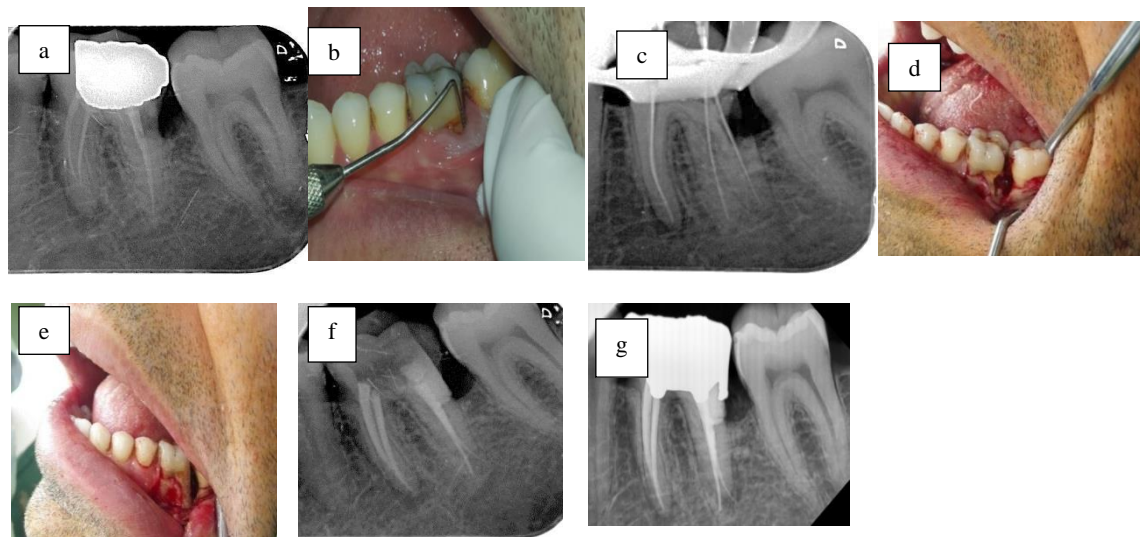


Figure 1: (a) Preoperative radiograph of teeth #19; (b) clinical examination and pocket depth of 6 mm at proximal distal root surface; (c) non-surgical endodontic retreatment of tooth #19; (d) surgical exposure of the resorptive area; (e) restoration of the defect with glass-ionomer cement; (f) post-operative radiograph; (g) follow-up radiograph 3 month after operation

Granulation tissue was excavated from the resorptive area using a hand excavator (Hu-Friedy, Chicago, IL, USA). The cavity was treated with 90% of aqueous trichloroacetic acid to necrotize the remaining tissues. After refreshing the defect with a round bur using a low-speed handpiece, the resorptive area was dried and filled with GIC (Fuji IX, GC Corporation, Tokyo, Japan). The area was kept isolated from blood and tissue fluids during the setting of GIC (Figure 1e).

A periapical radiograph was taken to confirm the proper restoration of the resorptive area (Figure 1f). The surgical field was cleaned, and the flap was placed back and sutured with a non-resorbable 3-0 silk thread. After the surgery, the patient was prescribed a 500-mg dose of amoxicillin three times a day for 1 week and 0.2% chlorhexidine mouthwash twice a day for 2 weeks. The patient was asked to refer after a week for suture removal.

After the removal of the suture, the patient was advised for regular follow-ups. However, he referred to the department only once 3 months later. He was completely asymptomatic with no sign or symptom in clinical and radiographic examinations (Figure 1g).

Discussion

Progressive ECRR has an inflammatory origin and develops immediately below the epithelial adhesion. It often occurs in the cervical region of the tooth. Its exact pathogenesis has not been elucidated; however, it appears that any changes in

the protective layer of the root surface (i.e., cementum) cause the attraction of clastic cells to the area, followed by inflammation leading to the continuation of the resorption process (13).

The causes of root surface damage include orthodontic tooth movement, trauma, non-vital tooth bleaching, periodontal treatments, and other idiopathic causes (14). The bacteria of gingival sulcus appear to cause an inflammatory response in the epithelial attachment region (14). This type of resorption starts from the small area and extends into the dentin. Subsequently, it irregularly spreads under the enamel and cementum along the longitudinal axis of the root. This kind of resorption is also observed in the adjacent bone.

There are two possibilities for the etiology of resorption in this patient as follows:

1. bacteria and their byproducts penetrated from the contaminated canal to the outer surface of the root through the dentinal tubules and/or
2. periodontal disease due to the previous defective restoration and prolonged food impaction leading to the activation of the resorptive-causing bacteria in the gingival sulcus

It is claimed that the potential reason for this resorption is more probable due to prolonged food impaction and periodontal involvement. The most effective approaches for an extensive ECR consist of exposing the resorptive area orthodontically or surgically and removing the granulation tissue and restoring it with proper restorative material (20). Due to the presence of a large communication

between the resorptive defect and root canal space, the treatment plan of the present report was a combination of surgical approach and non-surgical root canal retreatment. The surgical plan involved periodontal flap reflection, curettage of the lesion, and restoration of the defect with GIC. In the present case, the lesion was above the alveolar crest and was exposed to the oral and gingival fluids.

The utilization of amalgam, GIC, MTA, or resin composite has been reported in several cases (15, 21-23). The use of MTA as a repair material demonstrated favorable results in several case series with invasive cervical resorption (21-23). Some of its favorable properties are an increase in the radiodensity of crestal bone when used in combination with GTR to repair ERR associated with a bony defect, osteoblast cell attachment essential for osteogenesis, no negative effect on the viability and morphology of cementoblasts, and induced biomineralization of cementoblasts on the root surface (24). However, in the areas that will have constant contact with the oral flora, similar to the case in the present study, the MTA will be continuously contaminated.

The GIC was considered sealing material because it is biocompatible and adheres chemically to dentin (25). It was chosen for its short setting time, more quick manipulation under difficult circumstances, and less sensitivity to early contact with fluids (e.g., blood). Previous studies have shown that conventionally setting GIC has an acceptable resistance to moisture contamination, and surface hardness of GIC increases with time when generally stored in a humid atmosphere (26).

The GIC has also exhibited a better long-term root-end sealing than intermediate restorative material and MTA (27) based on a case report. The extensive use of GIC to rebuild a root was reported successful (28). It is required to carry out further follow-up studies on whether the use of GIC is advantageous in the long term.

Conclusions

If ECRR is diagnosed in time, it can be successfully treated using proper strategies. The GIC is a good choice for sealing and filling the external resorption defects. The prognosis of the treatment depends on the location, size, accessibility of the defect, and establishment of structural integrity between the tooth and periodontium. The consent of the patient is particularly important in cases with an unknown prognosis.

Conflict of Interest

The authors declare that there is no conflict of interest.

References

1. Patel S, Ford TP. Is the resorption external or internal? *Dental Update*. 2007; 34(4):218-29. [PMID: 17580820](#) [DOI: 10.12968/denu.2007.34.4.218](#)
2. Bergmans L, Van Cleynenbreugel J, Verbeken E, Wevers M, Van Meerbeek B, Lambrechts P. Cervical external root resorption in vital teeth: X-ray microfocus-tomographical and histopathological case study. *J Clin Periodontol*. 2002; 29(6):580-5. [PMID: 12296786](#) [DOI: 10.1034/j.1600-051x.2002.290615.x](#)
3. Patel S, Kanagasingam S, Ford TP. External cervical resorption: a review. *J Endod*. 2009; 35(5):616-25. [PMID: 19410071](#) [DOI: 10.1016/j.joen.2009.01.015](#)
4. Kandalgaonkar SD, Gharat LA, Tupsakhare SD, Gabhane MH. Invasive cervical resorption: a review. *J Int Oral Health*. 2013; 5(6):124-30. [PMID: 24453457](#)
5. Heithersay GS. Invasive cervical resorption: an analysis of potential predisposing factors. *Quintessence Int*. 1999; 30(2):93-5. [PMID: 10356560](#)
6. Gold SI, Hasselgren G. Peripheral inflammatory root resorption: a review of the literature with case reports. *J Clin Periodontol*. 1992; 19(8):523-34. [PMID: 1447376](#) [DOI: 10.1111/j.1600-051x.1992.tb00679.x](#)
7. Belanger GK, Coke JM. Idiopathic external root resorption of the entire permanent dentition: report of case. *ASDC J Dent Child*. 1985; 52(5):359-63. [PMID: 3862683](#)
8. Yusof WZ, Ghazali MN. Multiple external root resorption. *J Am Dent Assoc*. 1989; 118(4):453-5. [PMID: 2708724](#) [DOI: 10.14219/jada.archive.1989.0182](#)
9. Heithersay GS. Invasive cervical resorption. *Endod Top*. 2004; 7(1):73-92. [DOI: 10.1111/j.1601-1546.2004.00060.x](#)
10. Liang H, Burkes EJ, Frederiksen NL. Multiple idiopathic cervical root resorption: systematic review and report of four cases. *Dentomaxillofac Radiol*. 2003; 32(3):150-5. [PMID: 12917279](#) [DOI: 10.1259/dmfr/12925020](#)
11. Cohen S, Burns R. *Pathways of the pulp*. 8th ed. St Louis: Mosby; 2002. P. 2.
12. Frank AL, Torabinejad M. Diagnosis and treatment of extracanal invasive resorption. *J Endod*. 1998; 24(7):500-4. [PMID: 9693580](#) [DOI: 10.1016/S0099-2399\(98\)80056-3](#)
13. Rankow HJ, Krasner PR. Endodontic applications of guided tissue regeneration in endodontic surgery. *J Endod*. 1996; 22(1):34-43. [PMID: 8618084](#) [DOI: 10.1016/S0099-2399\(96\)80234-2](#)

14. Frank AL, Bakland LK. Nonendodontic therapy for supraosseous extracanal invasive resorption. *J Endod.* 1987; 13(7):348-55. [PMID: 3481799](#) [DOI: 10.1016/S0099-2399\(87\)80117-6](#)
15. Trope M. Subattachment inflammatory root resorption: treatment strategies. *Pract Periodontics Aesthet Dent.* 1998; 10(8):1005-10. [PMID: 9863460](#)
16. Schwartz RS, Robbins JW, Rindler E. Management of invasive cervical resorption: observations from three private practices and a report of three cases. *J Endod.* 2010; 36(10):1721-30. [PMID: 20850686](#) [DOI: 10.1016/j.joen.2010.06.011](#)
17. Bodrumlu E. Biocompatibility of retrograde root filling materials: a review. *Aust Endod J.* 2008; 34(1):30-5. [PMID: 18352901](#) [DOI: 10.1111/j.1747-4477.2007.00085.x](#)
18. Asgary S, Eghbal MJ, Ehsani S. Periradicular regeneration after endodontic surgery with calcium-enriched mixture cement in dogs. *J Endod.* 2010; 36(5):837-41. [PMID: 20416429](#) [DOI: 10.1016/j.joen.2010.03.005](#)
19. Samiee M, Eghbal MJ, Parirokh M, Abbas FM, Asgary S. Repair of furcal perforation using a new endodontic cement. *Clin Oral Investig.* 2010; 14(6):653-8. [PMID: 19888611](#) [DOI: 10.1007/s00784-009-0351-8](#)
20. Tronstad L. Root resorption--etiology, terminology and clinical manifestations. *Endod Dent Traumatol.* 1988; 4(6):241-52. [PMID: 3078294](#) [DOI: 10.1111/j.1600-9657.1988.tb00642.x](#)
21. Yilmaz HG, Kalender A, Cengiz E. Use of mineral trioxide aggregate in the treatment of invasive cervical resorption: a case report. *J Endod.* 2010; 36(1):160-3. [PMID: 20003958](#) [DOI: 10.1016/j.joen.2009.07.002](#)
22. Main C, Mirzayan N, Shabahang S, Torabinejad M. Repair of root perforations using mineral trioxide aggregate: a long-term study. *J Endod.* 2004; 30(2):80-3. [PMID: 14977301](#) [DOI: 10.1097/00004770-200402000-00004](#)
23. Pace R, Giuliani V, Pagavino G. Mineral trioxide aggregate in the treatment of external invasive resorption: a case report. *Int Endod J.* 2008; 41(3):258-66. [PMID: 18042223](#) [DOI: 10.1111/j.1365-2591.2007.01338.x](#)
24. Hakki SS, Bozkurt SB, Hakki EE, Belli S. Effects of mineral trioxide aggregate on cell survival, gene expression associated with mineralized tissues, and biomineralization of cementoblasts. *J Endod.* 2009; 35(4):513-9. [PMID: 19345796](#) [DOI: 10.1016/j.joen.2008.12.016](#)
25. De Bruyne M, De Moor R. The use of glass ionomer cements in both conventional and surgical endodontics. *Int Endod J.* 2004; 37(2):91-104. [PMID: 14871175](#) [DOI: 10.1111/j.0143-2885.2004.00769.x](#)
26. De Moor RJ, Verbeeck RM. Changes in surface hardness of conventional restorative glass ionomer cements. *Biomaterials.* 1998; 19(24):2269-75. [PMID: 9884039](#) [DOI: 10.1016/s0142-9612\(98\)00135-5](#)
27. De Bruyne M, De Bruyne RJ, Rosiers L, De Moor R. Longitudinal study on microleakage of three root-end filling materials by the fluid transport method and by capillary flow porometry. *Int Endod J.* 2005; 38(2):129-36. [PMID: 15667635](#) [DOI: 10.1111/j.1365-2591.2004.00919.x](#)
28. Homme GM, Browaeys HA, De Moor RJ. Surgical root restoration after external inflammatory root resorption: a case report. *J Endod.* 2006; 32(8):798-801. [PMID: 16861085](#) [DOI: 10.1016/j.joen.2005.10.038](#)