



Original Article

Determine the effect of Low-Level Laser Therapy on pain, swelling, and trismus after impacted mandibular third molar surgery

Narjes Akbari¹, Marzieh Mohamadimoghadam², Amir Mohammad Chaji³

¹ Associate Professor of Oral & Maxillofacial Medicine, Department of Oral & Maxillofacial Diseases, School of Dentistry, Infectious Diseases Research Center, Birjand University of Medical Sciences, Birjand, Iran

² Department of Periodontics, School of Dentistry, Birjand University of Medical Sciences, Birjand, Iran

³ Student Research Committee, Birjand University of Medical Sciences, Birjand, Iran

Corresponding Author:

Tel: +989153771364

Email: mohamadi_moghadam@yahoo.com

Abstract

Introduction: Dental surgeries are always associated with pain and swelling for several consecutive days. Recent articles have shown conflicting results in the use of new techniques such as low-power lasers to treat postoperative pain and swelling. This study aimed to evaluate the reduction of pain, swelling, and trismus after surgery of the third molar impacted tooth after the use of a low-power laser.

Method: This study was a randomized, single-blind, split-mouth clinical trial involving patients who were referred to the special clinic of Birjand Dental School from December 2021 to June 2021 and required bilateral removal of the occluded third molars. Immediately after surgery, the patient was given a radiation laser with a wavelength of 780 nm and a power of 70 MW for 30 seconds at a dose or power density of 52.5 j/cm². The extent of swelling and trismus was assessed by measuring the dimensions of the face and the amount of mouth opening as well as the amount of pain on the second and seventh days after surgery. Statistical analysis was performed using the Wilcoxon and Mann–Whitney U test by SPSS (Version 21) at the significant level of (5 %).

Results: Intensity of pain and swelling decreased significantly over time and the amount of trismus increased significantly during the seventh day compared to the second day (p.value<0.05). The amount of pain on the 7th day after surgery in the group without laser was 1.98±0.26 and the amount of pain in the group with laser was 0.85 ± 0.92 which was not statistically significant between the two groups (value>0.05). The amount of trismus on 7-day was 38.79 ±9.94 and on the side, with laser, it was no significant difference. The distance between the tragus and the corner of the lip on day 7 after surgery was 110.03 ± 5.77 mm and in the laser group was 109.66 ±5.67 mm, no significant difference was observed between the two groups. The distance between the gonium and the outer corner on day 7 after surgery was 98.84 ±7.24 mm in the laser group and 98.21± 6.93 mm in the non-laser group and no significant difference was observed.

Conclusion: The use of low power laser reduced the pain, reduce postoperative swelling, and trismus caused by surgery but this reduction was not significant. Therefore, it is suggested that the study method should be changed and the sample size must be increased in further studies.

Keywords: Low-Level Light Therapy, Third Molar, Tooth Extraction, Trismus, Pain, Edema

Citation: Akbari N, Mohamadimoghadam M, Chaji AM. Determine the effect of Low-Level Laser Therapy on pain, swelling, and trismus after impacted mandibular third molar surgery. J Surg Trauma. 2022;10(4):137-144.

Received: January 1, 2022

Revised: July 23, 2022

Accepted: October 10, 2022

Introduction

Extracting impacted lower third molars (LTIMs) is one of the most common oral surgeries (1). Trauma to the bones and soft tissues is unavoidable in this surgery. The patient usually experiences side effects such as pain, swelling, and trismus in the first few days after surgery (2, 3).

These complications can affect patients' daily activities such as sleeping, eating, and chewing, and may even prevent some patients from undergoing further surgery (3,4). The pain usually peaks 3 to 5 hours after surgery after reducing the effect of local anesthesia, while swelling peaks 12 to 48 hours later (5). Although the pain and swelling gradually go away in the first week after surgery, reducing these complications is an important goal for surgeons and patients. Most surgeons have tried to reduce pain and swelling with painkillers, nonsteroidal anti-inflammatory drugs, or corticosteroids after surgery, but the side effects of these drugs remain a concern (3). The use of methods such as low-intensity laser or low-level laser therapy (LLLT) seems to be effective in reducing swelling, and pain by controlling the inflammatory process. LLLT promotes tissue healing without causing side effects in patients (6, 7).

LLLT has been considered in various studies because it can enhance several benefits depending on the dose used, the radiation wavelength, the time of use, and the conditions of the tissue being treated. LLLT triggers a variety of biological reactions, it increased cellular metabolism and regenerative potential. Weakening orthodontic pain, reducing dentin sensitivity, and reducing the signs and symptoms of temporomandibular joint disorders; LLLT is used in dentistry (8). Although LLLT has been used to prevent swelling and trismus after third molar surgery, the results of previous studies are controversial (8-10). Consequently, it seems necessary to conduct more studies to find the causes of these contradictions and to arrive at a unique protocol for the use of LLLT in order to reduce the complications in the extraction of the third molar surgery.

Due to the lack of definitive results in the use of LLLT to reduce postoperative complications in

patients, this study was performed to evaluate the reduction of pain, swelling, and trismus after surgery of the third molar impacted tooth after the use of LLLT.

Materials and Methods

This study was a randomized, single-blind, split-mouth clinical trial which registered with the code IRCT(20210928052620N1) on the clinical trial site, and was written in accordance with the CONSORT guidelines. Statistical community was involving patients who were referred to the special clinic of Birjand Dental School from December 2020 to June 2021, and required bilateral extraction of the impacted third mandibular molars.

Randomly for one sided used LLLT after surgery and for another side not used LLLT. Inclusion criteria were patients of both sexes who consciously tended to extract the mandibular impacted teeth on both sides, where the impacted teeth on both sides should be the same in terms of depth and angle of occlusion (according to Pell & Gregory). Exclusion criteria are patients with any systemic disease, patients who have used corticosteroids for more than 3 months, or patients whose impacted teeth are not the same in-depth and angle of incidence. Details of subjects screened was presented in (Figure 1).

Extraction of impacted teeth was performed by a maxillofacial surgeon in the experimental and control groups. Surgical extraction and similar flaps were performed for both impacted mandibular incisors. Osteotomy and sectioning were performed for the patient if necessary.

Laser therapy was then performed by a person who is blind to the group and method of the study. So in the same treatment session for patients, a low-level laser device was randomly placed on one side of their mouth (laser experimental group), and on the opposite side, the laser device was turned off (control group). All patients were given a dose of ibuprofen 400 mg as a painkiller. A radiation laser at a close distance from the surgery area with a diode laser with a wavelength of 780 nm and a power of 70 MW was given to the patient for 30 seconds at a dose of 52.5 j/cm².

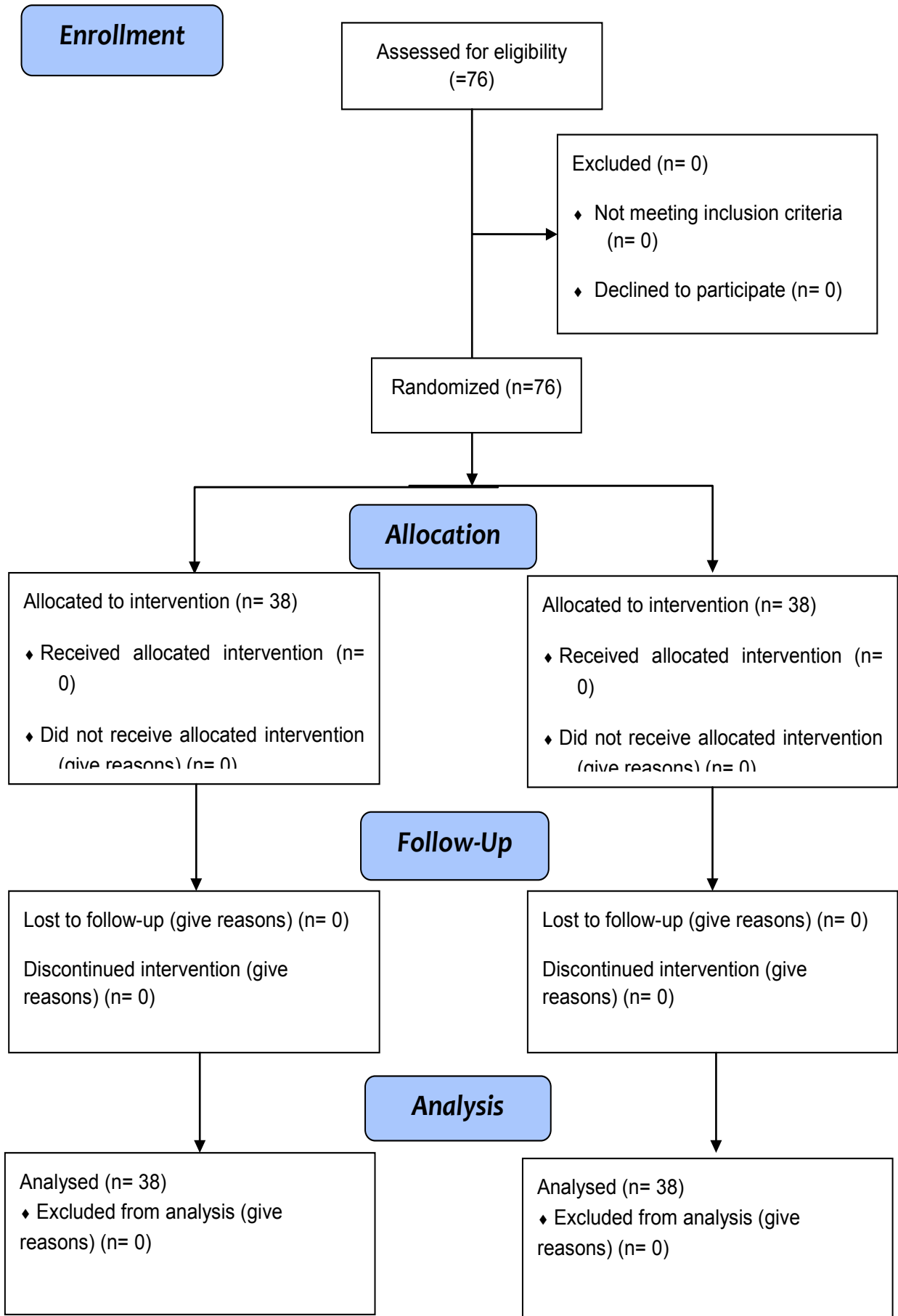


Figure 1. The CONSORT Flow Diagram of the study

Patients were then asked to record the amount of postoperative pain at home with The Visual Analogue Scale (VAS) for 7 days after surgery to determine the perceived pain.

Draw a horizontal line and divide it into ten parts. So zero (left) indicates no pain and 10 (right) indicates maximum pain. Pain Severity was recorded before bedtime for 7 days after surgery.

To determine the extent of swelling and trismus of the face, the patient was asked to refer to the office on days 2 and 7 after surgery. Swelling and trismus of the face were measured before surgery too (baseline).

The distance between the tragus and the corner of the lip and the distance between the gonium and the outer corner of the eye was measured in millimeters for swelling, and the maximum interincisal opening was measured in millimeters to determine the amount of trismus.

Finally, the data analysis was performed by another person who was blind to the treatment process.

The collected data were entered into SPSS software (Version 21) and the Kolmogorov-Smirnov test was used to evaluate the normality of data distribution. All the data had a non-normal distribution.

Statistical analysis was performed using Wilcoxon and Mann-Whitney U test. It should be noted that the significance level in all tests was considered 5%.

In this study, the researcher explained the objectives of the study and invited patients to participate in the study.

They wished to participate in the study, written and informed consent was obtained. The plan was approved by the Regional Committee on Research Ethics.

The code of ethics is IR.BUMS.REC.1399.454 and the details of the participants remained confidential.

Results

In our study, the pain in the side that was treated with a low-level laser (laser side) was less than

the untreated side two days after tooth extraction, but there was no significant difference between the laser side and the control side ($P = 0.094$).

Seven days after surgery, the pain in the laser side was less than on the control side, but the difference was neither significant ($P = 0.113$).

Within 3 days, from day 2 to day 5, the amount of pain significantly decreased on both the control and laser sides ($P < 0.001$) (Table 1).

Trismus was higher on the laser side than on the untreated side two days after tooth extraction, but this rate was not significant ($P = 0.794$).

Seven days after surgery, the amount of trismus in the area treated with a low-power laser was less than the untreated side, but this rate was not significant ($P = 0.954$).

Over time, from 2 days to 7 days, the amount of trismus decreased significantly in both the control and laser sides ($P < 0.001$) (Table 1).

Two days after surgery, the distance between the tragus and the corner of the lip on the side that was treated with a low-power laser was less than the untreated side, but this difference was not significant ($P = 0.228$).

Seven days after surgery, the distance between the tragus and the corner of the lip on the laser side was less than the control side, but the difference was not significant ($P = 0.679$).

Over time, from day 2 to day 7, the trismus decreased significantly in both control and laser groups ($P < 0.001$) (Table 1).

The distance between the gonion and the lateral cantus of the eye on the laser side was less than the control side in the next two days after surgery, but the difference was not significant ($P = 0.834$).

Seven days after surgery, the distance between the gonion and the lateral cantus of the eye on the laser side was less than on the untreated side, but this was not significant ($P = 0.867$).

Over time, from day 2 to day 7, the distance between the gonion and the lateral cantus of the eye decreased significantly in both control and laser groups ($P < 0.001$) (Table 1).

Table 1: Paired and independent comparisons of pain, Trismus, and, edema (The distance between the tragus and the corner of the lip, and the distance between the Gonion and the lateral cantus of the eye) in the groups by studied days

Item	Postoperative time	Control side (mean± (SD))	laser side (mean± SD)	Results of Mann–Whitney U test
Pain	Day 2	5.71±1.72	5.05±1.54	Z=-1.674; P=0.094
	Day 7	1.26±0.98	0.92±0.85	Z=-1.585; P=0.113
Results of Wilcoxon test		T13.84=; P<0.001	T14.46=; P<0.001	
Trismus	Day 2	29.32±10.64	29.61±10.76	Z=-0.261; P=0.794
	Day 7	38.79±9.94	38.58±10.02	Z=-0.057; p=0.954
Results of Wilcoxon test		T4.01=; P<0.001	T3.76=; P<0.001	
The distance between the tragus and the corner of the lip	Day 2	116.63±6.26	115.13±5.57	Z=-1.205; P=0.228
	Day 7	110.03±5.77	109.66±5.67	Z=-0.414; P=0.679
Results Wilcoxon test		T4.78=; P<0.001	T4.24=; P<0.001	
The distance between the Gonion and the lateral cantus of the eye	Day 2	103.55±7.16	103.08±7.03	Z=-0.209; P=0.834
	Day 7	98.84±7.24	98.21±6.93	Z=-0.167; P=0.867
Results of Wilcoxon test		T2.85=; P=0.006	T3.04=; P=0.00	

Discussion

This study aimed to evaluate the effect of LLLT in the reduction of pain, swelling, and trismus after impacted mandibular third molar surgery. After the third molar surgery, the patients were exposed to an LLLT; then 2 and 7 days postoperative the amount of pain, swelling, and trismus in patients were assessed. In our study, the amount of pain, swelling, and trismus on days 2 and 7 after surgery were not significantly different between the LLLT received side and control side (p-value >0.05); but, the amount of pain, swelling, and trismus were significantly reduced in two groups in 7 day compared with 2 day (p-value <0.001).

These results are similar to the López-Ramírez et al. (2012), Asutay et al. (2018), and Amarillas-Escobar et al. studies, which showed no statistically significant difference in the amount of pain, swelling, or trismus

between the control and laser groups (5,11,12). In Asutay et al. study the pain level in the test group was significantly lower than that in Group 3 at all-time points (11). But, these results were in contrast with Ferrante et al. (2012), Intan et al. (2018) and Santos et al. (2020), Eshghpour et al., and koparal et al. (2018) studies (13-15,3,16). On Ferrante et al., koparal et al. and Intan et al. studies, group test showed improvement in the interincisal opening and remarkable reduction of trismus, swelling and intensity of pain on the first and the seventh postoperative days (11).

Santos et al. showed that LLLT was effective in reducing pain after surgical removal of unerupted third molars immediately after surgery, after laser application, 24 hours after surgery, 48 hours after surgery, and 72 hours after surgery (15).

This contradiction in the results has been shown in

other studies. So that, in two systematic review and meta-analysis conducted by Duarte de Oliveira et al (2021) and He et al (2015) were showed that the low-intensity laser therapy has significantly reduced the pain and edema after third molar surgery, but not reduced trismus (9). While, in another systematic review and meta-analysis conducted by Domah et al (2020) found that LLLT significantly reduces swelling after extraction of mandibular third molars compared with placebo, but has not shown reduction in postoperative pain and trismus (17). It seems that the heterogeneity in the type of intervention and evaluation of the outcomes as well as the risk of bias of the trials are the main cause in these contradictions (18).

In this study, we used the radiation laser with a wavelength of 780 nm and a power of 70 MW for 30 seconds at a dose or power density of 52.5 j/cm² for 38 patients and compared it with 38 controls. However, Markovich and Todorovich suggested a post-operative AsGaAl laser (637 nm, 4 J/cm², 50 MW, 10 minutes at a distance of 1 cm from the surgical wound) to reduce postoperative pain and their study included 90 patients who were divided into three groups of 30 patients (19). In Santos et al. study, 32 patients in test group received LLLT with output power of 70 mW, dose or power density of 52.5 J/cm², and irradiation time of 30 seconds per point (15).

In Kopal et al. study, forty-five patients were divided into three groups. (16).

the first group received the usual treatment and was known as the control group. The second group was applied by a dose of gallium aluminium-arsenide laser (with energy of 4 joules and a duration of 40 seconds to the master muscle immediately after the operation. In the third group, the same laser was applied immediately after the operation and two days after the operation (20).

So, the difference in our results and previous articles is due to the difference in the method and frequency of laser use.

Aras and Gongormus found that the diode laser had better results in reducing swelling and trismus when the laser was applied orally near the location of the master muscle than when it was used orally.

According to these authors, surgical procedures may cause spasms in some muscles, especially the master muscle, so intraoral laser therapy does not directly affect this muscle (4). This may be one of the reasons why we did not get good results in reducing trismus in our study, although intraoral use may increase the relaxation of other masticatory muscles, such as the internal pterygoid. Thus, the effects of LLLT when administered intraorally and extra orally to a patient have also been studied (9,10).

Aras and Gongormos observed that internal and external oral laser uses significantly reduced trismus and swelling 7 days after surgery. In their study, diode laser radiation at 808 nm and 100 mW was applied for 120 seconds, 1 cm from the surgical wound (intraorally), and for another 120 seconds in contact with the master site (extra-orally) immediately after surgery (21).

Amarillas-Escobar et al. conducted a similar study but administered multiple daily doses to patients to evaluate the cumulative effect of laser therapy. In this case, patients received an intraoral laser immediately after surgery and were irradiated for three postoperative sessions (24, 48, and 72 hours) with six dots distributed on the affected side of the face (12).

Totally, in order to resolve these contradictions, a suggestion was made to conduct more clinical trials in the future with larger samples and with different low-level laser wavelengths to examine the therapeutic effect of laser on complications following the surgical operation of the impacted third molar.

Conclusion

The results of this study showed that the use of gallium arsenide laser as oral administration did not significantly reduce postoperative swelling and trismus after surgery of the lower third molar. The pain was reduced by using LLLT but this decrease was not significant. It is essential to increase the sample size and consider new studies to evaluate the analgesic and anti-inflammatory effects of LLLT.

Acknowledgments

None.

Funding

The authors received no financial support for the research and/or authorship of this article.

Conflicts of Interest

There is no conflict of interest.

References

- Zhang Y, Chen X, Zhou Z, Hao Y, Li H, Cheng Y, et al. Effects of Impacted Lower Third Molar Extraction on Periodontal Tissue of the Adjacent Second Molar. *Ther Clin Risk Manag.* 2021;17:235-247.
- Cho H, Lynham AJ, Hsu E. Postoperative interventions to reduce inflammatory complications after third molar surgery: review of the current evidence. *Aust Dent J.* 2017;62(4):412-419.
- Eshghpour M, Ahrari F, Takallu M. Is Low-Level Laser Therapy Effective in the Management of Pain and Swelling After Mandibular Third Molar Surgery?. *J Oral Maxillofac Surg.* 2016;74(7):1-8.
- Sayed N, Bakathir A, Pasha M, Al-Sudairy S. Complications of Third Molar Extraction: A retrospective study from a tertiary healthcare centre in Oman. *Sultan Qaboos Univ Med J.* 2019;19(3):230-235.
- López-Ramírez M, Vílchez-Pérez MA, Gargallo-Albiol J, Arnabat-Domínguez J, Gay-Escoda C. Efficacy of low-level laser therapy in the management of pain, facial swelling, and postoperative trismus after a lower third molar extraction. A preliminary study. *Lasers Med Sci.* 2012;27(3):559-566.
- Fávaro-Pípi E, Ribeiro DA, Ribeiro JU, Bossini P, Oliveira P, Parizotto NA, et al. Low-level laser therapy induces differential expression of osteogenic genes during bone repair in rats. *Photomed Laser Surg.* 2011;29(5):311-317.
- Kahraman SA, Cetiner S, Strauss RA. The Effects of Transcutaneous and Intraoral Low-Level Laser Therapy After Extraction of Lower Third Molars: A Randomized Single Blind, Placebo Controlled Dual-Center Study. *Photomed Laser Surg.* 2017;35(8):401-417.
- Aras MH, Güngörmüş M. Placebo-controlled randomized clinical trial of the effect two different low-level laser therapies (LLLT)--intraoral and extraoral--on trismus and facial swelling following surgical extraction of the lower third molar. *Lasers Med Sci.* 2010;25(5):641-645.
- Duarte de Oliveira FJ, Brasil G, Araújo Soares GP, Fernandes Paiva DF, de Assis de Souza Júnior F. Use of low-level laser therapy to reduce postoperative pain, edema, and trismus following third molar surgery: A systematic review and meta-analysis. *J Craniomaxillofac Surg.* 2021;49(11):1088-1096.
- Markovic A, Todorovic L. Effectiveness of dexamethasone and low-power laser in minimizing oedema after third molar surgery: a clinical trial. *Int J Oral Maxillofac Surg.* 2007;36(3):226-229.
- Asutay F, Ozcan-Kucuk A, Alan H, Koparal M. Three-dimensional evaluation of the effect of low-level laser therapy on facial swelling after lower third molar surgery: A randomized, placebo-controlled study. *Niger J Clin Pract.* 2018;21(9):1107-1113.
- Amarillas-Escobar ED, Toranzo-Fernández JM, Martínez-Rider R, Noyola-Frías MA, Hidalgo-Hurtado JA, Serna VM, et al. Use of therapeutic laser after surgical removal of impacted lower third molars. *J Oral Maxillofac Surg.* 2010;68(2):319-324.
- Ferrante M, Petrini M, Trentini P, Perfetti G, Spoto G. Effect of low-level laser therapy after extraction of impacted lower third molars. *Lasers Med Sci.* 2013;28(3):845-849.
- Intan AD, Murdana N, Nuhonni SA, Dwi L, Shatri H. Effect of low-level laser therapy (LLLT) on post-operative pain, trismus and quality of life (QOL) of patients undergoing extraction of impacted lower third molars. *J Phys Conf Ser.* 2018;1073:042026.
- Santos PL, Marotto AP, Zatta da Silva T, Bottura MP, Valencise M, Marques DO, et al. Is Low-Level Laser Therapy Effective for Pain Control After the Surgical Removal of Unerupted Third Molars? A Randomized Trial. *J Oral Maxillofac Surg.* 2020;78(2):184-189.
- Koparal M, Kucuk AO, Alan H, Asutay F, Avci M. Effects of low-level laser therapy following surgical extraction of the lower third molar with objective measurement of swelling using a three-dimensional system. *Exp Ther Med.* 2018;15(4):3820-3826.
- Domah F, Shah R, Nurmatov UB, Tagiyeva N. The Use of Low-Level Laser Therapy to Reduce

- Postoperative Morbidity After Third Molar Surgery: A Systematic Review and Meta-Analysis. *J Oral Maxillofac Surg.* 2021;79(2):1-19.
18. He WL, Yu FY, Li CJ, Pan J, Zhuang R, Duan PJ. A systematic review and meta-analysis on the efficacy of low-level laser therapy in the management of complication after mandibular third molar surgery. *Lasers Med Sci.* 2015;30(6):1779-1788.
19. Marković AB, Todorović L. Postoperative analgesia after lower third molar surgery: contribution of the use of long-acting local anesthetics, low-power laser, and diclofenac. *Oral Surg Oral Med Oral Pathol Oral Radiol Endod.* 2006;102(5):4-8.
20. Hamid MA. Low-level Laser Therapy on Postoperative Pain after Mandibular Third Molar Surgery. *Ann Maxillofac Surg.* 2017;7(2):207-216.
21. Aras MH, Güngörmüş M. The effect of low-level laser therapy on trismus and facial swelling following surgical extraction of a lower third molar. *Photomed Laser Surg.* 2009;27(1):21-24.