



Case Report

## The first report of the Iranian combination of tetralogy of fallot and hypertrophic cardiomyopathy; A rare case report

Feisal Rahimpour<sup>1</sup>, Reza Ghasemi<sup>2</sup>, Maryam Moradian<sup>3</sup>, Mahmood Hosseinzadeh Maleki<sup>4</sup>,  
Mohsen Yaghubi<sup>5</sup>

<sup>1</sup> Assistant Professor, Department of Pediatric Cardiology, Imam Reza Hospital, Mashhad University of Medical Sciences, Mashhad, Iran

<sup>2</sup> Assistant Professor, Department of Cardiology, 9 Day Hospital, Torbat Heydariyeh University of Medical Sciences, Torbat Heydariyeh, Iran

<sup>3</sup> Assistant Professor, Department of Pediatric Cardiology, Rajaie Cardiovascular Medical and Research Center, Iran University of Medical Sciences, Tehran, Iran

<sup>4</sup> Associated Professor, Department of Cardiac Surgery, Imam Reza Hospital, Mashhad University of Medical Sciences, Mashhad, Iran

<sup>5</sup> MSc in Extra-Corporeal Technology, Department of Extra-Corporeal Circulation (ECC), Razavi Hospital, Imam Reza International University, Mashhad, Iran

### Corresponding Author:

Tel: +989155127487

Email: [mahmoodhosseinzadeh@yahoo.com](mailto:mahmoodhosseinzadeh@yahoo.com)

### Abstract

The Tetralogy of Fallot is the most common cyanotic congenital heart disease that is often associated with chromosomal aberration had a high prevalence rate of all congenital heart diseases. The association of the Tetralogy of Fallot (ToF) with other congenital cardiac defects, especially with hypertrophic cardiomyopathy, is infrequent. While, unlike the tetralogy of Fallot, hypertrophic cardiomyopathy is accompanied by specific gene loci.

We report this scarce association in a 6-month male infant, cyanotic since birth and known with ToF, in her first hospital admission for treatment of recurring cyanotic crises. After the preliminary evaluations and the unsuccessful stenting of the patent ductus arteriosus (PDA) under an angiographic manner, he was prepared to undergo cardiac surgery to establish a modified Blalock-Taussig Shunt procedure. The patient was discharged in good condition and suggested that his parents follow up on his cardiac function after it. On follow-up at the age of three, the child had no cyanotic crises in this period.

**Keywords:** Tetralogy of Fallot, Hypertrophic Cardiomyopathy, Congenital Heart Defects

**Citation:** Rahimpour F, Ghasemi R, Moradian M, Hosseinzadeh Maleki M, Yaghubi M. The first report of the Iranian combination of tetralogy of fallot and hypertrophic cardiomyopathy; A rare case report. *J Surg Trauma.* 2022;10(4):167-171.

**Received:** February 5, 2022

**Revised:** February 28, 2022

**Accepted:** June 15, 2022

## Introduction

Concurrent with increasing life expectancy due to improvements in diagnosis and treating cardiovascular disease, congenital heart defect repair remains challenging, increasing morbidity and mortality (1, 2). Hypertrophic cardiomyopathy often occurs as a single disease and is rarely associated with other cardiac lesions (3).

On the other hand, the combination of Tetralogy of Fallot (ToF) and hypertrophic cardiomyopathy (HCM) is extremely rare in humans reported in scarce cases (4).

Herein, we have described the first case of the combination of Tetralogy of Fallot and hypertrophic cardiomyopathy in an Iranian infant.

## Case

A 6-month male infant weighing 6 kg was admitted to the emergency department with a cyanotic appearance. The primary history taking and the evaluation of the medical records revealed that he suffered from ToF. Before this admission, the parents noted that they were often referred to the pediatric heart clinic for follow-up on his condition. They had no family history of cardiovascular disease, sudden cardiac death, or congenital heart disease.

On admission, hemodynamic parameters were in the critical ranges. The infant had a blood pressure of 76/58 mmHg, heart rate of 166 beats/minute, and respiratory rate of 49 breaths/minute, and he was also in an afebrile state with an axillary temperature of 37.3. Oxygen saturation, with a finger pulse oximeter on the index finger, was 68%. Primary physical examination was also done, and mild bilateral crackles in the lower chest in auscultation were found. His fingers had mild clubbing.

Due to his critical situation, the patient was immediately transferred to the Neonates Intensive Care Unit (NICU).

Heart auscultation showed normal S1 with a single S2 that accompanied with a 3/6 grade of systolic murmur.

The laboratory evaluation showed an elevated white blood cell count (18,450 cells/ml) with neutrophilic predominance and lymphopenia (6,280 cells/ul).

Hemoglobin was 12.2 gr/dl with hematocrit 30.2%.

The portable anteroposterior chest radiography was done and showed an increased cardiothoracic ratio (CTR), marked the boot-shaped heart sign with a left-sided aortic arch. Also, pulmonary vasculature marking (PVM) was decreased (Figure 1).

Bedside transthoracic echocardiography was done and revealed ToF (overriding of Aorta, sub-aortic ventricular septal defect (VSD), right ventricular hypertrophy (RVH), severe valvular and subvalvular pulmonary stenosis) was accompanied by severe hypertrophy of left ventricular walls (interventricular septum diameter was 13mm, z score= 13) (Figure 2).

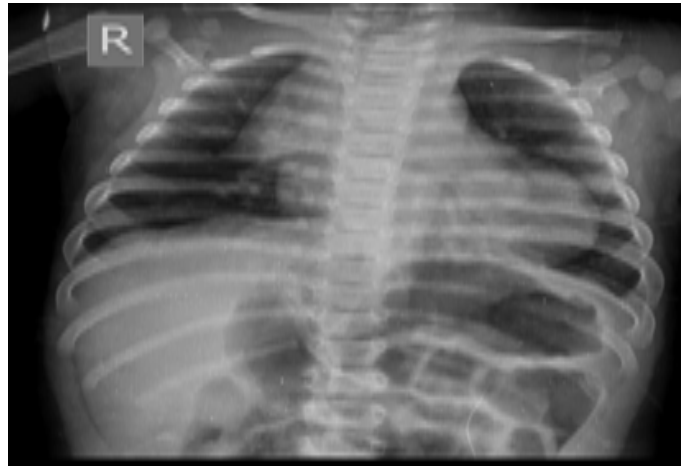
Since these findings were scarce, we decided to do more evaluation to make a good decision. So, the infant was transferred to the radiology department, and Multislice spiral CT angiography of the heart and major vascular was done. The findings showed Visceral situs solitus, levocardia, D-loop. Atrio-ventricular concordance, Pulmonary atresia, and confluent pulmonary artery branches (RPA= 10.5mm, LPA origin= 6.5mm, Hilum= 9.2mm) and vertical patent ductus arteriosus (PDA) with stenosis in origin (PDA measured 3.5mm). The aortic arch was left-sided with normal supra-aortic branches, no coarctation of the aorta (CoA) but Aneurysmal dilatation of ascending aorta (Ascending aorta= 24mm) and a Sub-aortic VSD. All pulmonary veins were connected to the left atrium, no left superior venacava(LSVC) was seen, and coronary anatomy had a normal course (Figure 3).

So, the infant was prepared to undergo angiography. We tried to stenting the PDA with this procedure that unfortunately, it was unsuccessful (Figure 4).

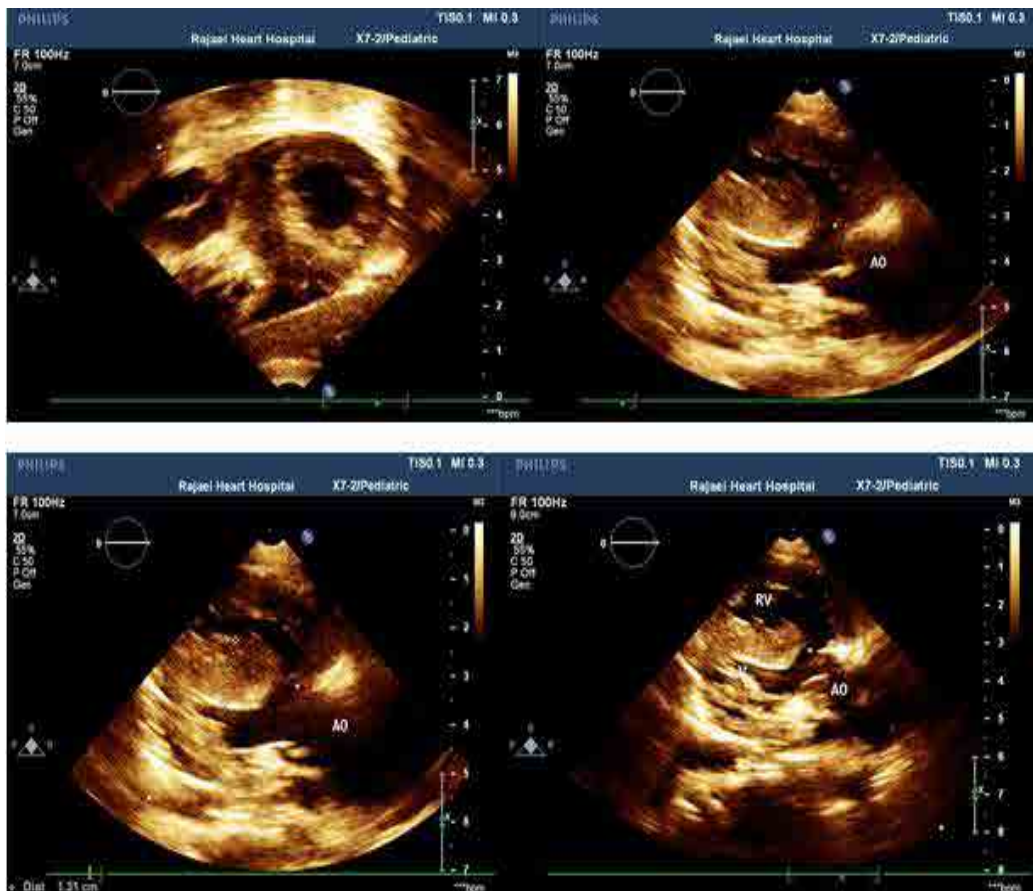Finally, the patient was prepared to undergo cardiac surgery to establish a modified Blalock-Taussig (BT) Shunt procedure. We utilize a right Gore-Tex® with size 5 mm, conduit between the right subclavian and right pulmonary artery. After this procedure, the infants were transferred to cardiac surgery ICU. After 8 hours from ICU admission, he was weaned from mechanical ventilation. Instantly, the trans-thoracic echocardiography was done, and the BT shunt was patent. After two

days from ICU admission, he was transferred to PICU to follow up on the critical care condition. The infant was discharged from the hospital five days later, in good condition. Before discharge, we recommended that his parents follow up on the patient's cardiac function and refer him to the

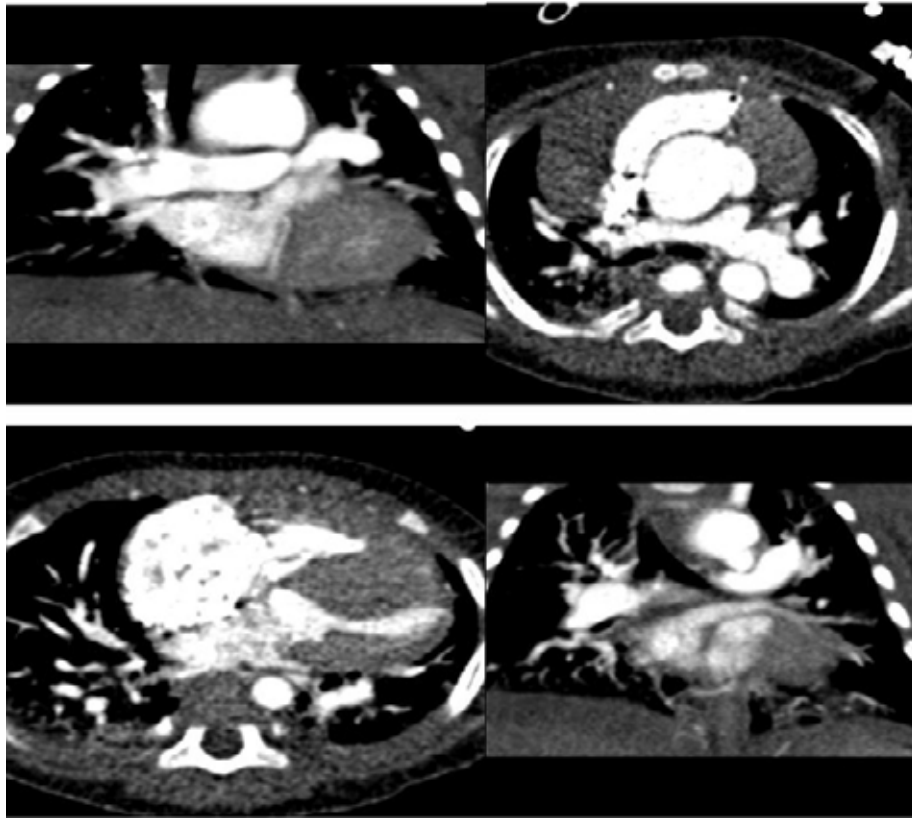
congenital heart disease department every three months. On follow-up at the age of three, the child had no cyanotic crises in this period. He was gaining weight, albeit a weight-height deficit was apparent. Also, periodic echocardiography showed that the shunt was adequate.



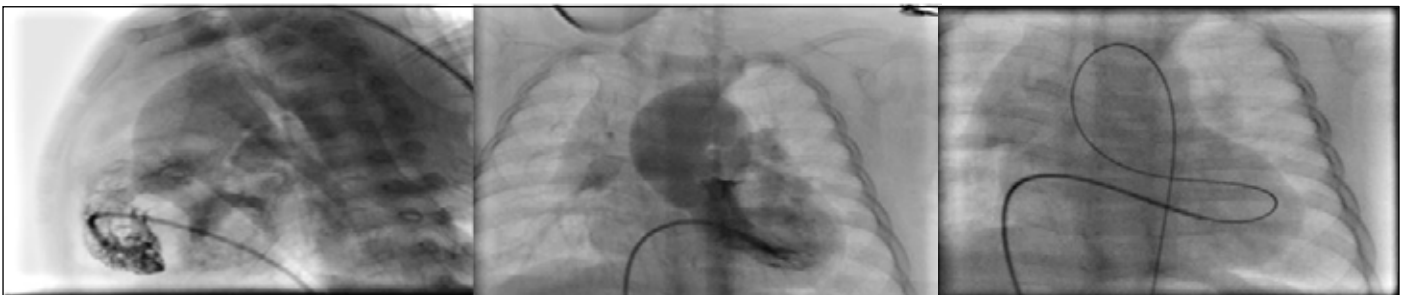
**Figure 1.** The portable AP view chest X-ray showed increased CRT with decreased PVM.



**Figure 2.** Trans-thoracic echocardiography showed typical Tetralogy of Fallot anomalies with left ventricular hypertrophy.



**Figure 3.** Chest CT angiography approved the ToF anomalies with hypertrophic cardiomyopathy.



**Figure 4.** The angiography showed pulmonary atresia, VSD, Aortic orifice overriding, and thickened IVS.

## Discussion

In a few cases, the very rare association of the ToF and hypertrophic cardiomyopathy was reported in the last four decades (5). This anomaly was diagnosed in infancy with cyanosis and congestive heart failure presentation (6). However, most of these infants died in short-term periods after total correction or palliative surgeries, the 30 months follow-up after only palliative surgery in one case showed acceptable results (5,7). In this report, our patient had a suitable condition after palliative surgery and 36 months follow-up. Also, this patient was the first Iranian infant diagnosed and reported with this anomaly.

The incidence of the HCM in the newborn stage or even in the fetus period can be due to maternal metabolic disorders, such as diabetes mellitus. Another risk factor for this disorder may be steroid exposure in the antenatal or postnatal periods (4,8). However, based on our history taking and medical records, there is no known intrauterine exposure to steroids, even a single dose, and maternal metabolic disorders; we concluded that our case had primary HCM. On the other hand, in the primary HCM, the genetic etiology was identified. Nevertheless, all of the identified genes are not responsible for all cases of HCM (8). So, the coincidence of the HCM



with other genetic diseases revealed heterogeneity in genotypic. Therefore, HCM may be associated with other genetic defects that are still unknown. This hypothesis is confirmed by other cases that reported some cardiac abnormalities with HCM (9). ToF is the most prevalent cyanotic cardiac lesion of infancy. This phenomenon seems to be familial if other congenital heart defects accompany it (2).

However, there were no familial congenital heart defects in our patient and even hospitalization due to cardiac disease. So, this fact has proven one of the rarity features of our case. Up to now, there has been no definitive successful therapy for the combination of HCM and ToF. Other researchers proposed that systemic-to-pulmonary shunt followed by chronic propranolol therapy can be considered the best therapeutic procedure (4). This procedure was conducted on our patient, and his follow-up showed this strategy could survive the same patient with a good condition. Albeit, the long-term prognosis of the patients with this therapeutic strategy is still unknown.

## Conclusion

In conclusion, the precise recognition of ToF associated with HCM is most important because the therapeutic road map should be drawn before any decisions. Also, the therapeutic approach of these patients follows a complicated surgical plan.

## Conflict of interest

The authors declare that they have no conflict of interest.

## References:

1. Younessi Heravi MA, Mojdekanlu M, Seyed

Sharifi SH, Yaghubi M. The role of cardiovascular risk factors in involvement of coronary arteries; A predictive model in angiographic study. *JNKUMS*. 2014; 6(1):199-205.

2. Ghanei Motlagh F, Ghasemi R, Nazari S, Yaghubi M. Successful pregnancy outcome in a 31 years old woman with uncorrected Tetralogy of Fallot; A case report. *JNKUMS*. 2017;8(3): 541-547.

3. A Kodliwadmth, Y Shrivastava, B Duggal ,J Cardiovasc Echogr. Heart failure in tetralogy of fallot due to associated hypertrophic obstructive cardiomyopathy: A lesson to learn. 2021; 31(1): 35–38.

4. Wheeler YY, Russo P, Carter GA, Lababidi Z, Luger AM, Tobias JD. Tetralogy of Fallot, hypertrophic cardiomyopathy, and Down's syndrome: a rare and challenging combination. *Pediatr Dev Pathol*. 2006;9(4):307-311.

5. Hsu KH, Chang CI. A rare association of tetralogy of Fallot and hypertrophic cardiomyopathy. *Eur J Cardiothorac Surg*. 2012;41(6):1390-1392.

6. Yildirim SV, Kale-Cekinmez E, Ozcan D, Derbent M. Tetralogy of Fallot and hypertrophic cardiomyopathy in a case of cardiofaciocutaneous syndrome. *Turk J Pediatr*. 2008; 50:275–277.

7. Carvalho AM, Diógenes TC, Jucá ER, Carvalho AF, Carvalho CF, Paes Júnior JN. Tetralogy of Fallot and hypertrophic cardiomyopathy: a rare association. *Arq Bras Cardiol*. 2003;80(2):217-219.

8. Kale Y, Aydemir O, Ceylan O, Bas AY, Demirel N. Hypertrophic Cardiomyopathy After a Single Dose of Dexamethasone in a Preterm Infant. *Pediatr Neonatol*. 2015;56(4):268-270.

9. Seo HS, Lee IH, Song YW, Choi BM, Jang GY, Son CS, and et al. A Case of Congenital Hypertrophic Cardiomyopathy. *Korean Circ J*. 2013;43(1):54-56.