



Case Report

## Hiccups as a rare presentation of pulmonary embolism: A case report study

Somayesadat Hoseini<sup>1</sup> , Soroush Khojasteh-Kaffash<sup>2</sup>  

<sup>1</sup> Department of Internal Medicine, School of Medicine, Birjand University of Medical Sciences, Birjand, Iran

<sup>2</sup> Student Research Committee, School of Medicine, Birjand University of Medical Sciences, Birjand, Iran

**Corresponding Author:**

Tel: +989155736174

Email: [soroushkaffash@gmail.com](mailto:soroushkaffash@gmail.com)

---

### Abstract

Pulmonary Embolism (PE) causes more than 300,000 deaths per year in the United States. Early diagnosis and treatment can significantly reduce mortality. Hiccups are involuntary spasmodic contractions in the respiratory muscles (inspiratory muscles), especially the diaphragm. Due to the importance of early diagnosis and quick treatment of PE, knowing its uncommon symptoms can help to diagnose and treat it before death. A 67-year-old man with no history of previous diseases and a history of knee joint surgery (5 years ago) came to the emergency room (ER) with continuous hiccups since 10 days ago. There were no cardiovascular risk factors such as family history, history of stroke and thromboembolism, smoking, alcohol, diabetes mellitus and hypertension. Respiratory rate (RR) was 18 breaths/minute, pulse rate (PR) was 120 beats/minute, blood pressure (BP) was 122/84 mmHg, oxygen saturation (SPO<sub>2</sub>) in the room was 96%, and body temperature (T) was 36 °C. He was a candidate for computed tomography angiography (CTA). The filling defect was observed in the distal peripheral of the left main pulmonary artery (LMPA), with extension to the left upper lobe (LUL), left lower lobe (LLL), and segmental branches. After 6 days of hospitalization, with the improvement of symptoms and stability of vital signs, he was discharged with medications. Due to the association of hiccups with dangerous diseases, it is important to investigate continuous and long hiccups.

**Keywords:** Hiccup, Pulmonary Embolism, Thromboembolisms

---

**Citation:** Hoseini S, Khojasteh-Kaffash S. Hiccups as a rare presentation of pulmonary embolism: A case report study. *J Surg Trauma*. 2022;10(4):172-176.

*Received: July 30, 2022*

*Revised: August 1, 2022*

*Accepted: August 17, 2022*

---

## Introduction

Venous thromboembolism (VTE) is known as the third most common cause of cardiovascular syndromes (1). VTE has two forms, deep vein thrombosis (DVT) and pulmonary embolism (PE). The incidence of PE in different communities is 39-115 per 100,000 populations (2). According to studies, the risk of vascular syndromes, including PE, increases with age (2). PE causes more than 300,000 deaths per year in the United States and is recognized as one of the leading causes of cardiovascular mortality (2).

Due to the challenge of diagnosing PE and its high mortality rate, early diagnosis and treatment can significantly reduce mortality. According to previous studies, the death rate due to PE was 34%, and only 7% of cases were diagnosed and treated before death (3).

Hiccups are involuntary spasmodic contractions in the respiratory muscles (inspiratory muscles), especially the diaphragm (4, 5).

This reflex is caused by the afferent nerve trunk (including the phrenic, vagus, sympathetic nerves T6-10 and a center in the brainstem) and efferent (including the phrenic nerve) (6).

Any irritant, such as inflammation, trauma, drugs, or excessive expansion of the serosa, which causes irritation of the efferent and afferent nerve trunks, can cause hiccups (7). Due to the importance of early diagnosis and quick treatment of PE, knowing its uncommon symptoms can help to diagnose and treat it before death.

## Case

A 67-year-old man with no history of previous diseases and a history of knee joint surgery (5 years ago) came to the emergency room (ER) with continuous hiccups since 10 days ago. He had no history of cardiovascular, respiratory (except silent asthma), gastrointestinal and neurological diseases. The patient had no medical history and was not taking any medication.

There were no cardiovascular risk factors such as family history, history of stroke and thromboembolism, smoking, alcohol, diabetes

mellitus, and hypertension.

The onset of symptoms after spraying the farm was fever and chills. He complained of anorexia, weakness and lethargy, and progressive shortness of breath during the last days.

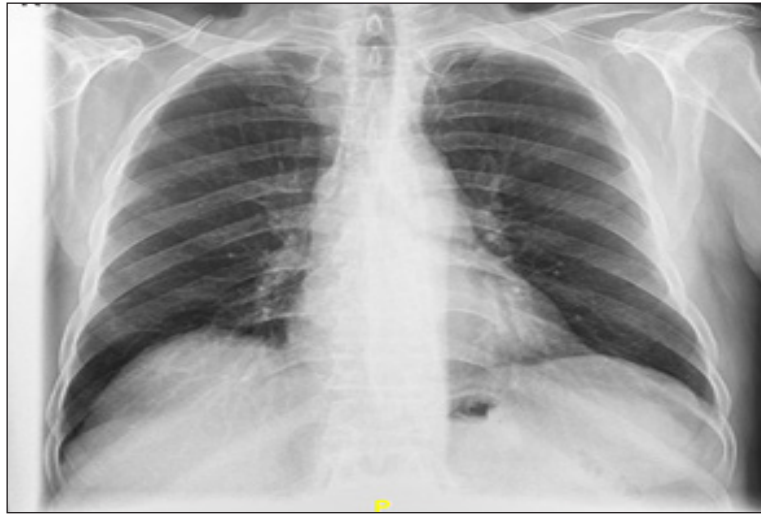He did not complain of limb edema, dizziness, abdominal pain, or chest pain. In physical examination, respiratory rate (RR) was 18 breaths/minute, pulse rate (PR) was 120 beats/minute, blood pressure (BP) was 122/84 mmHg, oxygen saturation (SPO<sub>2</sub>) in the room was 96%, and body temperature (T) was 36 °C. Heart Auscultation was without murmurs and the lungs were clean and normal. Based on the history, clinical symptoms, and physical examination, the wells criteria were checked for the patient and according to the score of 1.5, the patient was placed in the low-risk group of PE.

The Electrocardiogram (ECG) showed sinus tachycardia and ST depression in the inferior leads. In the chest x-ray (CXR), normal cardiothoracic ratio CTR, open costophrenic angle, and no consolidation were observed (Figure 1). After rolling out the differential diagnoses, the wells criteria were recalculated and with a score of 4.5 and according to the medium PE risk, he was a candidate for Computed Tomography Angiography (CTA).

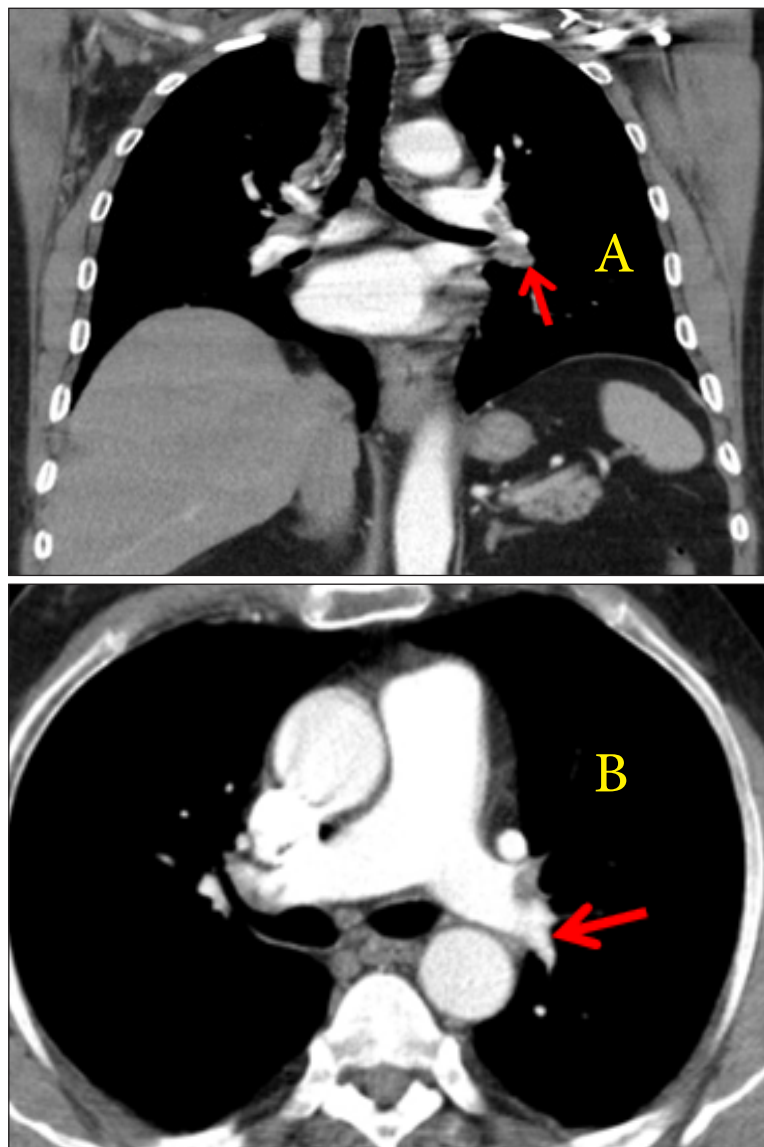
In CTA, the filling defect was observed in the distal peripheral of the left main pulmonary artery (LMPA), with extension to the left upper lobe (LUL), left lower lobe (LLL), and segmental branches (Figure 2).

Based on this, the patient was diagnosed with PE. Diagnostic tests include complete blood count (CBC), arterial blood gas (ABG), and COVID-19 PCR, electrolytes, prothrombin time (PT), partial thromboplastin time (PTT), international normalized ratio (INR), and cardiac troponin test were performed. All the mentioned tests were normal, but only the PTT was high at admission, which decreased on the last day of hospitalization.

After 6 days of hospitalization, with the improvement of symptoms and stability of vital signs, he was discharged with the prescription of anti-coagulants including heparin, aspirin, and clopidogrel (Plavix).



**Figure 1.** Chest X-ray (CXR) with normal cardiothoracic ratio (CTR), open costophrenic angle, and no consolidation.



**Figure 2.** A. Computed tomography angiography (CTA) in coronal section showing an embolus in distal peripheral of the left main pulmonary artery (LMPA) with extension to left upper lobe (LUL), left lower lobe (LLL) (filling defect, red arrow). B. CTA in axial view showing an embolus in distal peripheral of the left main pulmonary artery (LMPA) (filling defect, red arrow).

## Discussion

Due the importance of early diagnosis and treatment of PE, the use of diagnostic methods is important. Important risk factors for PE include history of lower limb fracture, history of myocardial infarction (in the last 3 months), history of surgery and trauma, cancer, smoking, oral contraceptive pills (OCP), hospitalization due to heart failure (fibrillation or flutter), and arthroplasty of the knee joint (8). In order to diagnose PE, the risk is first calculated based on the wells criteria, and then based on the result, if the risk is high and there is a high clinical probability of PE, the patient undergoes CTA. In case of low clinical probability, d-dimer is first checked for the patient and if it is below 500 ng/ml, PE is ruled out; otherwise the final diagnosis will be based on CTA as the gold standard (8). The most common clinical symptoms of PE include sudden dyspnea at rest and activity (73%), pleuritic chest pain (44%), restlessness, dry cough (34%), dizziness, lower extremity edema, palpitations, and sweating (9, 10). One of the main causes of death in PE patients is late diagnosis due to asymptomatic or non-specific symptoms. Generally, CXR and EKG should be performed for all patients who refer to the ER. If there is a clinical suspicion of PE, vascular doppler ultrasound (to check lower limb DVT), ventilation/perfusion scan (VQ scan) and CTA can be used (8). Corticosteroid drugs, dopamine, azithromycin and benzodiazepine, gastrointestinal diseases such as gastroesophageal reflux disease (GERD), esophagitis and gastric volvulus, cardiovascular diseases such as myocardial infarction and neurological diseases such as tumors or vascular abnormalities can cause hiccup reflex (11). PE can also rarely cause hiccups by stimulating the efferent and afferent trunks, the mechanism of which is not clearly known (12). Due to the high prevalence of idiopathic hiccups, if the hiccups are persistent and prolonged, due to its association with neurological diseases, myocardial infarction and PE should be investigated.

## Conclusion

In conclusion, due to the importance of early diagnosis and treatment of PE in its prognosis,

recognition of various symptoms in patients can be helpful. The use of existing criteria to check and evaluate the risk of PE and the use of diagnostic tests can greatly help in its correct diagnosis. CTA can still be mentioned as the most accurate method for diagnosing PE. Also, due to the association of hiccups with dangerous diseases, it is important to investigate continuous and long hiccups.

## Conflict of interest

The authors declare that they have no conflict of interest.

## References:

1. Raskob GE, Angehaisuksiri P, Blanco AN, Buller H, Gallus A, Hunt BJ, et al. Thrombosis: a major contributor to global disease burden. *Arterioscler Thromb Vasc Biol.* 2014;34(11):2363-2371.
2. Wendelboe AM, Raskob GE. Global burden of thrombosis: epidemiologic aspects. *Circ Res.* 2016;118(9):1340-1347.
3. Cohen A, Cohen AT, Agnelli G, Anderson FA, Arcelus JI, Bergqvist D, Brecht JG, et al. *Thromb Haemost.* 2007;98:756-764.
4. Marai I, Levi Y. [The diverse etiology of hiccups]. *Harefuah.* 2003;142(1):10-13.
5. Gigot AF, Flynn PD. Treatment of hiccups. *JAMA.* 1952;150(8):760-764.
6. Souadjian JV, Cain JC. Intractable hiccup, Etiologic factors in 220 cases. *Postgrad Med.* 1968;43(2):72-77.
7. Loft LM, Ward RF. Hiccups: a case presentation and etiologic review. *Arch Otolaryngol Head Neck Surg.* 1992;118(10):1115-1119.
8. Konstantinides SV, Meyer G, Becattini C, Bueno H, Geersing GJ, Harjola VP, et al. 2019 ESC Guidelines for the diagnosis and management of acute pulmonary embolism developed in collaboration with the European Respiratory Society (ERS). *Eur Heart J.* 2020;41(4):543-603.
9. Courtney DM, Kline JA, Kabrhel C, Moore CL, Smithline HA, Nordenholz KE, et al. Clinical features from the history and physical examination that predict the presence or absence of pulmonary embolism in symptomatic emergency department

patients: results of a prospective, multicenter study. *Ann Emerg Med.* 2010;55(4):307-315.

10. Hassen GW, Singh MM, Kalantari H, Yemane-Merriwether S, Ferrante S, Shaw R. Persistent hiccups as a rare presenting symptom of pulmonary embolism. *West J Emerg Med.* 2012;13(6):479-483.

11. Errante D, Bernardi D, Bianco A, Zanatta N,

Salvagno L. Recurrence of exhausting hiccup in a patient treated with chemotherapy for metastatic colon cancer. *Gut.* 2005;54(10):1503-1504.

12. Payne BR, Tiel RL, Payne MS, Fisch B. Vagus nerve stimulation for chronic intractable hiccups: case report. *Journal of neurosurgery.* 2005;102(5):935-937.