



Original Article

Comparison of topical azithromycin ophthalmic solution 1% and erythromycin eye ointment on the posterior blepharitis

Seyed Abbas Hosseinirad¹  , Malihe Nikandish² , Armin Forghani³ 

¹ Assistant Professor, Department of Ophthalmology, Birjand University of Medical Sciences, Birjand, Iran, Birjand, Iran
² Associate Professor, Department of Ophthalmology, School of Medicine Cellular and Molecular Research Center, Birjand University of Medical Sciences, Birjand, Iran
³ Student Research Committee, School of Medicine, Birjand University of Medical Sciences, Birjand, Iran

Corresponding Author:

Tel: +989151615021

Email: Hosseinirad@bums.ac.ir

Abstract

Introduction: Posterior blepharitis is one of the most common eye diseases that involve eyelashes, sebaceous and apocrine glands. The most important symptoms of blepharitis are burning and irritation of the eyes, which are more severe in the morning. Azithromycin 1% solution is a new therapeutic method for treating blepharitis, which has recently entered Iran. The purpose of this study was to compare the treatment of 1% azithromycin eye drops and erythromycin topical ointment on the symptoms and signs of blepharitis.

Methods: In this clinical trial study, 98 patients with posterior blepharitis referred to the ophthalmology clinic of Razi Hospital in Birjand on March 2020 up to October 2021 were studied based on inclusion and exclusion criteria. Patients were randomly divided into two groups receiving erythromycin and 1% azithromycin by the blocking method. A two-part questionnaire was completed for the patients before and after the intervention. In the first part of the questionnaire, the demographic information of the patients and the signs and symptoms of the disease, including the degree of dry eyes, redness and swelling of the eyes, itchy eyes, and in the second part, the standard Ocular Surface Disease Index questionnaire was completed by self-declaration. The SMTube test was also performed by the project manager for the patients. The intensity of color sensitivity was checked and recorded by an eye specialist. After collecting the data, they were entered into SPSS software (Version 18) and analyzed by independent, Mann-Whitney, paired t, Chi-Square and Fisher's exact test at the significance level less than (5%).

Results: Out of a total of 98 patients, 52 patients (53.1%) were female. At the beginning of the study, there was no significant difference between the average Ocular Surface Disease Index(OSDI), staining intensity and SMTube, and at the end of the study, there was no significant difference between the two groups ($P>0.05$).

Conclusion: Based on the results of the present study, the efficacy of azithromycin eye drops in the patients was the same as the efficacy of topical erythromycin ointment in patients with posterior blepharitis.

Keywords: Blepharitis, Azithromycin, Eye Drops

Citation: Hosseinirad S.A, Nikandish M, Forghani A. Comparison of topical azithromycin ophthalmic solution 1% and erythromycin eye ointment on the posterior blepharitis. *J Surg Trauma*.2022;10(4):128-136.

Received: October 16, 2022

Revised: November 20, 2022

Accepted: November 20, 2022

Introduction

Blepharitis is a common and chronic inflammation of the eyelid which is one of the most common eye diseases in clinics. This disease affects eyelashes, and sebaceous and apocrine glands (1). The spread of the disease is due to mild blepharitis, which is the only symptom, and the cases where patients refer to other causes are reported lower than the actual value (2). Some studies have stated that 37% of patients visited by ophthalmologists are patients with blepharitis (3). 41% of patients are diagnosed with dry eye, 16% of cases are identified for evaluation of eye surgery and 6% are identified in periodic examinations. It is estimated that 33% of patients need cataract surgery; they also suffer from blepharitis (3). Blepharitis is divided into two categories, infectious and non-infectious, based on the type of agent, and based on the location of the lesion, it is divided into posterior and anterior types (3,4). Obstruction of meibomian gland may cause chalazion, which in turn warrants surgical intervention (5).

The most important clinical symptom of blepharitis is the irritation of the eyes, which is more severe in the early morning. Other symptoms of the disease include itching and irritation of the eyelids, discomfort in the eyes after working on the computer, feeling of heaviness in the eyelids, the presence of secretions on the eyelashes, feeling of dryness in the eyes, sticking of the eyelids when waking up, and also eye redness indicated (6). The first stage of disease treatment is the complete explanation of the disease to the affected person and his/her lack of awareness of the course of the disease and its possible complications if not properly treated. We should also talk about the fact that chronic blepharitis does not have a definite cure and the treatment continues for years and sometimes until the end of life. The goal of treating blepharitis is to reduce the patient's symptoms, improve the function of the meibomian glands, and reduce inflammation (3,7).

Currently, traditionally, washing and warm compressing of the eyelids are the main treatment

for blepharitis, but the desire to use the medicine, especially new eye medicines, is also increasing. Maintaining the hygiene of the eyelids has a limited role in the treatment of this disease (6,8). Ophthalmologists' tendency to use medicine to treat blepharitis includes 1% eye solution of azithromycin and oral doxycycline, then anti-inflammatory agents such as cyclosporine, loteprednol etabonate, and a combination of dexamethasone and tobramycin. Also, the use of bacitracin ointment, erythromycin, and sometimes fluoroquinolones is also prescribed to treat the disease (6). Azithromycin 1% drops is a new therapeutic method for the treatment of blepharitis in patients, which has recently been produced in Iran (4). This medicine, like our erythromycin and doxycycline, has anti-inflammatory effects, which, after being used by patients, leads to the improvement of symptoms and signs of the disease (4). Considering that the studies conducted regarding the efficacy of 1% azithromycin drops were low, the purpose of this study was to investigate the effect of 1% azithromycin treatment on the symptoms and signs of blepharitis.

Materials and Methods

This clinical trial study was conducted after receiving permission from the ethics committee (IR.BUMS.REC.1399.532) of Birjand University of Medical Sciences in the Iranian clinical trial system to obtain the IRCT code under registration number (IRCT20 1906 18043034N9). Also, the administrative steps of the study were carried out at Birjand University of Medical Sciences (Razi Hospital). Informed consent was obtained from all the participants. The studied population was 98 patients with posterior blepharitis who were referred to the ophthalmology clinic on March 2020 up to October 2021. Inclusion criteria were patients with posterior blepharitis between the ages of 18 and 80, people with telangiectasia, low OSD, and low SMTube, and Exclusion criteria were eye injuries and infections, non-dry eye inflammation, surgery, and eye trauma in the last 6 months. The sample size

was calculated using the study of Optiz et al. and the following formula (10). By using this formula, the sample size was equal to 45 people in each group, and the possibility of reducing people in the study 8%, 49 people increased, thus the total number of 98 people was calculated. At first, the implementation method and study objectives were explained to the patients and informed consent was obtained from the patients. Patients with blepharitis were divided into two groups receiving 1% azithromycin (Group A) and topical erythromycin ointment (Group B) by simple randomization and block method. The patients with the above conditions were divided into two groups by simple randomization and by the block method (blocks of four) into one of the two intervention groups with control. In this way, first, various blocks of four were created (ABAB, BBAA, AABB, BABA, ABBA, BABA). Randomly one of these blocks was selected and the patients were divided into one of the two groups A and B and then randomization was done for the other patients as well. The ophthalmologist did not know the placement of the patients in each of the studies, and only the study manager knew about the patient groups (single-blind study). To diagnose blepharitis, patients were examined by an ophthalmologist using a slit lamp and clinical criteria for blepharitis.

Patients were given topical azithromycin eye drops 2 times a day for 4 days, then once a day for 4 weeks. Then the patients took the necessary care for 4 weeks, including washing their eyes with shampoo, and then went to the doctor's office. Patients in the control group received erythromycin eye ointment once every night for 4 weeks along with eye health care, and then these patients visited by an ophthalmologist. The SMTube test and the Ocular Surface Disease Index questionnaire were completed for the patients.

A two-part questionnaire was used in this study. In the first part of this questionnaire, information was received from the patients, based on the objectives of the study, including the symptoms of the disease, such as the degree of dry eyes, redness and swelling of the eyes, and itching of the eyes.

Also, the demographic information of the patients including age, gender, education level, previous disease history, and place of residence was also recorded. Then, in the second part, the standard Ocular Surface Disease Index questionnaire was completed by self-report for each patient at the beginning of the visit and after treatment with 1% azithromycin and erythromycin topical ointment.

This questionnaire has 3 sections including:

1. Clinical symptoms experienced by the patient in the last week.
2. Clinical symptoms that have limited the patient's activities.
3. Uncontrollable clinical symptoms, each section containing 4 questions (12 questions in total) were scored on a Likert scale (never: 0 / always: 4).

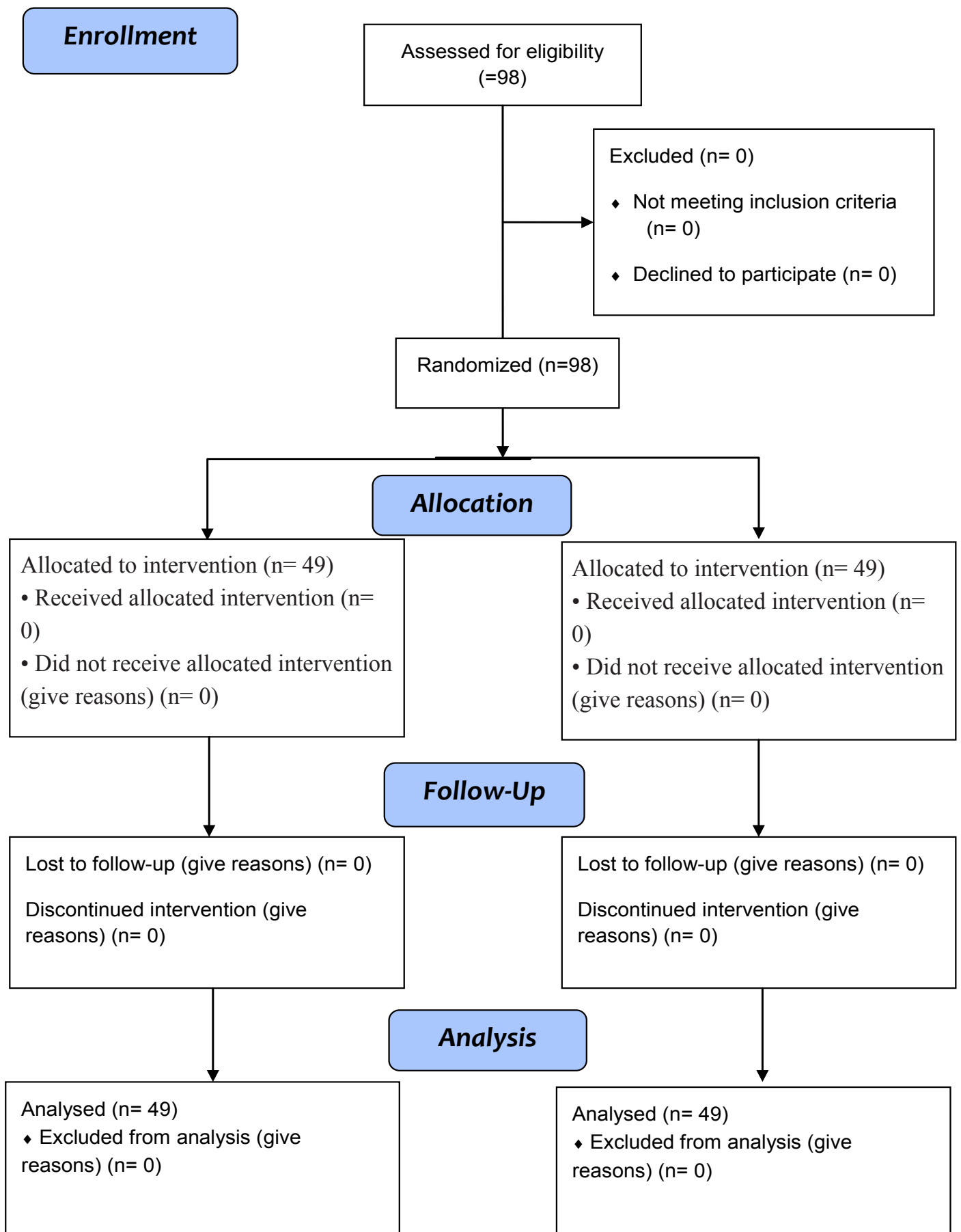
The minimum and maximum score of the questionnaire varies between 0 and 100. The score of the questionnaire is calculated as follows:

- 25 points from a total of 12 questions
- The score is 0-12 normal, 13-22 mild, 23-32 moderate, and 33-100 severe

The original version of the (OSDI) questionnaire was confirmed in the study conducted by Optiz et al. (10). Also, the Persian version of this questionnaire has been confirmed in the study conducted by Javadi et al. (3). Also, the SMTube test was performed by the project manager for the patients, and the results were checked and recorded by an ophthalmologist. In this test, if the paper gets wet under 10 mm within 5 seconds, the person has dry eyes. Also, the patient's staining intensity was measured by fluorescein paper by the study administrator at the beginning and end of the study. The Oxford recipe was used to perform and interpret the dye intensity test.

After completing the questionnaire, the data was entered into SPSS software (Version 18). Shapiro test was used to check normality. Mann-Whitney test, independent t-test and paired t-test were used to analyze the data. Chi-Square test and Fisher's exact test were also used for qualitative variables. The significance level in this study was considered to be less than ($P < 0.05$).

The CONSORT Flow Diagram



Results

A total of 98 patients with posterior blepharitis participated in this study. No participant was lost due to withdrawal or protocol deviation. There was

no significant difference in baseline characteristics in both intervention (Azithromycin) and control groups (Erythromycin) ($P < 0.05$), as shown in (Table 1).

Table 1: Comparing the average age and frequency distribution of gender of patients in the two studied groups

The parameters of the studied groups	Age Mean±SD	Female	Male
		N(%)	N (%)
Azithromycin	41/5± 18/1	28 (57/1)	21 (42/9)
Erythromycin	38/8± 16/7	24(49)	25(51)
Result	*P=0.433	**P=0.544	

* Independent T-test

** A feeling of heaviness in the eyelid

The mean of (OSDI) index at the beginning and end of the study was not significantly different between the two groups ($P < 0.05$). The changes before and after the index were significant in both groups ($P < 0.001$), but the mean score staining intensity at the end of the study in the group receiving azithromycin significantly decreased compared to the group receiving erythromycin ($P = 0.049$). Also, the mean staining intensity at the end of the study

in both groups was significantly reduced compared to the beginning of the study ($P < 0.001$). The mean of the SM Tube test at the beginning and end of the study was not significantly different between the two investigated groups ($P < 0.05$). The mean score of SM Tube in the erythromycin and azithromycin group increased significantly at the end of the study compared to the beginning of the study ($P < 0.05$). (Table. 2).

Table 2. Comparing the mean OSDI before and after the intervention between the two investigated groups

The parameters of the studied groups	Erythromycin Mean± SD	Azithromycin Mean± SD	P-value
OSDI at the beginning of the study	32/2 ± 10/8	32/7 ± 10/1	P=0.817*
OSDI at the end of study	16/1 ± 7/6	14/5 ± 8/3	P=0.314*
The result of Wilcoxon statistical test	P<0.001	P<0.001	-----
staining intensity at the beginning of the study	3/6 ± 1/1	3/9 ± 1/1	P=0.332
staining intensity at the end of study	1/9 ± 0/84	1/5 ± 0/74	P=0.049
The result of the paired t- test	P<0.001	P<0.001	
SMTube at the beginning of the study	11/4 ± 3/6	11/1 ± 2/8	P=0.589
SMTube at the end of study	13/7 ± 6/1	13/1 ± 5/2	P=0.532
The result of Wilcoxon statistical test	P=0.021	P=0.021	----

* Mann-Whitney statistical Test

The most common complaints among patients were dry eyes, eye discomfort, secretions, and eye irritation, respectively.

symptoms based on Fisher's exact test at the beginning and end of the study was not significantly different between the two studied groups ($P < 0.05$) (Table 3).

Although the frequency distribution of eye

Table 3. Comparison of the frequency distribution of disease symptoms before and after treatment between the two investigated groups

Disease Symptoms	Evaluation Time	Azithromycin N (%)	Erythromycin N (%)	The result of Chi-Square statistical test
Eye Irritation	Before intervention	4(100)	4(80)	*P= 1.000
	After intervention	0(0)	1(20)	*P= 1.000
Itching and burning eyelids	Before intervention	4(100)	2(66/67)	*P= 0.678
	After intervention	0(0)	1(33/33)	*P= 1.000
Discomfort after working with the computer	Before intervention	6(75)	5(62/5)	P= 1.000
	After intervention	2(25)	3(37/5)	*P= 1.000
feeling of heaviness in the eyelid	Before intervention	2(100)	0(0)	*P= 0.495
	After intervention	0(0)	0(0)	-----
The presence of secretions on the eyelashes	Before intervention	5(83/3)	4(66/7)	* P= 1.000
	After intervention	1(16/7)	2(33/3)	* P= 1.000
feeling of dryness in the eyes	Before intervention	15(100)	14(77/8)	P= 1.000
	After intervention	0(0)	4(22/2)	P= 0.117
Sticking of the eyelids when waking up	Before intervention	5(100)	4(66/7)	P= 1.000
	After intervention	0(0)	2(33/3)	* P= 0.495
Eye redness	Before intervention	4(100)	2(66/7)	* P= 1.000
	After intervention	0(0)	1(33/3)	* P= 1.000

* Fisher's exact statistical test

Discussion

There was no significant difference between the two groups in the mean of OSDI index at the beginning and end of the study. Based on the results of paired t-test, the changes before and after the index were significant in both groups. The average score of eye symptoms in patients receiving azithromycin and standard treatment significantly decreased compared to the beginning of the study. So that the average number of eye symptoms decreased significantly from 7.2 and 2.9 to 1.5 and 1.3 respectively. which was consistent with our study. Optiz et al. (2011) stated that

the mean score of ocular symptoms in patients receiving azithromycin was significantly reduced, which was also consistent with our study (10). Although the distribution of the frequency of eye symptoms based on the results of Fisher's post hoc test at the beginning and end of the study was not significantly different between the two groups under investigation. In the study conducted by Igami et al. (2011), it was stated that eye symptoms in patients receiving oral azithromycin significantly decreased, so that this decrease in all symptoms was 1.5 points (12). This part was not consistent with the study done by us. Among the reasons for

this inconsistency, we can mention the difference in the method of receiving treatment. In the study conducted by Luchs (2009) and Haque et al. (2010), it was stated that a significant improvement was observed in the function of meibomian glands and eye redness compared to the group receiving hot water compress (13, 14).

Prior studies have sought to examine the efficacy of Azithromycin eyedrops for MGD-associated posterior blepharitis. Arita et al. reported a significant improve in lid margin vascularity, tear osmolarity, Noninvasive break-up time of the tear film, fluorescein-based break-up time of the tear film, and meibum grade following Azithromycin treatment compared with preservative-free artificial tear (15).

In the study conducted by Zandian et al. (2015), it was stated that the distribution of the frequency of eye symptoms in patients receiving doxycycline (the mean score decreased from 1.2 to 0.24) and azithromycin (0.96 to 0.32) decreased. Which was significantly different from each other ($P<0.05$)(16). This part was not consistent with the study done by us. Among the reasons for this inconsistency, he pointed out the difference in the method of receiving treatment. According to the results of the present study, the average of staining intensity at the beginning of the study was not significantly different between the two groups ($P<0.05$), but the average of staining intensity at the end of the study in the group receiving azithromycin significantly decreased compared to the group receiving erythromycin ($P=0.09$).

Also, the average of staining intensity at the end of the study in both groups was significantly reduced compared to the beginning of the study ($P=0.09$). In the study conducted by Igami et al., 2011, it was stated that the results of the fluorescein staining test after injection in the group receiving azithromycin did not have a significant difference (12). this part was not consistent with the study conducted by us. So that the average staining intensity increased, but these changes were not significant). Among the reasons for this lack of reading, we can mention

the difference in the treatment method. In the study conducted by Optiz et al. (2011), it was stated that the average of staining intensity of corneal in patients receiving azithromycin was significantly reduced ($P<0.05$) and it was consistent with our studies. The mean of the SM Tube test at the beginning and end of the study was not significantly different between the two investigated groups ($P<0.05$) (10). The average score of SMTube in the erythromycin and azithromycin group increased significantly at the end of the study compared to the beginning of the study ($P<0.05$). In the study conducted by Igami et al. (2011), it was stated that the results of the TFBUT test in the group receiving azithromycin significantly increased tissue ($P<0.05$), which was consistent with the study conducted by us (12). Considering that for the treatment of blepharitis, erythromycin topical ointment is used for patients, and on the other hand, blepharitis is a disease related to the eyelid margins and meibomian glands, the effectiveness of the topical ointment is suitable for the treatment of this disease. Considering that azithromycin eye drops is a new drug for the treatment of blepharitis, despite the fact that this drug is an eye drop, it had a suitable and acceptable effect as erythromycin. Azithromycin is a nitrogen-containing broad-spectrum antibiotic that also has a macrolide ring.

Antibiotic azithromycin is effective against gram-positive, gram-negative, chlamydia, etc. This antibiotic has antibacterial properties due to inhibiting bacterial protein synthesis by binding to the 50 S ribosomal subunit of sensitive microorganisms. Also, this drug has a pharmacokinetic property that one or two doses per day will be useful for patients.

This drug is used in ophthalmology to treat conjunctivitis in adults, which was approved by the CDC over time to treat blepharitis (4). Antibiotic azithromycin is available for the treatment of systemic infections, which has anti-inflammatory properties. Various studies have stated that azithromycin inhibits pro-inflammatory cytokine products and metalloproteinase products (16).

Blepharitis is a common eye disease, but there is no standard treatment for the disease. Anterior blepharitis is an infection of the eyelid margin by Gram-positive bacteria. Treatment options usually include topical erythromycin, personal hygiene, use of warm compress and commercial scrubs (4).

Posterior treatment can be treated by removing the crusts and opening the meibomian glands. Also, the use of warm compress, topical and oral antibiotics to eliminate the anti-inflammatory effects are among its treatments. Topical corticosteroids are used for severe symptoms in patients, which lead to recovery in the short term, but do not treat the pathophysiology of the disease.

There were no special limitations in this study, except that access to some patients in distant cities was difficult.

Conclusion

Based on the results of the present study, the effectiveness of azithromycin eye drops in the studied patients was as high as the effectiveness of erythromycin topical ointment in patients with posterior blepharitis.

Acknowledgments

Thanks to everyone who contributed to this article. We also Thank Ms. Malaki Moghadam for her statistical cooperation in this article.

Funding

None.

Conflicts of interest

The authors declare that there is no conflict of interest.

References

1. Bernardes TF, Bonfioli AA. Blepharitis. In *Seminars in ophthalmology*. 2010;25(3):79-83.
2. Driver PJ, Lemp MA. Meibomian gland dysfunction. *Surv Ophthalmol*. 1996;40(5):343-367.
3. Javadi M, Feizi S. Blepharitis. *Bina*. 2011;16(2):142-158.[Persian]
4. Luchs J. Azithromycin in DuraSite for the treatment of blepharitis. *Clin Ophthalmol*. 2010;4:681-688.
5. Kim E, Afshin EE, Elahi E. The Lowly Chalazion. *Surv Ophthalmol*. 2022;(22):154. doi: 10.1016/j.survophthal.2022.11.002. Epub ahead of print. PMID: 36395826.
6. Bowman RW, Miller KN, McCulley JP. Diagnosis and treatment of chronic blepharitis. *Focal Points: Clinical Modules for Ophthalmologists*. American Academy of Ophthalmology. San Francisco. 1989.
7. Foulks GN, Bron AJ. Meibomian gland dysfunction: a clinical scheme for description, diagnosis, classification, and grading. *Ocul Surf*. 2003;1(3):107-126.
8. Dougherty JM, McCulley JP, Silvany RE, Meyer DR. The role of tetracycline in chronic blepharitis. Inhibition of lipase production in staphylococci. *Invest Ophthalmol Vis Sci*. 1991;32(11):2970-2975.
9. Jackson WB. Blepharitis: current strategies for diagnosis and management. *Can J Ophthalmol*. 2008;43(2):170-179.
10. Opitz DL, Tyler KF. Efficacy of azithromycin 1% ophthalmic solution for treatment of ocular surface disease from posterior blepharitis. *Clin Exp Optom*. 2011;94(2):200-206.
11. Fadlallah A, Rami HE, Fahd D, Dunia I, Bejjani R, Chlela E, et al. Azithromycin 1.5% ophthalmic solution: efficacy and treatment modalities in chronic blepharitis. *Arq Bras Oftalmol*. 2012;75:(1):78-82.
12. Igami TZ, Holzchuh R, Osaki TH, Santo RM, Kara-Jose N, Hida RY. Oral azithromycin for treatment of posterior blepharitis. *Cornea*. 2011;30(10):1145-1499.
13. Luchs J. Efficacy of topical azithromycin ophthalmic solution 1% in the treatment of posterior blepharitis. *Adv Ther*. 2008;25(9):858-870.
14. Haque RM, Torkildsen GI, Brubaker K, Zink RC, Kowalski RP, Mah FS, et al. Multicenter openlabel study evaluating the efficacy of

azithromycin ophthalmic solution 1% on the signs and symptoms of subjects with blepharitis. *Cornea*. 2010;29(8):871-817.

15. Zandian M, Soheilifar S. Comparison of therapeutic effects of topical azithromycin solution and systemic doxycycline on posterior blepharitis.

Int J Ophthalmol. 2016;9(7):1016-1019.[Persian]
16. Lanaro A, Lalen A, Maffia P, Sautebin L, Rombola L, Carnuccio R, et al. Anti-inflammatory macrolide antibiotics. *J Pharmacol Exp Ther*. 2000;292(1):156-63.