



Case Report

## A cause of postmenopausal vaginal bleeding and severe anemia: vaginal leech infestation

Vajihe Hazari  <sup>1</sup>, Nazanin Sedghi<sup>2</sup>

<sup>1</sup> Department of Gynecology and Obstetrics, Faculty of Medicine, Birjand University of Medical Sciences, Rooyesh Infertility Center, Birjand, Iran

<sup>2</sup> Student Research Committee, School of Medicine, Birjand University of Medical Sciences, Birjand, Iran

**Corresponding Author:**

Tel: +989153611879

Email: [dr.vhazari@gmail.com](mailto:dr.vhazari@gmail.com)

### Abstract

Poor rural residents who drink leech-contaminated water are more likely to get human leeches. Atrophic endometrium, carcinoma, and other atypical postmenopausal vaginal bleeding causes must be diagnosed and treated immediately. Postmenopausal women may die from this. This paper describes the leech-induced atypical vaginal bleeding of a 72-year-old postmenopausal woman with six days of bleeding and weakness. Her medical history includes a year of tinnitus, three months of dizziness, and true vertigo. Anemia, weakness, and a low hemoglobin level (7.1 mg/dL) resulted from postmenopausal vaginal bleeding. She was transfused with one unit of whole blood and one liter of crystalloid, and she was admitted to a public referral hospital's gynecology ward. The vaginal leech was surgically removed. The patient was discharged five days after the leech was removed. Vaginal bleeding due to leech infestation is a very uncommon but important gynecological problem.

**Key words:** Leech, Postmenopausal, Vaginal Bleeding, Anemia

**Citation:** Hazari V, Sedghi N. A Cause of Postmenopausal Vaginal Bleeding and Severe Anemia: Vaginal Leech Infestation. *J Surg Trauma.*2023;11(4):167-171.

*Received: May 8, 2024*

*Revised: June 14, 2024*

*Accepted: June 23, 2024*

### Introduction

Leeches are segmented-bodied, hematophagous worms that are parasitic on both humans and other animals (1). Leeches feed on the blood of their hosts. Leeches feed on human blood. The class Hirudinea, within the phylum Annelida (segmented worms), includes leeches (2). They are capable of sucking and storing blood with multiple folds in their body composition, and the subject is usually unaware of attachment due to the leech's saliva anesthetic. Leeches can infest the skin, nasal cavity, pharynx, larynx, trachea, esophagus, urinary bladder, rectum, and vagina (3). Bleeding or mechanical organ blockage are the main complications of leech bites. Leeches tend to gather in wet environments. In contrast to terrestrial leeches, which detach themselves from their hosts after sucking blood, aquatic leeches stay attached to their hosts for extended periods and are responsible for a variety of complications (4). serious injuries to the internal viscera as a result of a leech

bite are extremely rare. When it occurs, it has the potential to cause significant morbidity and, in some cases, may even be fatal. Leech bites can occur in different places, such as the esophagus, larynx, pharynx, nose, bladder, or even the rectum (5).

Leeches can enter a person's body through the conjunctiva, cornea, vagina, vulva, urethra, mouth, and nose of individuals who typically bathe, drink, or swim in water that has not been treated or is contaminated. Sustained bleeding is one of the most concerning symptoms that can be seen in patients who have been exposed to it (6). Only a few leech bites have caused vaginal bleeding, most of which have occurred in tropical climates. After the leech is removed, the lesion may bleed for many hours or even for seven days (7).

Contaminated water allows leech entry into the vagina. Once inside, leeches attach to mucus without pain. Then, they make hirudin, a strong anticoagulant, and other anti-proteases in the saliva that mess up blood clotting and make bleeding last longer (4). Depending on the patient's condition, resuscitation or blood transfer should be done first. The patient should receive intravenous crystalloids, a 2-unit whole blood infusion, vitamin C pills, and ferrous sulfate. Leech removal is another important therapeutic step. Leeches should not be removed hastily, because their sucker could become embedded in the wound, causing bleeding and infection. Salt, rubbing alcohol, or vinegar can remove it. After the leech is removed, a pressure dressing is used (8, 9). No treatment is needed if the bleeding stops quickly. If bleeding persists, the vagina should be examined, and the bleeding area should be carefully cleaned with normal saline to ensure leech saliva has been removed. Therefore, it is of utmost priority to gather a comprehensive history and perform a thorough physical examination, as well as to manage patients based on the findings of diagnostic tests (10). This case report describes the leech-induced atypical vaginal bleeding of a 72-year-old postmenopausal woman with six days of bleeding and weakness.

## Case

A 72-year-old woman, Para v (all alive), postmenopausal for the last 20 years, visited the

nearby health center (Hazrat Ali Bin Abi Talib Sarbisheh Hospital) in October 2022 with complaints of painless vaginal bleeding of 6 days' duration and fatigue, weakness, and lower abdominal pain in the hypogastric region. On arrival, the vital signs based on scoring were BP: 90/65, RR: 18, PR: 96, T: 36.5, and GCS: 15/15.

Her prior medical history includes symptoms of dizziness and true vertigo for three months, as well as tinnitus for one year. Moreover, the patient had dyslipidemia (DLP), and her psychological disorder (depression) was treated with Citalopram, Alprazolam, Nortriptyline, and Propranolol. Another issue she faces is opium addiction. Following a visit to a general practitioner, the patient's clinical conditions and examination revealed a low hemoglobin level (7.1 g/dL), weakness, and anemia caused by postmenopausal vaginal bleeding. The patient received two units of whole blood and one liter of crystalloid solution the day before, as she had no other sources of bleeding the prior day. A white blood cell count (WBC) of  $6.2 \times 10^3/\mu\text{L}$ , a hemoglobin (Hb) of 8.8 g/dL, and a platelet count (PLT) of  $116 \times 10^3/\mu\text{L}$  were found in the first set of blood tests. The individual was subsequently referred to Vali-asr Hospital in the city of Birjand and hospitalized in the gynecological ward. The patient had no history of postcoital bleeding, several sexual partners, trauma, pain, rape, abuse, hormonal drugs, or coagulation problems. The patient's blood pressure was 75.110 mmHg, heart rate was 88 beats per minute, and breathing rate was 16. The conjunctiva was pallid. The patient was examined by a gynecologist, who noticed that she had a pale complexion. The patient was uncooperative; however, an examination was conducted to the extent possible the perineal area was covered in blood, the cervix was closed, and the size and consistency of the uterus were normal. The perineal area was covered in blood, the cervix was closed, and the size and consistency of the uterus were normal the following tests have been requested: a CBC with differential and platelet count, a prothrombin time (PT), a partial thromboplastin time (PTT), an international normalized ratio (INR), a blood urea nitrogen level (BUN), an ALT level, an AST level, an LDH level,

a transvaginal ultrasound, and vital sign monitoring. The patient reported that she occasionally bled at home, which led to the formation of sizable blood clots. Since the bleeding started, the patient has had trouble staying awake, and her dizziness has gotten significantly worse. She also feels fatigued all the time. A complete blood count showed a hemoglobin level of 9.8 g/dL and a platelet count of 142 cells/microliter, urea of 24 mg/dL, creatinine of 0.8 mg/dL, LDH of 387 U/L, and a hematocrit of 32.3%. The urine analysis showed just blood (4+), the appearance of turbidity, many RBCs, and many bacteria, and a transvaginal ultrasound showed

uterine size of 44×25 mm, endometrial thickness of 4 mm double layer, the ovaries were atrophic, and the arcuate uterine vessels are calcified. The patient was taken to surgery for diagnostic curettage. A black mass with wavelike movements was found in the tightly stuck vagina after anesthesia. A pathologist examined tissue from a complete uterine curettage. The results showed normal endometrial tissue. After surgical forceps gently removed the leech from the lower thirds of the vaginal lateral wall, the bleeding stopped (Figure 1). The patient's medical history was reviewed, and it was discovered that the patient had once bathed in freshwater in a nearby village creek.

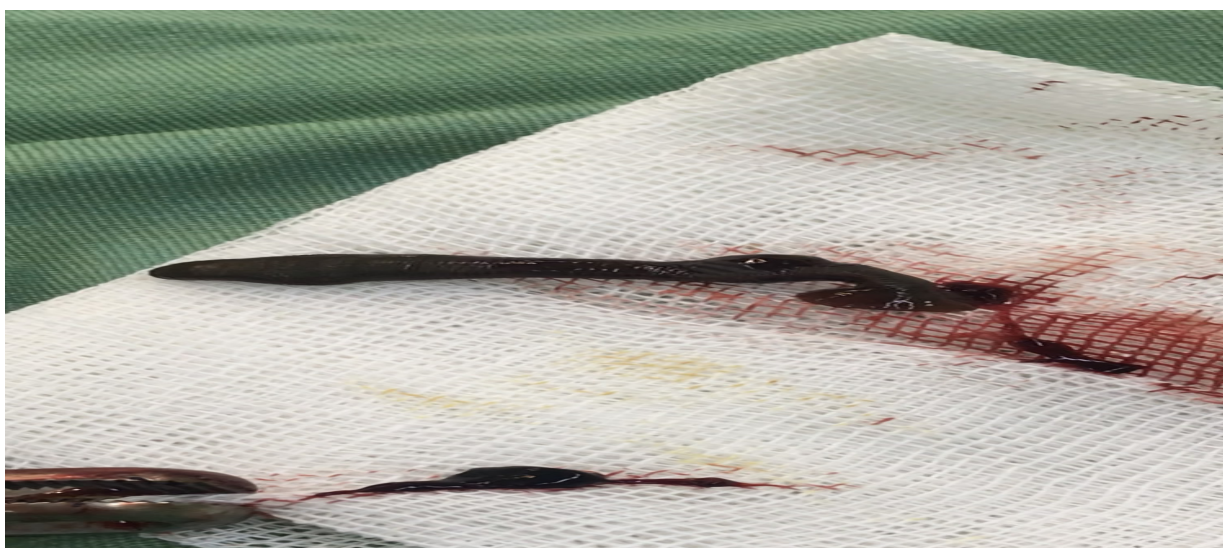


Figure 1. Leech Removal

Vaginal bleeding stopped at the next appointment. Neurology counseling examines vertigo and dizziness. The echocardiogram was normal after a cardiac consultation for shoulder burning and cold sweat. Brain MRIs and CT scans without contrast were normal. The patient's health improved, and she was discharged on the fifth day with instructions to take precautions if she visited the pond water again. Betahistine and ferrous sulfate were prescribed for dizziness. If her relatives had unusual symptoms, she was advised to bring them. before discharge, CBC showed 9.1 g/dL of hemoglobin and 150,000 platelets per microliter.

A speculum examination showed the adhesion site had fully recovered, and there was no bleeding. The

patient requested a two-week follow-up. Permission was obtained from the individual before publishing the paper to comply with ethical standards. The patient's identity and features were kept secret to advance scientific knowledge. The ethical code was obtained IR.BUMS.REC.1403.050.

## Discussion

Leech-based treatments were mentioned in historical texts, but leech-related morbidities were not (11). Greek and Moorish healers used leech phlebotomy to treat patients (12). In *The Canon of Medicine*, Abu Ali Sina, the great ancient Iranian scientist, warned travelers against drinking spring and stream water due to leech contamination (13). The leech's

vaginal attachment may cause hypovolemic shock and severe anemia. Physicians should check rural women and those who drink and bathe in streams, springs, and stagnant ponds for leech vaginal attachment to avoid complications (14). Assess the patient's medical history with an emphasis on recent activities, and conduct a pelvic examination using a speculum to identify the source of the bleeding (15).

Imaging and laboratory tests may complete the diagnosis. Excessive force can leave leech hooks in the site, causing infection. After feeding on a host's blood for 20–120 minutes, leeches may detach and become easier to remove. In an emergency, a local anesthetic (5 mL of 10% lidocaine directly to the leech), a strong salt solution, or a lighted match (or cigarette) could be used to detach leeches from their hosts (13).

The patient's coagulation profile may require additional treatment. Complex cases may need more medical attention. However, if the hemorrhaging stops quickly, treatment is usually unnecessary. In cases of excessive or persistent vaginal bleeding, the vagina must be checked and rinsed with normal saline to remove leech saliva. Additionally, the vaginal canal should be rinsed, and gauze should be applied (15).

Leech bite bleeding usually stops on its own. Persistent bleeding after a leech bite can be due to hirudin secretion from leech saliva, leech migration into deeper tissue structures, and disseminated intravascular coagulation as a secondary complication due to significant blood loss. In this study, the patient's bleeding was stopped without the use of a pressure dressing. A similar case study reported persistent vaginal bleeding in a postmenopausal woman due to a leech bite in the vagina, which resulted in hypovolemic shock and severe, life-threatening anemia (15). In cases of bleeding thought to be due to a leech bite, the diagnosis heavily relies on facts, the patient's history, and a comprehensive clinical examination. Leech infestation monitoring encompasses various aspects.

First, supportive treatment of symptoms, reduces leech bite complications, and second, parasite removal. Supportive treatment may include

intravenous crystalloids, blood transfusions, and iron sulfate.

## Conclusion

Even though leeches are not a common cause of vaginal bleeding, it is important to examine the external genitalia and vagina and ask about the patient's history of swimming or bathing in polluted springs, qanats, rivers, and pools. To reduce risk, rural and endemic residents must receive health education and information about leech bite contamination and its effects. To prevent complications, physicians and nurses should consider leeches as a potential cause of vaginal bleeding, even in the postmenopausal period. Early diagnosis significantly benefits the patient and reduces the risk of complications.

## Conflict of interest

The authors declare that there is no Conflict of interest.

## References

1. Ganguly BB, Sinha AK, Adhikari S. Introduction to biology of animals: New Central Book Agency; 1988.
2. Kutschera U, Shain DS. Hirudinea Lamarck 1818: Evolutionary origin and taxonomy of the six medicinal leeches (genus *Hirudo*) known today. *Biomedical Research and Reviews*. 2019;3(1):1-4.
3. Rahman ST, Shahriar T, Tarannum A, Kasem MA, Akter T. A case report on prepubertal vaginal bleeding due to leech bite: history is very important. *Gynecol Obstet Case Rep*. 2021;(1):8896600.
4. Saber A, Khodaparast M, Yazdani M. Vaginal Leech Infestation: a Rare Cause of Prepubertal Vaginal Bleeding and Anemia. *J Babol Univ Med Sci*. 2019;21(1):74-77.
5. Krüger C, Malleyeck I, Olsen OH. Aquatic leech infestation: a rare cause of severe anaemia in an adolescent Tanzanian girl. *European journal of pediatrics*. 2004;163:297-299.
6. Zengin Y, Gündüz E, Mustafa İ, Dursun R, Durgun HM, Gündüzalp A, et al. A rare cause of epistaxis due to leech infestation: a case report. *JEMCR*. 2014;5(7):197-199.



7. Karunaratne AH, Wijerathne BT, Wickramasinghe RS, Wijesinghe AK, Liyanage AS. A rare case of vaginal bleeding in a child due to a leech bite and review of the literature. *Wilderness & Environmental Medicine*. 2015;26(4):579-584.
8. Tilahun T. Case Report-vaginal leech Infestation: a rare cause of Hypovolumic shock in postmenopausal woman. *Ethiopian Journal of Health Sciences*. 2015;25(4):377-380.
9. Lkizceli L, AvLaroLulları L, Sözüer E, Yürümez Y, Akdur O. Bleeding due to a medicinal leech bite. *Emergency medicine journal*. 2005;22(6):458-460.
10. Mahmoudian A, Hamzei A. Postmenopausal Vaginal Bleeding after Infesting with Leeches. *ZJRMS*. 2012;14(4).
11. Elliott JM, Kutschera U. Medicinal leeches: historical use, ecology, genetics and conservation. *Freshwater Reviews*. 2011;4(1):21-41.
12. Mofrad MH, Shafiei R, Bolandi S, Najjari M, Hatam G. Leech bite: a rare cause of postmenopausal vaginal bleeding. *Iran Red Crescent Med J*. 2012;14(6):384.
13. Azizi M-H. The otorhinolaryngologic concepts as viewed by Rhazes and Avicenna. *Arch Iran Med*. 2007;10(4):552-555.
14. Hannan M, Hoque M. Leech infestation in children through body orifices: experience in a hospital in Bangladesh. *World journal of surgery*. 2012;36(9):2090-2092.
15. Hasanzadeh M, Zarrinfar H, Najjari M. Unusual vaginal bleeding due to a leech bite in a girl from a tropical area: A case report. *Revista da Sociedade Brasileira de Medicina Tropical*. 2019;52 e20180425.