






CASE REPORT

A Case Report of a Patient with Suicidal Trauma, Abdominal Surgery, and Short Bowel Syndrome

Ghasem Zarei¹ , Iman Nariman² , Hosein Ghaderi-Zefrhi³ 
, Mohamad Sadegh Aboutalebi⁴  

¹ Department of Medical Physiology, Isfahan University of Medical Sciences, Research and Development Responder of Shahid Sadoughi Hospital, Isfahan, Iran

² Department of General Surgery, Isfahan University of Medical Sciences, Isfahan, Iran

³ Department of Clinical Biochemistry, School of Pharmacy & Pharmaceutical Sciences, Isfahan University of Medical Sciences, Isfahan, Iran

⁴ Nursing & Midwifery Care Research Center, Department of Nursing Critical Care, School of Nursing and Midwifery, Isfahan University of Medical Sciences, Isfahan, Iran

Received: December 03, 2024

Revised: December 11, 2024

Accepted: December 16, 2024

Abstract

Suicidal behavior in chronic spinal palsy is frequently reported and constitutes a significant cause of mortality in these patients. Continuous management of psychiatric conditions can reduce mortality and psychosomatic complaints. A 69-year-old man with a history of spinal cord palsy, psychological treatment, socioeconomic challenges, and frontal trauma presented to the emergency room with a pale face and a 15 cm abdominal laceration in the right upper quadrant caused by a suicidal attempt. After initiating fluid therapy and emergency stabilization, the patient was transferred to the operating room. Approximately 2 meters of the small intestine were resected due to trauma, and a colorrhaphy was performed. Although the surgical intervention saved the patient from severe trauma, his prognosis remained critical. In the intensive care unit (ICU), hemodynamic stabilization, bleeding management, and antibiotic therapy were conducted. Total parenteral nutrition (TPN) was gradually transitioned to enteral nutrition (EN) using a specialized technique described in this report. By the 28th day of hospitalization, the patient's clinical, psychological, and mental conditions had stabilized, and he was discharged with special therapeutic care. Over the following three months, continuous monitoring of liver and kidney function, psychological health, diarrhea frequency, and physical strength revealed favorable outcomes, suggesting the effectiveness of the treatment protocol.

Key words: Short Bowel Syndrome, Surgery, Suicide, Trauma

Introduction

Chronic spinal palsy is associated with a high risk of suicidal behavior, which is a significant cause of death in these patients. Continuous psychiatric management can help reduce mortality and psychosomatic complaints [1-3]. Patients with chronic spinal palsy and spinal cord injury are often afflicted by depression, low mood, and suicidal tendencies, posing a serious public health concern.

The World Health Organization (WHO) has highlighted the elevated suicide risk among these patients [3]. Short Bowel Syndrome (SBS) is a rare condition characterized by the loss of bowel mass due to surgical resection, congenital disabilities, or disease [4]. Symptoms include malabsorption, dehydration, diarrhea, weight loss, steatorrhea, and electrolyte imbalances. Persistent diarrhea and malabsorption can cause dehydration and reduced kidney function. Patients with SBS may require

© 2024 Journal of Surgery and Trauma

Tel: +985632381214

Fax: +985632440488

Po Box 97175-379

Email: jsurgery@bums.ac.ir

✉ Correspondence to:

Mohamad Sadegh Aboutalebi, Nursing & Midwifery Care Research Center, Department of Nursing Critical Care, School of Nursing and Midwifery, Isfahan University of Medical Sciences, Isfahan, Iran

Telephone Number: +983137927566

Email Address: aboutalebi@nm.mui.ac.ir

parenteral nutrition (PN) or intravenous fluid support (5). Prolonged PN use may lead to intestinal failure-associated liver disease (IFALD). To mitigate these complications, gut adaptation should be promoted through enteral nutrition (EN). However, little is known regarding nutritional management in SBS patients. Kim et al. proposed nitrogen balance analysis to reduce PN dependence in SBS patients (6). This case report describes the management of a 69-year-old male patient with SBS, evaluating effective and safe treatment methods.

Case

A 69-year-old man with a history of spinal cord palsy, psychological treatment, socioeconomic challenges, and frontal trauma presented to the emergency room with pallor and a 15-cm abdominal laceration in the right upper quadrant due to a suicide attempt. Due to his T4 spinal injury, the patient did not experience abdominal pain; however, his motor nerves in the hands were intact,

enabling him to penetrate the abdomen and expose the abdominal contents.

In the emergency room, fluid therapy was initiated, emergency orders were executed, and blood samples were sent to the laboratory. The patient was then transferred to the operating room. Anesthesia was induced using Propofol and ketamine, maintained with Isoflurane, and supplemented with norepinephrine (4 mcg/kg/min), four units of fresh frozen plasma, and four units of packed red blood cells to manage hypotension.

A midline abdominal incision exposed the abdomen. Approximately one liter of blood was suctioned, and packs were placed. The liver, stomach, pelvic cavity, and spleen showed no active bleeding. Only 15 cm of duodenum and 10 cm of terminal ileum remained intact; other sections of the intestine were severely damaged. Mesenteric artery branches were sutured to control bleeding (Figure 1).

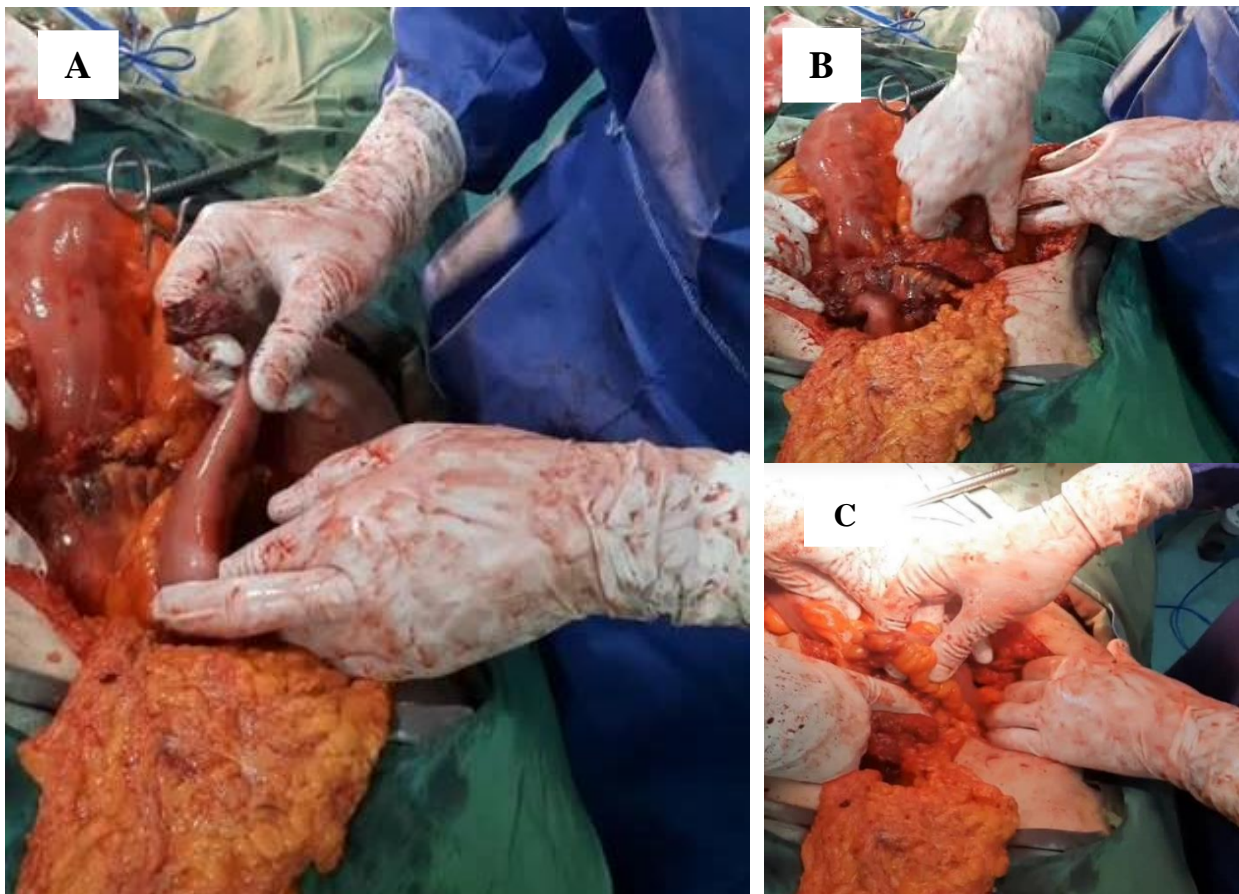


Figure 1. Empty abdomen from small intestine. (A) Duodenum and mesenteric peritoneum remained; (B) remained intestine; (C) 10 cm of terminal ileum

The ascending colon was depersonalized in two segments, and a colorrhaphy was performed. The ascending colon was medially rotated to create two intestinal segments, and an appendectomy was performed. In order to reduce anastomotic tension, the remaining small intestines were side-to-side anastomosed in two layers; then, the abdomen was closed. Post-surgery, the patient was extubated and transferred to the intensive care unit (ICU).

Hemodynamic stabilization was achieved in the ICU using crystalloids and packed red blood cells. TPN, consisting of 70 grams (1 g/kg) of amino acids, 350 grams (50% of total energy) of dextrose, and 70 grams (1 g/kg) of lipids, was initiated on the third day and continued for 10 days. Heparin (5,000 units three times daily) was administered from the third day to prevent pulmonary thromboembolism.

The patient initially experienced 15 episodes of diarrhea per day. Furosemide and albumin were administered to reduce edema. During the duration of TPN, hypertriglyceridemia was observed, and a tablet of atorvastatin was administered when triglyceride levels reached 350 mg/dL. If magnesium reached under 1.8 mg/dl or phosphate reached under 2.5 mg/dl, magnesium sulfate 30 meq per day was administered. The patient did not have hypernatremia or hyponatremia; however, he had hypokalemia and received 60 mL of 15% KCl and 60 mL of oral KCl per day to correct his potassium level. Due to the high diarrhea ratio and the normal color of the drainage secretions, TPN was gradually shifted to enteral nutrition (EN) over 48 hours.

EN was initiated from the 12th to the 14th day, containing iso-osmolar fluids and protein powder; however, the diarrhea rate reached 10 times daily. On the 20th day, the color of drain corrugate secretions was milky; the CT scan with contrast agent showed no leakage of fluids from the intestine to the abdomen. Continuously, we followed EN with a moderate length chain of triglyceride to decrease ascetic fluid. Carbohydrates, folic acid 1 mg twice per day, B complex once per week, vitamin C 500 mg, and vitamin A 5000 units per week were administered. Additionally, tablet Loperamide 2 mg was given four times per day, and tablet Clidinium C 2.5 mg/5 mg was taken once per day, along with high-dose antacids (pantoprazole 50 mg every 12 hours and famotidine 40 mg once per day) for controlling diarrhea. Calcium-D 500 mg/1000 units was provided daily, along with a low oxalate diet to prevent oxalate stones, while omitting sugar and full-fat foods from feeding. The powdered protein of Entra Meal® was converted to hydrolyzed powdered protein of PEPTAMEN®. After these treatments, the diarrhea rate reached

5 times per day.

On the 24th day, the drain corrugate fluid color was milky again. Octreotide 100 mg twice daily was administered, which was reformed three days further. On the 28th day, the patient was discharged with stable hemodynamics, a diarrhea rate of 5 times per day, and with the recommendation of drugs containing complex sugars, PEPTAMEN protein, 2 liters of ORS solution, 1 liter of fluid feeding (e.g., dough) so that the urine volume output from the Foley urinary catheter remained constant at 1 liter, a low oxalate diet, medium-chain triglycerides, B12 weekly, folic acid twice per day, calcium D per day, pantoprazole 50 mg once per day, famotidine 40 mg, and Clidinium C once per day for inhibition of gastric hypersecretion, tablet Loperamide 2 mg twice per day, Octreotide 100 mg twice per day, and theophylline 80 mg once per day for prevention of the probability of bradycardia from octreotide.

In addition, these parameters were recommended to examine one week after discharge, including Ca, phosphor, Na, K, albumin, CBC, BUN, Cr, and urine volume. One week later, these parameters were normal, and fortunately, the diarrhea rate was three times per day. On the 45th day after discharge, the patient experienced hiccups and nausea. After stopping Loperamide, Famotidine, and Clidinium C, the diarrhea rate stabilized, and these complaints were resolved. On the 65th day after discharge, a sonography result showed Grade II fatty liver and elevated AST and ALT levels. Fortunately, 160 days post-surgery, follow-up sonography of the liver indicated Grade II fatty liver with normal renal function. A psychologist visited him several times and prescribed appropriate recommendations.

Discussion

Long-time administration of total parenteral nutrition (TPN) can damage the structure and functions of several epithelial cells of the gastrointestinal tract (7); therefore, the management and transfer of TPN to EN is the point of accuracy. The process of transferring should be gradual throughout 48–72 hours. The overall process of nutrition management in this study can be outlined as follows: The acute phase occurs immediately after the bowel resection, and dehydration, acid-base abnormalities, and electrolyte deficiencies must be avoided. The second phase occurs from 48 hours to 4 weeks after the resection, featuring a stepwise increase in the duration of EN and a corresponding decrease in the duration of TPN. The maintenance phase lasts several years with continuous nutrition support (7, 8).

The ileum has more significant potential for

adaption compared to the jejunum because of the ability of nutrient absorption (bile salts, vitamin B12, fat-soluble vitamins, electrolytes) and slow motility pattern due to the proximity to the ileocecal valve (8, 9).

Short bowel syndrome involves several uncomfortable conditions, including gastric hypersecretion, hypermobility, and cholerrheic diarrhea in the acute phase following the induction of SBS, as well as osteoporosis, nephrolithiasis, and kidney and liver failure in the chronic phase (9). One of the important concerns and follow-up issues is the suitable approach for treating acute complications and preventing chronic complications. In relation to this topic, we have made an approach based on recent recommendations.

Conclusions

This case highlights the importance of multidisciplinary approaches in managing complex cases involving SBS after suicidal trauma. These approaches included surgical intervention, gradual nutritional transition (TPN to EN), pharmacological treatment perioperative, careful home care at follow-up, and monitoring of liver and kidney function that induced successful and favorable outcomes. Further basic research regarding these approaches is recommended.

Conflict of Interest

There is no conflict of interest to be declared.

References

1. Kisely S, Preston N, Xiao J, Lawrence D, Louise S, Crowe E. Reducing all-cause mortality among patients with psychiatric disorders: a population-based study. *CMAJ*. 2013;185(1):E50-E56.
2. Han S, Kim W, Kim O. Risk factors for suicidality in individuals with spinal cord injury: a focus on physical and functional characteristics. *Ann Rehabil Med*. 2023;47(5):377-384.
3. Faleiros F, Binati F, Bimbatti K, Vedana KGG, Carvalho e Silva J, De Oliveira K  ppler C, et al. suicidal ideation in people with traumatic spinal cord injury. *Psychiatry Int*. 2023;4(4):394-403.
4. Carroll RE, Benedetti E, Schowalter JP, Buchman AL. Management and complications of short bowel syndrome: an updated review. *Curr Gastroenterol Rep*. 2016;18(7):40.
5. Kelly DG, Tappenden KA, Winkler MF. Short bowel syndrome: highlights of patient management, quality of life, and survival. *JPEN J Parenter Enteral Nutr*. 2014;38(4):427-437.
6. Kim A, Sim S, Kim J, Hwang J, Park J, Lee J, et al. Nutrition management through nitrogen balance analysis in patient with short bowel syndrome. *Clin Nutr Res*. 2022;11(2):146-152.
7. Jiang L, Wang Y, Xiao Y, Wang Y, Yan J, Schnabl B, et al. Role of the gut microbiota in parenteral nutrition-associated liver disease: from current knowledge to future opportunities. *J Nutr*. 2022;152(2):377-385.
8. Puoti MG, K  glmeier J. Nutritional management of intestinal failure due to short bowel syndrome in children. *Nutrients*. 2022;15(1):62.
9. Mocanu V. Harnessing gut microbial modulation in chronic inflammatory gastrointestinal disease. 2021.