

# CASE REPORT

## Metastasis of alveolar soft part sarcoma of the retroperitoneum to distal phalanx of hand

Mohammadreza Motie<sup>1✉</sup>, Mohsen Aliakbarian<sup>2</sup>, Alireza Rezapanah<sup>3</sup>

<sup>1</sup> Associate Professor of Surgery, Surgical Oncology Research Center, Imam Reza Hospital, Faculty of Medicine, Mashhad University of Medical Sciences, Mashhad, Iran;

<sup>2</sup> Associate Professor of Surgery, Surgical Oncology Research Center, Imam Reza Hospital, Faculty of Medicine, Mashhad University of Medical Sciences, Mashhad, Iran;

<sup>3</sup> Assistant Professor of Surgery, Surgical Oncology Research Center, Imam Reza Hospital, Faculty of Medicine, Mashhad University of Medical Sciences, Mashhad, Iran.

Received: May 21, 2017

Revised: June 15, 2017

Accepted: June 25, 2017

### Abstract

Hand metastasis accounts for approximately 0.1 percent of all metastatic osseous malignancies. The lung, breast and kidney are the most common primary sources of these metastatic lesions. A rare case of retroperitoneal alveolar soft part sarcoma metastasizing to the distal phalanx of the second finger of the right hand is presented here. The patient underwent complete DIP amputation of the affected finger and was referred to oncologist for further therapeutic workups. Acrometastases run a poor prognosis; thus, palliative treatment is in the patient's best interest.

**Key Words:** Sarcoma, Alveolar Soft Part; Neoplasm Metastasis; Finger Phalanges

### Introduction

Acro-metastasis to the bones of the hand is not common. It comprises approximately 0.1 percent of all metastatic osseous malignancies. The low frequency of hand metastasis may be explained by the less red marrow present in the hand (1). Handley firstly reported this unusual manifestation in 1906 (2).

The etiology is quite different from that of metastasis to other bones. Lung, followed by the breast and the kidney, are the three most prevalent primary sources reported in the literature. The remainder of the cases usually develops from cancers of the colon, stomach, liver, prostate, and rectum (3, 4).

Overall, the right hand was more often the host to

metastatic lesions. In addition, almost 10% of the cases have lesions in both hands. The third finger is the digit mostly affected by osseous metastases. Lesions of the other fingers are less common. The distal phalanx is the most frequent site of metastasis. The met

acarpals and the proximal phalanges account for the remainder of the most frequent region of the digit affected within the patient population (3, 4).

We present a case of alveolar soft part sarcoma (ASPS) of the retro peritoneum metastasis to the third finger of the right hand.

### Cases

A 33 year-old man was presented to our facilities with a necrotic lesion in the distal phalanx

©2016 Journal of Surgery and Trauma

Tel: +985632381203

Fax: +985632440488

Po Bax 97175-379

Email: jsurgery@bums.ac.ir



✉ Correspondence to:

Mohammadreza Motie, Associate Professor of Surgery, Surgical Oncology Research Center, Imam Reza Hospital, Faculty of Medicine, Mashhad University of Medical Sciences, Mashhad, Iran;

Telephone Number: +989151101871

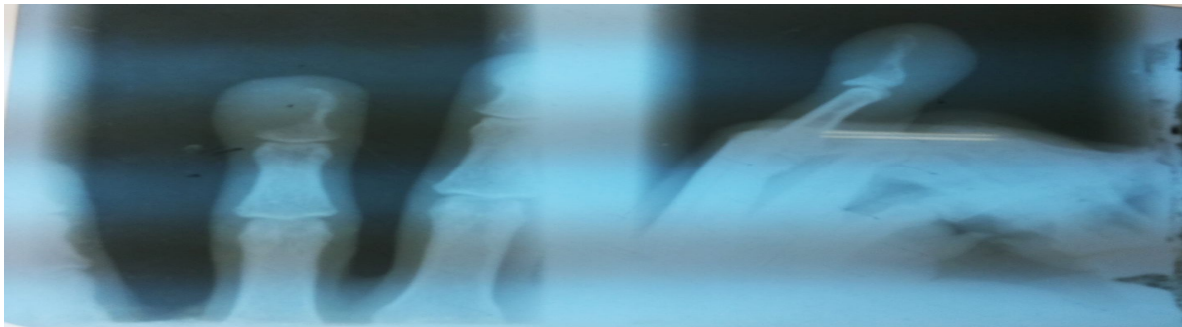Email Address: MotieM@mums.ac.ir

of the second finger (index finger) of his right hand. Radiography showed a 1\*2 cm osteolytic lesion that involved the distal phalange of the second digit [Fig. 1].

Eighteen months ago, he was diagnosed with ASPS of the retroperitoneum. At the time, his history and course of diagnosis and treatment were as follows: He presented complaining of an abdominal mass, nausea and vomiting. Physical examination revealed an immobile mass with smooth surface and about 10\*5 cm in size, palpated in RLQ. His examinations were otherwise unremarkable. Laboratory findings were all within normal limits. CT scan studies demonstrated a hyper-dense mass with necrotic center, 78\*83 mm in diameter in the lower abdomen [Fig. 2]. Colonoscopy findings were normal. Ultrasound guided biopsy of the lesion was performed and revealed neuroendocrine tumor. As a locally aggressive sarcoma, it was decided that complete

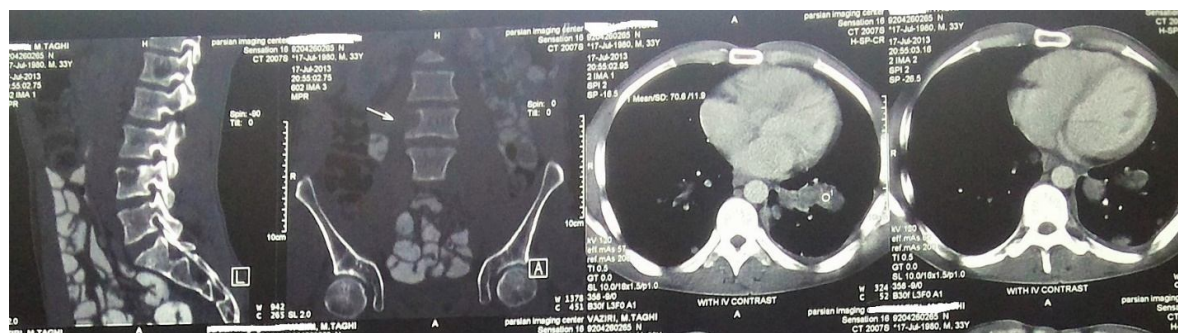
resection would yield the best chance of patient recovery and survival. Resection of the tumor was performed via laparotomy; a well-defined mass in retroperitoneal space without adhesion to urethra or other organs was transected and sent to pathology for further analysis. Histopathology report was obtained as a poorly differentiated (high grade) adenocarcinoma consistent with high grade RCC, which was incompatible with intraoperative and imaging data. There was no abnormality in either kidneys and no adhesion around the mass as it was observed during the operation. Therefore, we asked for a microscopic review and pathology, which confirmed that the lesion was ASPS. All surgical margins also were free [Fig. 3 & 4]. The patient refused adjuvant chemotherapy and unfortunately he did not show up to continue his treatment and further follow-ups.

**Figure 1: Osteolytic lesion of the distal phalanx:** Plain radiographs of the right hand revealed a 1.2-cm osteolytic lesion involving the distal phalanx of the second digit



**Figure 2: Coronal reformat images of abdominal & pelvic CT scan showed a retroperitoneal primary mass that was operated about 2 years ago**

**Figure 4: Large polyhedral cells with sharp borders containing large round nuclei with prominent nucleoli and abundant granular and less vacuolar cytoplasm (H&E, \*400)**



**Figure 5.** Sagittal and coronal reformat images of lumbar spine CT scan showing lytic metastatic lesions in L1 and L4 vertebral bodies. Lung CT scan images show a parahilar mass in the left lower lobe with mild pleural effusion.

For this newly developed lesion [Fig. 1], a full second finger (index finger) DIP amputation was administered. The pathologic report of the material obtained during surgery revealed metastatic carcinoma. Metastatic workup demonstrated metastasis in vertebrae column and lung metastasis [Fig. 5]. The patient was referred to the oncologist for additional treatment.

## Discussion

ASPS is a rare malignant soft tissue neoplasm, which accounts for less than 1% of soft tissue sarcomas. It was initially described as a distinctive clinical entity by Christopherson et al. in 1952 (5). The tumor received its name from its pseudo-alveolar appearance created by polygonal cells lacking central adhesion and abundant sinusoidal vessels (6, 7). It mainly affects adolescents and younger adults aged between 15 and 35 years, but the tumor can also occur in children as young as 2 years old. There is a slight female predilection (8, 9). The most common sites involved include extremities and trunk in young adults and head and neck in children (8, 10). ASPS is a slow-growing tumor with unusual patterns of metastasis. The most common sites of metastases include lungs, brain and bones (8).

Despite the extreme rarity of secondary metastasis to the hand bones, it should always be in mind as a differential diagnosis. Misdiagnosis or late diagnosis of metastases to the bones of the hand can cause pain, swelling, soft tissue ulceration, and massive osteolytic destruction; acrometastasis may also be the first manifestation of an occult cancer (4, 11). Differential diagnoses include paronychia, osteomyelitis, septic arthritis, gout and primary bone tumor (1, 11)

In our case, the diagnosis was made based on the clinical presentation, previous history of retroperitoneal ASPS, and pathology report. The lung and the brain are the most common sites of metastases in ASPS which is why X-ray or CT scans of the lung should be included in the follow-up

examinations for ASPS (7, 12) as in our patient who had metastases in vertebrae column and lung metastasis. The prognosis of patients with acrometastasis is poor, with an average survival length of 6 months (13). This means that pain palliation is often the primary aim of treatment, and the physician should choose the treatment in the best interest of the patients. At the time, surgery (amputation of the affected finger) is the definitive treatment (1, 4, 11).

## Conclusions

Considering the metastatic nature of ASPS, periodic radiologic follow-up is necessary to detect metastasis in these patients. Given the poor prognosis of patients with metastatic bone lesions, palliative therapy is the most important therapy to be considered.

## Conflict of Interests

Authors have no conflict of interests.

## References

- Huang FX, Zhang N, Liu L, Zhang H. Metastasis of lung adenocarcinoma to the fifth distal phalange of right hand. *BMJ Case Rep.* 2011 Sep 30;2011:bcr0520114276.
- Handley WS. *Carcinoma of the Breast and Its Operative Treatment.* John Murray. 1906: 32-40.
- Kerin R. The hand in metastatic disease. *J Hand Surg Am.* 1987 Jan 1;12(1):77-83.
- Flynn CJ, Danjoux C, Wong J, Christakis M, Rubenstein J, Yee A, Yip D, Chow E. Two cases of acrometastasis to the hands and review of the literature. *Curr Oncol.* 2008 Oct;15(5):51.
- Zadnik PL, Yurter A, DeLeon R, Molina CA, Groves ML, McCarthy E, Sciubba DM. Alveolar soft-part sarcoma in the sacrum: a case report and review of the literature. *Skeletal Radiol.* 2014 Jan 1;43(1):115.

6. Setsu N, Yoshida A, Takahashi F, Chuman H, Kushima R. Histological analysis suggests an invasion-independent metastatic mechanism in alveolar soft part sarcoma. *Hum Pathol.* 2014 Jan 31;45(1):137-42.
7. Daigeler A, Kuhnen C, Hauser J, Goertz O, Tilkorn D, Steinstraesser L, Steinau HU, Lehnhardt M. Alveolar soft part sarcoma: clinicopathological findings in a series of 11 cases. *World J Surg Oncol.* 2008 Jul 1;6(1):71.
8. Falkenstern-Ge RF, Kimmich M, Wohlleber M, Grabner A, Friedel G, Ott G, Leuschner I, Kohlhäufel M. Lung metastasis of primary alveolar soft-part sarcoma occurring 20 years after initial treatment. *Case Rep Oncol Med.* 2013 Nov 27;2013.
9. Silas OA, Adoga AA, Manasseh AN, Echejoh GO, Vhritherhire RA, Mandong BM. Persistent alveolar soft-part sarcoma with liver metastasis: a case report. *J Med Case Rep.* 2010 Jul 30;4(1):233.
10. Kim JM, Im SA, Oh SN, Chung NG. Alveolar soft part sarcoma arising from the kidney: imaging and clinical features. *Korean J Radiol.* 2014 Jun 1;15(3):381-5.
11. Carvalho HD, Tsai PW, Takagaki TY. Thumb metastasis from small cell lung cancer treated with radiation. *Rev Hosp Clin Fac Med Sao Paulo.* 2002;57(6):283-6.
12. Portera Jr CA, Ho V, Patel SR, Hunt KK, Feig BW, Respondek PM, Yasko AW, Benjamin RS, Pollock RE, Pisters PW. Alveolar soft part sarcoma. *Cancer.* 2001 Feb 1;91(3):585-91.
13. Hsu CS, Hentz VR, Yao J. Tumours of the hand. *Lancet Oncol.* 2007 Feb 28;8(2):157-66.