

ORIGINAL  
ARTICLE**Is meatal stenosis so important as to discourage neonatal circumcision?**

Mohammad Nadjafi-Semnani<sup>1</sup>, Hamed Najaran<sup>2</sup>, Ali Nadjafi-Semnani<sup>3</sup>,  
Fatemeh Nadjafi-Semnani<sup>3</sup>, Nahid Ghanbarzadeh<sup>4</sup> ✉

<sup>1</sup> Associate Professor of Urology, Shahid Beheshti University of Medical Sciences, Tehran, Iran

<sup>2</sup> Medical Student, Member of Committee Research Center, Birjand University of Medical Sciences, Birjand, Iran

<sup>3</sup> Medical Student, Tehran University of Medical Sciences, Tehran, Iran

<sup>4</sup> Associate Professor of Gynecology and Obstetrics, Department of Gynecology and Obstetrics, Birjand University of Medical Sciences, Birjand, Iran

Received: November 5, 2017

Revised: April 15, 2018

Accepted: May 21, 2018

**Abstract**

**Introduction:** Circumcision is proposed as the world's oldest and most controversial operation and meatal stenosis as the most common complication of neonatal circumcision. Published studies in Iran are deficient regarding this complication. This research shows the rate of meatal stenosis in children less than one year in Birjand-Iran.

**Methods:** This descriptive study incorporated all children younger than 12 months who had normal penile anatomy and were circumcised using the plastic disposable device by one urologist from March 2005 to January 20<sup>th</sup>, 2009. Children were examined 14 days after circumcision. Parents of the children were subsequently called for meatal stenosis screening. Those that had symptoms were examined in the office, and their urine flow was observed.

**Results:** During the study period, 518 children (mean age: 47.6±2.7 days) were circumcised. Operation time for circumcision was 4±0.8 minutes. Mean follow-up period was 26.5±11.5 (8-55) months. A total of 12 (2.3%) children had meatal stenosis.

**Conclusions:** Meatal stenosis was the most common complication of circumcision in this study. There is a need for more research on the prevention of this complication.

**Key Words:** Circumcision; Male; Meatal stenosis; Complication; Foreskin

**Introduction**

Circumcision is considered the world's oldest and most controversial surgical procedure (1). Newborn circumcision seems to be the most common surgical operation carried out in the United States of America (2). Most Iranians are circumcised due to the Islamic rules of religion (3). Circumcision reduces the risk of urinary tract

infection during the first year of life (4). It also reduces the risk of penile cancer (1). In a study, the protective effect of circumcision on penile cancer has been approved (5). Most cases of penile cancer in Iran belong to the men who have circumcised late as a teenager (6). Studies in Iran confirm that the complications of circumcision in elder boys are more common than the younger ones (7) (3).

©2018 Journal of Surgery and Trauma

Tel: +985632381203

Fax: +985632440488

Po Bax 97175-379

Email: jsurgery@bums.ac.ir



✉ **Correspondence to:**

Nahid Ghanbarzadeh, Associate Professor of Gynecology and Obstetrics, Department of Gynecology and Obstetrics, Birjand University of Medical Sciences, Birjand, Iran;

Telephone Number: +989155610029

Email Address: nghanbarzadeh@gmail.com

These studies also reveal that most Iranian boys are circumcised at the age of 2-7 years (8). During consultation with the parents, some physicians discourage neonatal circumcision due to its complication of meatal stenosis (6). Studies on circumcision and the meatal stenosis in Iran are scant (3, 9). This study was performed to show the prevalence of meatal stenosis in children less than one year who have been circumcised in the urologic clinic using a disposable plastic device. Results of this study could be used by physicians during parental consultation regarding the prevalence of meatal stenosis and neonatal circumcision.

## Methods

The study protocol was approved by the ethics committee of the Birjand University of Medical Sciences (Identifier: ir.bums.REC.1394.427). The study included all male infants under one year of age with normal anatomy of penis, who were circumcised from March 2005 until January 20th, 2009, by a board-certified urologist with 16 years' experience in an office setting equipped with all necessary resuscitation equipment. Infants with hypospadias, buried penis, and small penis were excluded from the study. Circumcision was performed with the plastic disposable device according to the method described below (10) with a penile block for anesthesia. For dorsal penile nerve block, 4-5 mg/kg Lidocaine 1% was used and after infiltration, the infant waited for 5 minutes in the arm of the mother for full anesthesia effect. Meanwhile, the mother was advised to breastfeed the child during this period. The skin of prepuce was then marked carefully at the glans for proper skin removal. The infant was held in supine position and his knee was kept by an assistant. After prep and drape, the prepuce was separated from glans and the dorsal slit incision site is crushed and cut. Prepuce is reduced behind glans using a betadine-soaked gauze, and the preputial adhesions to glans was freed completely. An appropriate-sized plastic disposable device was placed into position on the glans and the foreskin was pulled back over the bell. The ligature was then properly positioned around the bell's groove and tied. The excess foreskin was removed just distal to the ligature, and lidocaine gel was applied. The time from prep and drape to applying lidocaine gel was recorded as the circumcision operation time. Parents were instructed to change the napkins as soon as they were soiled and to apply vitamin A+D ointment onto the penis and

glans during the first two weeks of circumcision. This is the recommendation of the World Health Organization to use lubricant immediately after circumcision and also later to apply it onto the penis. Lubricants (petroleum jelly, vaseline, petrolatum) have been shown to decrease infant male circumcision complications significantly. They serve to shield the wound, forms a barrier between the healing surfaces of the foreskin and striped areas of the glans, and keeps the wound from adhering to the diaper (11).

Parents were asked to attend the urologic clinic two weeks after circumcision for physical examination of the baby. On the 14th-day visit, early complications were recorded. Later, at least eight months after circumcision (8-55 months), in the summer of 2009, all parents were called by one trained investigator and were interviewed on telephone to screen meatal stenosis symptoms. When there was any symptom of urine stream deflection to one side, low caliber high pressure, or long distance riding urine stream, they were requested to attend the urologic clinic for a free of charge visit and thorough evaluation.

In the urologic office, the screening questionnaire was completed again. Then, all the boys were examined, and the meatus openness and shape were tested. If there was a pinpoint meatus (Figure 1), or a doubt of meatal stenosis, then the urologist in charge of the study, examined the pattern of the urination of the child in the toilet. Only if the urine stream was deflected to one side or there was narrow and excessively forceful urination, meatal stenosis diagnosis was established. All the boys with confirmed meatal stenosis were treated by meatal dilatation or meatotomy in the office setting. Data were collected and analyzed.

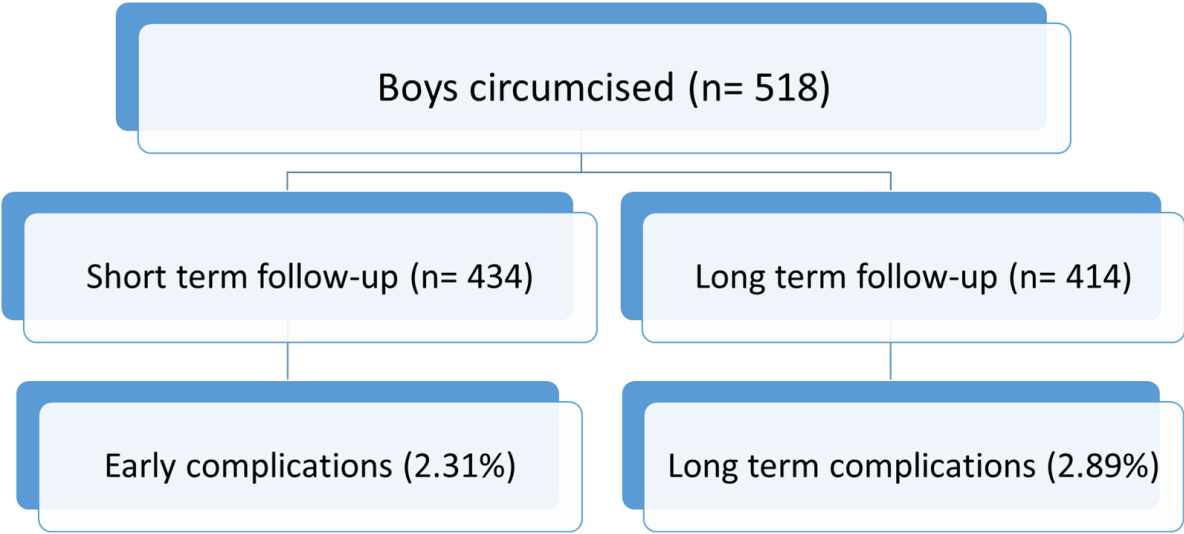
## Results

A total of 518 male infants younger than 12 months with the mean age of  $47.6 \pm 2.7$  days (2-365 days) were circumcised using the plastic disposable device. The age of 59.2%, 84.5% and 94.8% of these infants was less than 30, 90 and 180 days, respectively. The operation time of circumcision was  $4 \pm 0.8$  (4-10) minutes. The mean follow-up period was  $26.5 \pm 11.5$  (8-55) months. Overall, 83.7% of the boys were examined 14 days after circumcision (Chart 1).

The disposable ring part of the device along its ligature was dropped down at the mean time of  $7.8 \pm 2.2$  days. From among them, 12 infants (2.3%) had an early complication on the 14th-day visit.

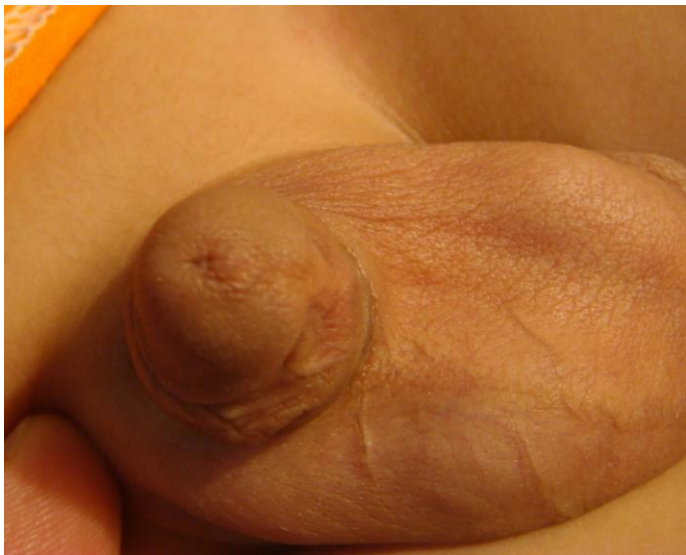

Figure 1: The appearance of the meatal stenosis in physical examination



In one child, the ring part of the device was migrated proximal to glans, while the glans had developed mild edema (Figure 2), and the child became restless. The ligature was cut with the surgical blade. The ring was broken and removed, and the baby did not develop any problem. All bleeding cases from circumcision were minor oozing, which were self-limiting and did not need any further intervention. For example, one child had loosely ligature tied around the bell's groove and developed minor bleeding after circumcision. A second ligature was tied adequately over the first whereby bleeding was stopped. Superficial wound infection was evident by purulent discharge over the skin. Ligature was seen in two cases and treated with local antibiotic ointment.

All parents were called by a trained research nurse at least eight months after circumcision, of whom 414 (79.9%) responded and were screened for symptoms of meatal stenosis. One child was expired at follow-up. Parents were invited for free of charge office visit if their child had symptoms of urine stream deflection to one side, dysuria, and a low caliber high-pressure urine stream that passes longer than usual. A total of 49 cases had such symptoms, all of whom were visited in the office for examination. At examination, 12 of 49 (2.3%) children were diagnosed to have meatal stenosis. Meatal stenosis was the most common complication of circumcision in our study. The children underwent meatal dilatation or meatotomy in the office for treatment of meatal stenosis.

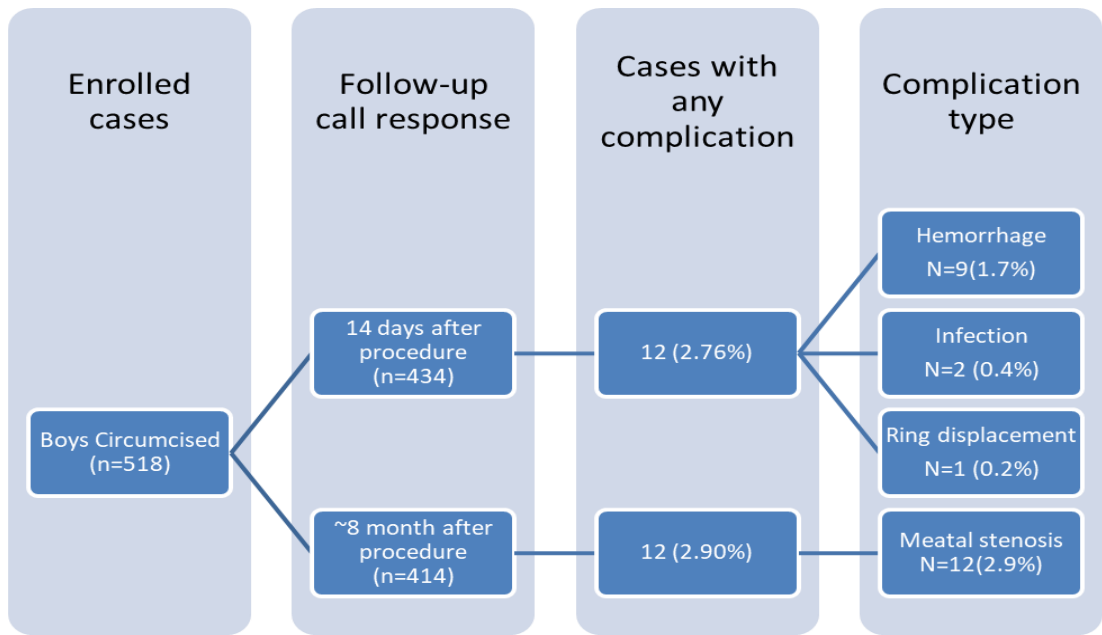


Chart 1: Short and long-term complications of neonatal circumcision

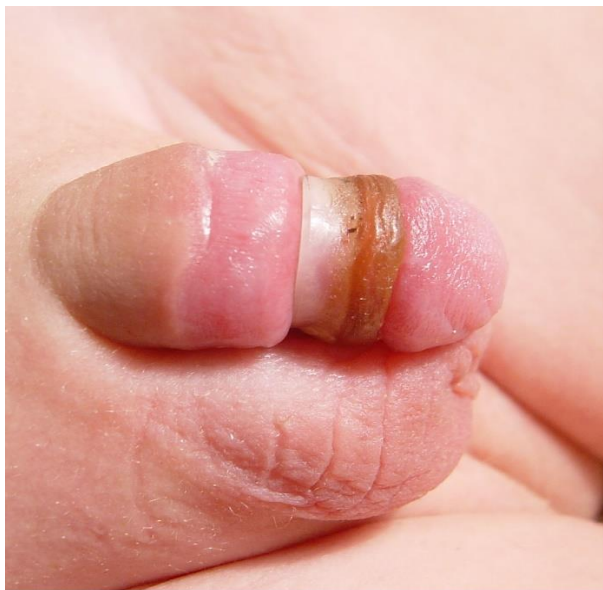


Figure 2: The ring part of the device is migrated proximal to glans, and the glans has developed mild edema.

Discussion

About 30% of males worldwide are circumcised, with almost full coverage in some countries and very low rates in some regions (7). In an Islamic society, the circumcision practice is attributed to the Prophet of Islam and circumcision acquired the status of sunnah (12). Islamic scholars do not have consensus regarding the age at which

circumcision should be carried out. The prophet Muhammad PBUH recommended performing circumcision at an early age (12). The complication rate for newborn circumcision is 0.2 to 3% (13). Minor complications include bleeding, removal of too much or too little skin, wound infection, penile adhesions, secondary phimosis with a trapped or hidden penis, injury to the glans, urethra, or penile shaft by careless cutting or by thermal damage

(13). There is a wide difference in reported frequencies of unfavorable events following circumcision (7). Several factors are directly associated with the rate of the complications, including the age at circumcision, training and expertise of the surgeon, the sterility of the conditions under which the procedure is undertaken, and the indication (medical/cultural) for circumcision (7).

Some authors assume that the most common late complication of neonatal circumcision is the meatal stenosis (13). Most studies consider the bleeding and infection as the most common complication of circumcision (7). It seems that the reason for these inconsistencies is that the follow-up of patients are inadequate, and the meatal stenosis has not been carefully investigated. Also, the difference is attributable to the methodology of studies such as the duration of follow-up, epidemiological study design, and description of complications (7). In our study, 9 cases developed hemorrhage after circumcision. All of these instances were minor self-limited bleeding, and there was no need for surgical exploration of the intervention. In a review article on circumcision complications, Weiss stated that the authors omitted all cases of oozing or bleeding, which had simply discontinued by squeezing (7). In a study of 1000 children aged from 7 to 9 years in Iran, Fesharkinia maintained that hemorrhage was the most common complication of circumcision in 3.4% cases. In this study, 135 children were circumcised before one month of age, and no bleeding was reported in them (3).

The lower rate of complications among neonates and infants is assumedly attributable to the uncomplicated nature of the surgery in this age group and the healing ability in the newborn (7). Moreover, a significant advantage of neonatal circumcision is that suturing is not usually necessary, whereas suturing is required for circumcisions in the post-neonatal period (7). This advantage is illuminated in a US-based study in which no complications were found among 98 boys circumcised in the first month of life, but 30% of the boys aged 3-8.5 months had significant postoperative bleeding (7). No meatal stenosis in Fesharkinia's study was reported (3). Vahedian reported hemorrhage in 0.5% of 756 children who were circumcised before six months of age (14). Of these, a hemorrhage rate of 8.2% was reported by Dehghani in 1500 children circumcised at the age younger than two years (15). Wound infection in our study was seen in 0.4% of children. All of these infections were superficial and were treated by local application of antibiotic ointment. Wound

infection was reported in 2.2%, 0.1% and 6.5% by Fesharakinia (3), Vahedian (13), and Dehghani (14), respectively.

Dehghani reported minor bleeding in 0.4% and secondary phimosis and trapped penis in 0.3% (15). In our study, one child (0.2%) had the complication of proximal migration of ring, and it was in concordance with Vahedian's findings (14). In a study of circumcision-associated complications in children younger than five years, Tootonchi failed to evaluate the meatal stenosis and no cases were reported (9). In the study of Dehghani, 4% had meatal stenosis. This complication was seen in 2.2% of our subjects, which is in concordance with Dehghani's study (15). Yegane, in the study of 3205 Iranian primary school children aged 6-12 years, reported that 0.9% of the cases had meatal stenosis (8). Low incidence of meatal stenosis in our study seems to be due to the definition of meatal stenosis as it was diagnosed by observing the shape and diameter of meatus along with the calibrating the meatus or observing the urine stream. Simply observing the meatus is not sufficient for establishing the diagnosis of meatal stenosis. It has been proposed that in case of doubt concerning meatal stenosis, meatus should be calibrated with bougie or infant sounds (6). Weiss stated that a major hurdle in their survey of complications of circumcision was to standardize the description of complications (7). If the urethral meatus of a boy looks especially small, urination of the child should be observed. In some cases, one can see that the meatus opens as a full, and a good stream is passed (16). If the stream is thin and very forceful, stenosis is presumably present (16).

## Conclusions

Although the meatal stenosis was observed in 2.2% of the infantile circumcision in our study, it was the most common complication. It has minor morbidity with low incidence and has no obstructive effect on the urinary tract (17), which can nonetheless be effectively treated with meatal dilatation or meatotomy in the office (6). Some physicians do not recommend neonatal circumcision because of the meatal stenosis associated with it, and during consultation with parents, these physicians discourage neonatal circumcision (6). Although all Iranian boys are circumcised due to the Islamic rules, studies show that most of them are circumcised after two years of age (8). This research can help physicians during parental consultation regarding the age of circumcision, and by encouraging infantile circumcision in newborns, they can benefit the

decreased urinary tract infection, decreased complications of circumcision, and profoundly reduced risk of penile cancer.

### Acknowledgements

We are immensely grateful to Mr. Aliabady for his contribution to the project, regarding patient registration and file management, which helped the team to perform the follow-up in a reasonable manner.

### Authors' contributors

Nadjafi-Semnani M and Ghanbarzadeh N developed the study design and the proposal. Najaran H and Nadjafi-Semnani M performed the study with Nadjafi-Semnani M doing the procedures and Najaran H following the patients up. Nadjafi-Semnani A and Nadjafi-Semnani F analyzed the data and prepared the manuscript. All authors received the final manuscript and approved it.

### Funding

This research was partially supported by Birjand University of Medical Sciences.

### Conflict of interest

There is no conflict of interest of authors for this study.

### References

1. Alanis MC, Lucidi RS. Neonatal circumcision: a review of the world's oldest and most controversial operation. *Obstet Gynecol Surv.* 2004 May;59(5):379-95.
2. Nelson CP, Dunn R, Wan J, Wei JT. The increasing incidence of newborn circumcision: data from the nationwide inpatient sample. *J Urol.* 2005 Mar;173(3):978-81.
3. Fesharaki Nia A, Ghafouri KH, Fouad Aldini M, Saadatjou SAR. A Study of circumcision condition in Birjand city. *J Birjand Univ Med Sci.* 2005; 12(3-4):45-9. [Persian]
4. Shaikh N, Morone NE, Bost JE, Farrell MH. Prevalence of urinary tract infection in childhood: a meta-analysis. *Pediatr Infect Dis J.* 2008 Apr;27(4):302-8. doi: 10.1097/INF.0b013e31815e4122.
5. Djajadiningrat RS, Jordanova ES, Kroon BK, van Werkhoven E, de Jong J, Pronk DT, et al. Human papillomavirus prevalence in invasive penile cancer and association with clinical outcome. *J Urol.* 2015 Feb;193(2):526-31. doi: 10.1016/j.juro.2014.08.087.
6. Simforoosh N, Nour Alizadeh A. Urinary Tract Infection in peadiatrics. In: Simforoosh N, Nour Alizadeh A (eds). *Iranian Textbook of Urology.* Tehran: Behineh; 2008. Vol 2. pp: 657-64. [Persian]
7. Weiss HA, Larke N, Halperin D, Schenker I. Complications of circumcision in male neonates, infants and children: a systematic review. *BMC Urol.* 2010 Feb 16;10:2. doi: 10.1186/1471-2490-10-2.
8. Yegane RA, Kheirollahi AR, Salehi NA, Bashashati M, Khoshdel JA, Ahmadi M. Late complications of circumcision in Iran. *Pediatr Surg Int.* 2006 May;22(5):442-5. DOI: 10.1007/s00383-006-1672-1
9. Tootoonchi P, Mahmoodzadeh H, Neamatolahzadeh Kh. A study of circumcision prevalence and complications in under 5 year old boys in Galleno village-Shahre Ray, Jan 1997. *Tehran Univ Med J.* 1998; 56(3):25-8. [Persian]
10. Simforoosh N, Nour Alizadeh A. Urinary Tract Infection in peadiatrics. In: Nour Alizadeh A (editor). *Iranian Textbook of Urology.* Tehran: Behineh; 2008. Vol 2 .pp: 657-64. [Persian]
11. World Health Organization. Manual for early infant male circumcision under local anaesthesia [Book on Internet]. Geneva: WHO Press; 2010. available at: <http://apps.who.int/iris/bitstream/handle/10665/44478/?sequence=1>.
12. Rizvi SA, Naqvi SA, Hussain M, Hasan AS. Religious circumcision: a Muslim view. *BJU Int.* 1999; 83 Suppl 1:13-6.
13. Elder JS. Abnormalities of the Genitalia in Boys and Their SurgicaMl anagement. In: Wein AJ (editor). *Campbell-Walsh Urology.* 9<sup>th</sup> ed. Philadelphia: Sunders Elsevier; 2007. Vol 4. pp: 3745-60.
14. Vahedian M, Zeynalinezhad H, Sotoudehnezhad AR, Pourseyedi B, Aghaei Afshar M. Evaluation of postoperative complications of Plastibell circumcision in infants under 6 months of age. *Iran South Med J.* 2003;5(2):141-5. [Persian]
15. Dehghani V, Moein MR, Mir Shamsi MH. [The prevalence of complications following circumcision in children under two years of age in Yazd]. *J Shaheed Sadoughi Univ Med Sci.* 2000;8(2):41-5. [Persian]
16. Jordan JH, Schlossberger SM. Surgery of the Penis and Urethra. In: Wein AJ (editor). *Campbell-Walsh Urology.* 9<sup>th</sup> ed. Philadelphia: Elsevier Sunders; 2007. Vol 1. pp: 1023-96.
17. Mahmoudi H. Evaluation of meatal stenosis following neonatal circumcision. *Urol J.* 2005 Spring;2(2):86-8.