

CASE REPORT

Bilateral symmetrical nasal retinal hypopigmentation associated with iris heterochromia: A case report

Gholam Hossain Yaghoobi¹ , Malihe Nikandish² 

¹Professor of Ophthalmology, Department of Ophthalmology, Valiasr Hospital, Birjand University of Medical Sciences, Birjand, Iran

²Assistant Professor, Department of Ophthalmology, Valiasr Hospital, Birjand University of Medical Sciences, Birjand, Iran

Received: January 24, 2019

Revised: February 27, 2019

Accepted: February 27, 2019

Abstract

We reported the case of a 9-year-old boy with a complete right blue iris and left brown iris. Other Ophthalmic examinations were normal except for the homonymous symmetrical pattern of nasal retinal hypopigmentation. The case had no systemic finding or positive family history. The present case was unique because the presentation of iris heterochromia did not follow Mendelian law and was not associated with any diseases or syndromes.

Key words: Heterochromia iridis, Inheritance pattern, Retinal pigmentation

Introduction

Iris color is one of the most obvious physical characteristics of a person that is determined by the concentration and distribution of melanin in the iris. Iris heterochromia that is the difference in the coloration of the iris may be complete or partial (sectoral), as well as congenital or acquired (1). Patients with complete heterochromia have two different-colored eyes, such as a blue eye and a brown eye. Heterochromia iridis is a rare condition that affects fewer than 200,000 individuals in the United States. Congenital heterochromia is usually inherited as an autosomal dominant trait. This condition can also occur in a variety of syndromes (2).

Cases

A 9-year-old boy with different iris colors since birth referred to our eye clinic (Figure 1). The right eye was diffusely blue and the left one was brown. In ophthalmic examination, visual acuity without correction in both eyes was 10/10. The pupils were reactive to light. He had a full range of ocular movements. The canthus position, lid position, and ocular adnexa were normal. The slit-lamp examination showed no abnormality in the anterior segment except for complete right iris heterochromia. Fundus examination revealed symmetrical patterns of nasal retinal hypopigmentation in both eyes (Figure 2).

The patient had no associated systemic

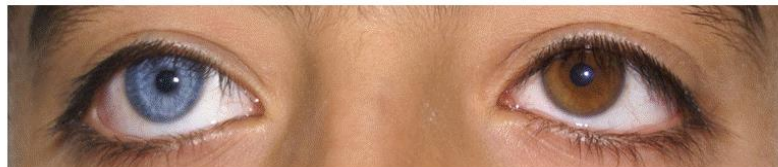

Figure 1: Heterochromia



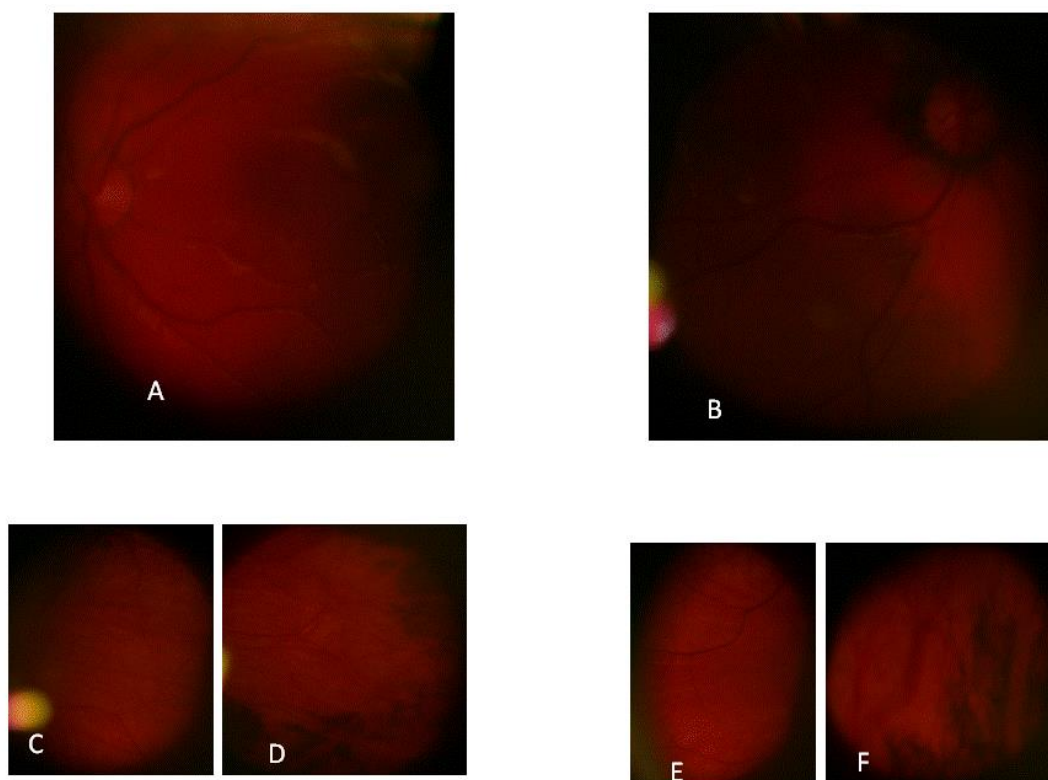


Figure 2: A: Right fundus, B: Left fundus, C: Nasal hypopigmentation and D: temporal hyperpigmentation of right eye. E: Nasal hypopigmentation and F: Temporal hyperpigmentation of Left eye

findings. There was no depigmentation in any parts of his skin or hair. He had no hearing impairment that is occasionally detected in individuals with heterochromia iridis. There were no inflammations or tumors associated with his eyes. The case did not suffer from any serious diseases since birth. In addition, he had no family history of iris heterochromia.

Discussion

We described complete iris heterochromia with bilateral retinal hypopigmentation associated with no skin or hair pigmentation disorders, as well as no systemic diseases. In the most fundamental forms, the inheritance of eye color is classified as a Mendelian trait. However, on the basis of the observation of phenotypes, iris pigmentation has a more complex pattern of inheritance and is controlled by at least 16 genes (3). It remains uncertain whether the co-occurrence of heterochromia iridis with retinal hypopigmentation in the present case was just coincidental or a true association.

We reported a case of heterochromia iridis that showed symmetrical retinal pigmentation versus heterochromia iridis. That case also had centrally-placed white forelock and could be considered

as Waardenburg syndrome (4). Other different congenital syndromes, such as Horner's syndrome, Sturge-Weber syndrome, Recklinghausen disease, Bournville disease, Hirschsprung's disease, and Block-Sulzberger syndrome, may also be characterized by heterochromia iridis (5). The present case was not associated with any of the aforementioned syndromes.

Mehta et al. reported the case of iris heterochromia that showed choroidal depigmentation with classical salt and pepper retinal appearance in a 2-year-old deaf female with brilliant blue iris related to Waardenburg syndrome (6). Tomar described the case of a 47-year-old male presented with Amber- and white-colored iris patches giving an artistic appearance to the iris of both eyes (7). In the present case, Mendelian dominant-recessive gene inheritance could not clarify heterochromia that was not associated with any systemic diseases. To the best of our knowledge, this was a unique presentation of iris and retinal pigment association without any systemic manifestations.

Conclusions

In conclusion, the association between iris and retinal pigmentation is much more complex

than Mendelian trait, and unilateral iris hypopigmentation (iris heterochromia) may be accompanied by bilateral retinal hypopigmentation.

Conflict of Interest

The authors declare that there is no conflict of interest.

References

1. Deprez FC, Coulier J, Rommel D, Boschi A. Congenital horner syndrome with heterochromia iridis associated with ipsilateral internal carotid artery hypoplasia. *J Clin Neurol*. 2015; 11(2):192-6. [PMID: 25749818](#) [DOI: 10.3988/jcn.2015.11.2.192](#)
2. Ur Rehman H. Heterochromia. *CMAJ*. 2008; 179(5):447-8. [PMID: 18725617](#) [DOI: 10.1503/cmaj.070497](#)
3. White D, Rabago-Smith M. Genotype-phenotype associations and human eye color. *J Hum Genet*. 2011; 56(1):5-7. [PMID: 20944644](#) [DOI: 10.1038/jhg.2010.126](#)
4. Yaghoobi G, Heidari E. Bilateral symmetric retinal pigmentation versus heterochromia: a case of waardenburg syndrome. *Pak J Ophthalmol*. 2013; 29(1):50-2.
5. Guha M, Maity D. Heterochromia iridis-a case study. *Explor Anim Med Res*. 2014; 4(2):240-5.
6. Mehta M, Kavadu P, Chougule S. Waardenburg syndrome. *Indian J Otolaryngol Head Neck Surg*. 2004; 56(4):300-2. [PMID: 23120104](#) [DOI: 10.1007/BF02974395](#)
7. Tomar M, Dhiman R, Sharma G, Yadav N. Artistic iris: a case of congenital sectoral heterochromia iridis. *J Ophthalmic Vis Res*. 2018; 13(3):359-60. [PMID: 30090196](#) [DOI: 10.4103/jovr.jovr_91_17](#)