

CASE REPORT

Laser therapy in lip hemangioma: A case report

Maryam Jalili Sadrabad¹ , Shabnam Sohanian² 

¹ Assistant Professor, Department of Oral Medicine, School of Dentistry, Semnan University of Medical Sciences, Semnan, Iran

² Assistant Professor, Department of Oral and Maxillofacial Pathology, School of Dentistry, Semnan University of Medical Sciences, Semnan, Iran

Received: October 23, 2019

Revised: November 22, 2019

Accepted: January 27, 2020

Abstract

Hemangioma is a benign vascular lesion, which is common in the head and neck but rare in the oral cavity. Oral hemangioma presents as a smooth, soft, painless mass, which may be sessile or pedunculated in any size. However, most of the lesions will diminish spontaneously. Several therapeutic approaches are used for hemangiomas, such as cauterization, cryotherapy, laser therapy, and sclerosing agents. Herein, we reported the case of a 36-year-old female who had a swelling on the top of her upper lip since birth. We proposed laser therapy as an efficient treatment plan because of its benefits, such as the achievement of coagulation, comfort for both practitioner and patient, and esthetic advantages. Moreover, this approach eliminates the chance of recurrence if performed perfectly.

Key words: Hemangioma, Laser therapy, Mouth, Oral, Surgery

Introduction

Hemangioma is a benign vascular lesion, which occurs as a result of the proliferation of the endothelial cells. It is considered a common soft-tissue tumor of the head and neck, which rarely appears in the oral cavity. Although intraoral hemangioma is rare, it might appear on the tongue, lip, gingiva, buccal and palatal mucosa, salivary glands, and bones (1). The first case of hemangioma was reported by Liston in 1843. In 1940, Kasabach and Merrit reported another case of hemangioma, which affected the skin and deep soft tissues and was associated with extensive purpura (1).

Hemangioma is microscopically classified into capillary and cavernous type. Capillary hemangioma consists of many small vessels, with a lining of a single layer of endothelial cells (2). Hemangioma is usually present at birth; however, it may also grow rapidly and involute during

childhood (3). Clinically, oral hemangioma presents as a smooth, soft, painless mass, which may be sessile or pedunculated in any size. The lesion is characterized by a bluish red color (1). There are many other lesions, which may look like oral hemangioma. The differential diagnoses include pyogenic granuloma, vascular lesions (e.g., telangiectasia), angiosarcoma, Sturge-Weber syndrome, and squamous cell carcinoma (1).

This condition has several therapeutic approaches, such as cauterization, cryotherapy, laser therapy, and sclerosing agents. However, most of the lesions do not need any treatment because they can be recognized clinically and diminish spontaneously (4, 5). This report presented a case of oral hemangioma in the upper lip treated by enucleation and laser therapy.

Cases

A 36-year-old female was admitted to the

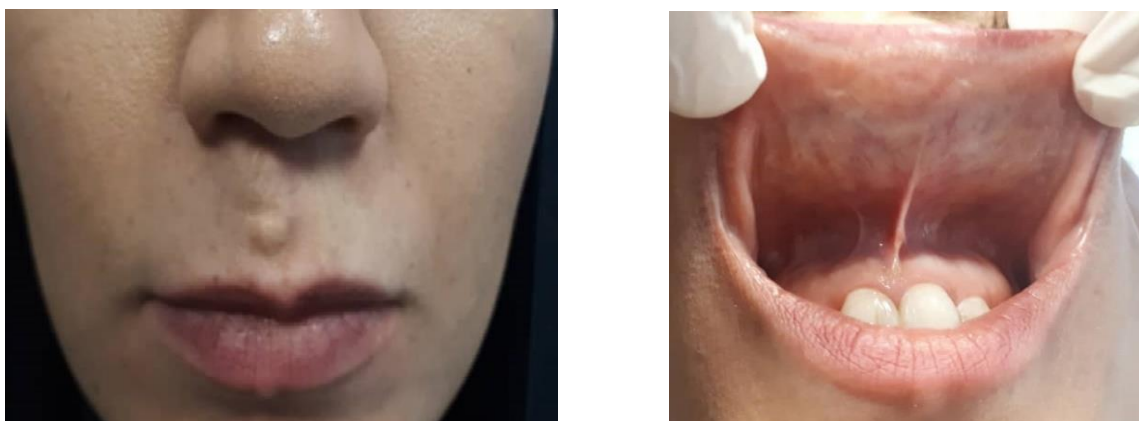


Figure 1: Clinical features of the lesion; A) a swelling on the upper lip, B) intraoral view

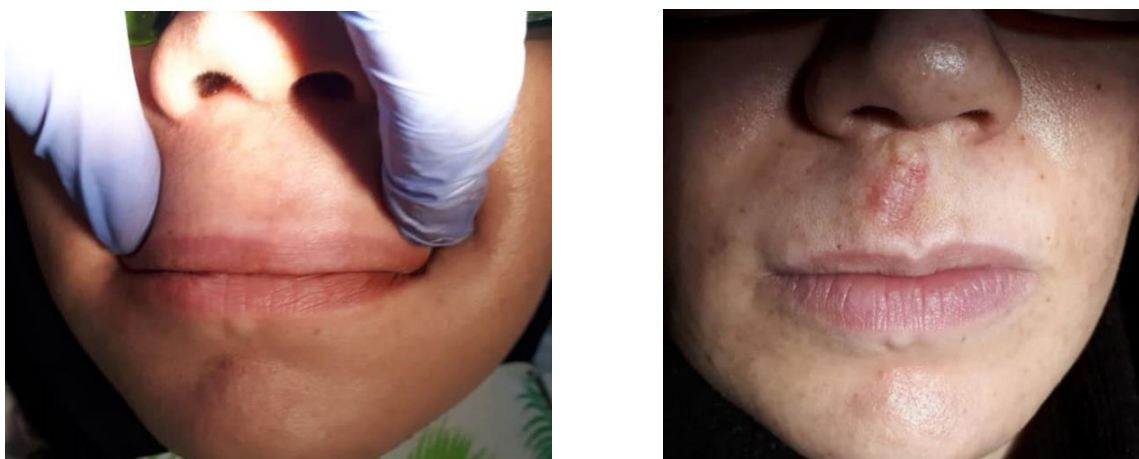

Figure 2: A) Lesion state right after laser therapy of hemangioma, B) one week after lesion removal

Department of Oral Medicine of Semnan Dental School, Located in Semnan, Iran, for a dental checkup. She had a swelling on the top of her upper lip. This lesion had existed since birth and had grown until 5 years of age, but then had shrunk in size and remained stable. The patient had referred to many dentists, and they all had denied the possibility of getting rid of the lesion (Figure 1). Clinically, the swelling had the same color as the adjacent skin, with a smooth and lobulated surface. In the extraoral examination, it measured 2×1.5 cm and was located on the right side of the upper philtrum, from the vermilion border up to the bottom of the nose. In addition, magnetic resonance angiography displayed a 1-cm lesion which was located deep on the back of the upper lip. After obtaining informed consent, the diode 940 laser was used to achieve coagulation in the lesion. The lesion disappeared just in a few seconds without any pain, bleeding, or discomfort. Subsequently, the extra, loose, superficial skin was removed by a blade (Figure 2). The recovery process was observed in three follow-up sessions

performed 1 week, 3 weeks, and 2 months after laser therapy.

Discussion

Hemangioma is the most common benign vascular tumor, which often appears during infancy and childhood. Although the lesion grows rapidly, it manifests a slow involution (1). The word hemangioma is derived from a Greek word, where 'hema' means blood, 'angeio' denotes vessel, and 'oma' means tumor. This terminology has been broadly used in medical and dental texts (6). Histologically, hemangioma is classified into capillary and cavernous types.

The lesion has a mesenchymal origin that is characterized by the creation of the vascular tubes of endothelial cells. Capillary hemangioma is composed of many small capillaries lined by a layer of endothelial cells, supported by a varying density of stroma. Unlike the capillary form, cavernous hemangioma consists of large vessels with thin walls or sinusoids separated by connective tissue

septa (1, 7). Clinically, oral hemangiomas are benign, enlarged, vascular hamartomas that seem like a painless, soft mass, which are smooth, lobulated, sessile, or pedunculated lesions and can be seen in any size. The lesion may show a rapid growth or enlarge progressively as the patient grows (1, 8).

Typically, hemangioma has a light bluish hue, with a characteristic "blanching" effect (1, 7, 8). Hemangioma is usually painless but if traumatized, it can be ulcerated and hemorrhagic (1, 9). The majority of hemangiomas occur in the head and neck. Hemangiomas arise in any organ; however, the most common site is the skin. They also frequently affect the oral cavity, specifically the oral mucosa, tongue, lips, and palate (6). Trivedi K. et al. reported a case of hemangioma on the buccal mucosa and vestibule (5). There are also reports regarding oral hemangioma on the gingiva (2, 7, 9), buccal mucosa (4), lower lip (6), and tongue (10).

In the present study, the patient had a congenital hemangioma of the upper lip, which had not been diagnosed until she was 36 years old. Hemangioma has a female predilection (6, 8). Accordingly, our case and other cases reported previously were all female (2, 4, 5, 7, 9). Hemangioma has a wide spectrum of clinical features, such as facial asymmetry, pain, spontaneous bleeding, teeth mobility, pulsation, bone expansion, root resorption, paresthesia, early exfoliation of the primary teeth, delayed eruption, and missing teeth (9). In the present case, the only clinical feature was lip swelling. A variety of lesions in the oral cavity are assigned as the differential diagnoses of hemangioma. These differential diagnoses include pyogenic granuloma, telangiectasia, Sturge-Weber syndrome, chronic inflammatory gingival hyperplasia, angiosarcoma, and squamous cell carcinoma (1).

Jananni M. et al. reported two cases of hemangioma in the gingiva mimicking as pyogenic granuloma (2). The management of hemangioma depends on a variety of factors. However, most of these lesions require no intervention and disappear without any treatment or noticeable marks. However, some types of hemangiomas require treatment because of their size, location, esthetic problem, stage of growth, and behavior (7). Large hemangiomas can cause skin changes because of the severe stretching of the skin or damaging the surface texture. Facial lesions, especially those located on the nose and lips, need cosmetic surgery (10).

The range of treatment depends on the associated risk and benefits. Surgery, laser therapy, corticosteroids, interferons, sclerosing agents,

radiation therapy, electrocauterization, and cryosurgery are the therapeutic approaches for hemangioma (7, 10). Total excision is a challenging treatment plan for hemangioma because it may have a high chance of recurrence. Corticosteroids have some systemic side effects; therefore, they should be applied only in particular cases. Although radiotherapy regresses the lesion, it causes atrophy on the tissues, especially on the skin. Cryotherapy and laser therapy can be used for superficial lesions (10).

Trivedi et al. decided to treat intraoral hemangioma by a sclerosing agent via intra-lesion injection. They repeated the injection within 3-week intervals, and after 6 months, the lesion almost healed (5). In some cases, due to the size and location of hemangiomas, the dentists decided to choose surgical excision, which reportedly results in no signs of recurrence both clinically and radiographically (4, 9). In the present case, we decided to use the diode 940 laser in order to use the benefits of coagulation, comfort, and esthetics.

Conclusions

Hemangioma is benign in origin and behavior. Given the clinical importance of oral hemangioma, the appropriate clinical diagnosis and proper management of this lesion are issues of critical significance. We proposed laser therapy as an efficient treatment plan because of its benefits, such as the achievement of coagulation, comfort for both practitioner and patient, and esthetic advantages. Moreover, this approach eliminates the chance of recurrence if performed accurately.

Conflict of Interest

There is no conflict of interest to be declared.

References

1. Kamala KA, Ashok L, Sujatha GP. Cavernous hemangioma of the tongue: a rare case report. *Contemp Clin Dent*. 2014; 5(1):95-8. PMID: 24808705 DOI: 10.4103/0976-237X.128680
2. Jananni M, Gubernath U, Mahendra J, Sivaramakrishnan M. Capillary hemangioma of gingiva mimicking as pyogenic granuloma: Report of two cases. *J Interdiscip Dent*. 2012; 2(3):218. DOI: 10.4103/2229-5194.113268
3. Newadkar UR. Oral hemangioma or vascular malformation: different entities! *J Indian Acad Oral Med Radiol*. 2015; 27(3):497. DOI: 10.4103/0972-1363.170480
4. Lakshmi S, Prasad D, Rao SD, Prasanth C, Gangadharan V, Kumar K. Primary hemangioma of a

- submental lymph node –a rare entity. *Int J Med Res Health Sci.* 2015; 4(2):474-6. [DOI: 10.5958/2319-5886.2015.00091.0](#)
5. Trivedi K, Soni A, Meshack R, Kulthya RS. Intraoral hemangioma: an overview of the clinical entity. *J Int Clin Dent Res Organ.* 2015; 7(1):79. [DOI: 10.4103/2231-0754.153506](#)
 6. Bakhshi M. Cellular hemangioma in an adult: a case report. *J Dent Materials Techniq.* 2018; 7(3):145-8. [DOI:10.22038/JDMT.2018.11118](#)
 7. Dilsiz A, Aydin T, Gursan N. Capillary hemangioma as a rare benign tumor of the oral cavity: a case report. *Cases J.* 2009; 2(1):8622. [PMID: 20181211](#) [DOI: 10.1186/1757-1626-0002-0000008622](#)
 8. Gill JS, Gill S, Bhardwaj A, Grover HS. Oral haemangioma. *Case Rep Med.* 2012; 2012:347939. [PMID: 22431929](#) [DOI: 10.1155/2012/347939](#)
 9. Nandaprasad S, Sharada P, Vidya M, Karkera B, Hemanth M, Kaje C. Hemangioma-a review. *Internet J Hematol.* 2008; 6(2):1-13.
 10. Kalkur C, Halim N. Haemangioma on tongue: a case report. *Juniper Online J Case Stud.* 2018; 8(2): 555733. [DOI: 10.19080/JOJCS.2018.08.555733](#)