

CASE REPORT

Intravesical foreign body: An unusual case report with emphasis on treatment modality

Mohammad Nadjafi-Semnani¹✉ , Nahid Ghanbarzadeh² , Ali Nadjafi-Semnani³ 

¹Associate Professor of Urology, Shahid Beheshti University of Medical Sciences, Tehran, Iran

²Associate Professor of Gynecology and Obstetrics, Birjand University of Medical Sciences, Birjand, Iran

³Resident in General Surgery, Shiraz University of Medical Sciences, Shiraz, Iran

Received: December 23, 2019

Revised: February 15, 2020

Accepted: March 01, 2020

Abstract

Very different objects have been reported as foreign bodies in the urinary bladder, which encompasses everything available in the environment, and each one presents a new challenge to urologists. Herein, we report the case of a 21-year-old male patient presented with lower urinary tract symptoms. Two months before his presentation, he had introduced a 110 cm soft electrical wire to his urethra, which migrated into the bladder. Although it has been said that most foreign bodies in the bladder could be endoscopically removed, an attempt to remove this wire by cystoscopy was unsuccessful, and suprapubic cystostomy was performed for the removal. Therefore, it is recommended to consider suprapubic cystostomy the choice of treatment instead of the endoscopic procedure in the case of long and knotted wires to avoid injuries to the urethra.

Key words: Bladder, Cystostomy, Cystoscopy, Foreign body, Masturbation, Suprapubic

Introduction

Almost any thinkable object has been reported as a foreign body in the bladder (1). Intravesical foreign bodies reach bladder in three different ways, including self-insertion through the urethra or traumatic path, iatrogenic, and migratory (2, 3). The most common motive associated with the self-insertion of foreign bodies to the genitourinary tract is sexual or erotic in nature (4). Foreign bodies are typically propelled into the bladder by being pushed further in the urethra in an attempt to remove them or involuntary contraction of the perineal muscles (5). The myriad of foreign bodies in the bladder encompasses everything available within the social environment of a self-insertor from bottles and straw brooms to hair and toothbrushes (6). Each foreign body presents a new challenge in the management to urologists.

PubMed database was searched in this case report for the keywords, including "Foreign Body" and "Urinary Bladder".

Cases

A 21-year-old male patient presented with a history of dysuria and frequency. Urinalysis showed pyuria, hematuria, and bacteriuria. Urine culture demonstrated significant *Escherichia coli*. Ultrasonographic examination revealed an echogenic curved mass with obvious posterior shadow (Figure 1). The case did not report any history of foreign body insertion. The kidney, ureter, and bladder (KUB) X-ray showed a long metallic density superior to pubic symphysis (Figure 2). Pelvic computed tomography (CT) scan demonstrated a curved fine high-density mass in the bladder (Figure 3). Still, the patient denied any

©2020Journal of Surgery and
Trauma

Tel: +985632381203

Fax: +985632440488

Po Bax 97175-379

Email: jsurgery@bums.ac.ir

✉Correspondence to:

Mohammad Nadjafi-Semnani, Associate Professor of Urology,
Shahid Beheshti University of Medical Sciences, Tehran, Iran;

Telephone Number: +989151611485

Email Address: nadjafai@sbmu.ac.ir

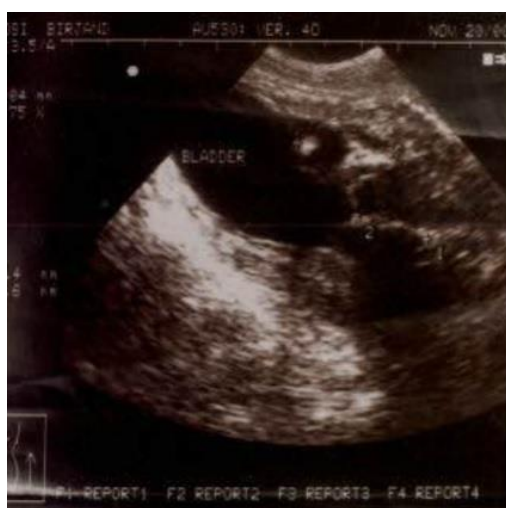

Figure 1: Ultrasound; an echogenic curved mass with obvious posterior shadow

history of the self-inserted foreign body.

Cystoscopy was conducted under general anesthesia. On cystoscopy, the wire was visible in the bulbar urethra and bladder, and it was covered by yellowish encrustation. Bladder mucosa was intensely inflamed, and there was severe trigonal hypertrophy. The wire was pulled out with biopsy forceps; however, the knotted wire was caught in the urethra and could not be removed. It was then decided to perform suprapubic cystostomy to avoid injuring the urethra.

A minimized cystostomy was carried out through a small midline incision. After opening the bladder, the wire could not be reached through the prostatic urethra because it was impacted in the bulbar urethra. For catching the wire, a cystoscope was inserted via meatus, and the wire was pushed;

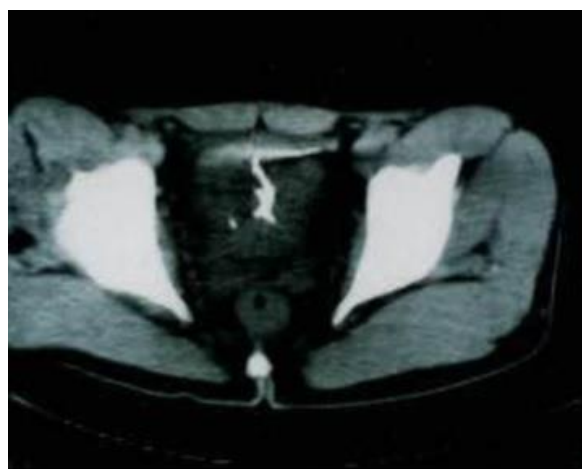


Figure 3: Pelvic computed tomography scan; a curved fine high-density mass in the bladder

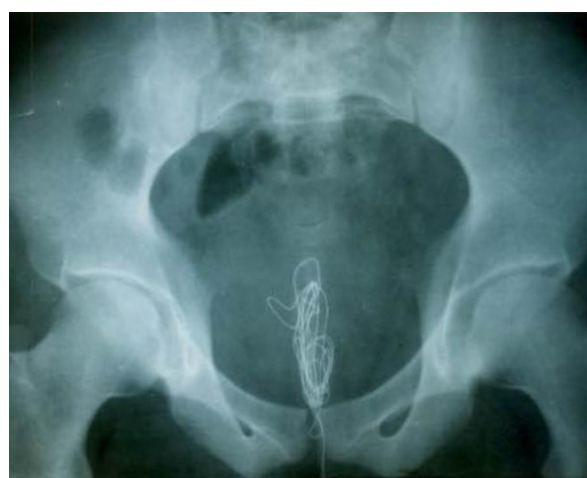

Figure 2: Kidney, ureter, and bladder (KUB) X-ray; a long metallic density superior to the pubic symphysis

therefore, it could be grasped in the prostatic urethra through the bladder and removed. The wire was 110 cm in length. The bladder was repaired in two layers, and the wound was closed. The patient was catheterized for a week after the operation, and upon its removal the patient had no problem. After a month, the case was reported with no symptom, and urine analysis was normal.

Discussion

Foreign bodies within the genitourinary tract are not infrequently observed and should be considered in the differential diagnosis of any patient with chronic unexplained urinary tract infection or hematuria (5). These cases can be found by searching PubMed. The symptoms of a foreign body in the bladder are those of acute cystitis with frequent and painful voiding and often accompanied by hematuria and stranguria (5). Most patients deny any history of the introduction of a foreign body. During the consultation, they do not give any clue for correct diagnosis.

The signs that should alert physicians regarding this diagnosis include unexplained anxiety during sexual questioning or unwillingness for genital or rectal examination (5). To evade shame, patients favor attempting treatment late and often ignore the problem until it becomes symptomatic (6). The present patient referred 2 months after introducing the wire to his urethra, and before its removal he denied it. However, after the extraction of the wire, he said that during masturbation, the wire accidentally lost into the urethra, and his attempt to find it was unsuccessful (7).

The detection and identification of a possible

foreign body are most easily conducted during an ultrasound and plain X-ray (5). In our case, the CT scan examination did not reveal any further information than KUB. Eckford et al. reported their 5 years of experience with 21 intravesical foreign bodies all of which were detected on plain abdominal X-ray (2). Pal reported three cases of intravesical wire all of which were diagnosed with a KUB (6). Most foreign bodies in the bladder may be removed via endoscopic procedures (5). Despite this statement, our case is an example demonstrating that the foreign body could not be endoscopically removed.

In the Eckford series, all the objects within the bladder were extracted in a one-stage endoscopic procedure using grasping forceps (2). In three cases of intravesical wire, all of them were endoscopically removed. In one case, the length of the wire was 110 cm, and the length of wires in other cases was not mentioned (6). In our case, it was attempted to remove the wire with cystoscopic grasping forceps; however, the wire was 110-cm long, knotted, and caught in the urethra. Finally, suprapubic cystostomy was conducted for its removal.

It is recommended to perform cystostomy and not cystoscopic extraction for the removal of the long heavy burden and knotted wire from the beginning. This statement is in line with the recommendation that suprapubic cystostomy is especially suitable if a catheter is intraurethrally lodged due to intravesical knotting (8-12). Ejstrud et al. has reported a 66-year-old man who had introduced a long electrical wire to the urinary bladder 6 weeks before referral, and one end of the wire was visible outside the urethra (7). The wire was knotted in the bladder and removed by laparoscopy (7).

Conclusions

Although it has been stated that most foreign bodies in the bladder could be endoscopically removed, an attempt to remove a 110-cm long wire by cystoscopy was unsuccessful, and suprapubic cystostomy was conducted for the removal. Therefore, it is recommended to consider suprapubic cystostomy the choice of treatment instead of the endoscopic procedure in the case of long and knotted wires to avoid injuries to the urethra.

Conflict of Interest

The authors declare that there is no conflict of interest.

References

1. Rafique M. Intravesical foreign bodies: review and current management strategies. *Urol J*. 2008; 5(4): 223-31. [PMID: 19101894](#)
2. Eckford S, Persad R, Brewster S, Gingell J. Intravesical foreign bodies: five-year review. *Br J Urol*. 1992; 69(1):41-5. [PMID: 1737252](#) [DOI: 10.1111/j.1464-410x.1992.tb15456.x](#)
3. Bansal A, Kumar M, Kanodia G, Aeron R, Goel S. Unusual intravesical foreign body in young female migrated from vagina due to autoerotism. *Int Braz J Urol*. 2017; 43(3):556-60. [PMID: 27649105](#) [DOI: 10.1590/S1677-5538.IBJU.2016.0164](#)
4. Grumet GW. Pathologic masturbation with drastic consequences: case report. *J Clin Psychiatry*. 1985; 46(12):537-9. [PMID: 4066621](#)
5. Van Ophoven A, Kernion JB. Clinical management of foreign bodies of the genitourinary tract. *J Urol*. 2000; 164(2):274-87. [PMID: 10893567](#) [DOI: 10.1097/00005392-200008000-00003](#)
6. Pal DK, Bag AK. Intravesical wire as foreign body in urinary bladder. *Int Braz J Urol*. 2005; 31(5):472-4. [PMID: 16255795](#) [DOI: 10.1590/s1677-55382005000500010](#)
7. Ejstrud P, Poulsen J. Laparoscopic removal of an electric wire from the bladder. *Br J Urol*. 1997; 80(2):338. [PMID: 9284214](#) [DOI: 10.1046/j.1464-410x.1997.00422.x](#)
8. Oosterlinck W, Renders G. A Knot in the urethra. *Br J Urol*. 1976; 48(4):284. [DOI: 10.1111/j.1464-410x.1976.tb03022.x](#)
9. Roberts P. Intravesical knotting of a urethral" catheter". *Can Med Assoc J*. 1976; 115(12):1199. [PMID: 1000452](#)
10. Najafi E, Maynard JF. Foreign body in lower urinary tract. *Urology*. 1975; 5(1):117-8. [PMID: 1114532](#) [DOI: 10.1016/0090-4295\(75\)90320-9](#)
11. Lissos I. Knots in the bladder. *Br J Urol*. 1974; 46(3):346. [PMID: 4843730](#) [DOI: 10.1111/j.1464-410x.1974.tb03839.x](#)
12. Raveenthiran V. Spontaneous knotting of urinary catheters. *Urol Int*. 2006; 77(4):317-21. [PMID: 17135781](#) [DOI: 10.1159/000096335](#)