

ORIGINAL
ARTICLE**Comparison of the effects of systemic and subcutaneous injection of recombinant human erythropoietin on the tissue-healing process in BALB/c Mice**

Seyed Yoosef Javadmoosavi^{1,2} , Negin Parsamanesh^{1,3} , Mohammad Afshar^{4,5} , Mahmoud Zardast⁶ , Reza Ghaderi⁷  

¹Student Research Committee, Birjand University of Medical Sciences, Birjand, Iran

²Medical Toxicology and Drug Abuse Research Center (MTDRC), Birjand University of Medical Sciences, Birjand, Iran

³Zanjan Metabolic Diseases Research center, Zanjan University of Medical Sciences, Zanjan, Iran

⁴Department of Anatomy, Faculty of Medicine, Birjand University of Medical Sciences, Birjand, Iran

⁵Medical Toxicology Research Center, Mashhad University of Medical Sciences, Mashhad, Iran

⁶Faculty of Medicine, Birjand University of Medical Sciences, Birjand, Iran

⁷Department of Dermatology, Faculty of Medicine, Birjand University of Medical Science, Birjand, Iran

Received: January 25, 2020

Revised: February 19, 2020

Accepted: February 19, 2020

Abstract

Introduction: Erythropoietin (EPO) is a glycoprotein hormone that is secreted for biological responses and is regulated by the interaction between EPO and specific cytokine receptors. The EPO is a mediator of angiogenesis and erythropoiesis and can increase several growth factors. The current research aimed to compare the effects of systemic and subcutaneous injection of recombinant human EPO on the tissue-healing process.

Methods: For the purposes of the study, 30 male BALB/c mice were selected and divided into three groups. The first one received EPO treatment with systemic injection (n=10) while the second one received EPO treatment with subcutaneous injection (n=10). The third group was the control or placebo group without any treatment (n=10). The biopsies were studied on days 4, 7, 10, and 14 through staining by hematoxylin-eosin and Mallory's trichrome. In each group, 3 mice were sacrificed due to exposure to high doses of anesthetic on days 4 and 7. Moreover, 2 other mice were sacrificed after 10 and 14 days. The collected data and images were analyzed in SPSS (version 18.0) and ImageJ software, respectively. Furthermore, they were analyzed using Wilcoxon signed-rank and analysis of variance tests in. During all the analytical processes, a p-value of <0.05 was considered statistically significant

Results: According to the results, the density of inflammatory cells significantly decreased in EPO-treated groups, compared to the control group. Moreover, the EPO-treated groups underwent an increase regarding the number of fibroblast cells, new capillary formation, and epithelial thickness in the margins of the wound, unlike the control group.

Conclusions: Findings of the present study indicated that the systemic injection of EPO resulted in a better physiological response regarding the acceleration of tissue-healing in comparison with the subcutaneous injection. Furthermore, the systemic injection of EPO improved the parameters related to skin wound repair.

Key words: Erythropoietin, Skin, Subcutaneous injection, Systemic erythropoietin, Wound healing

Introduction

Skin is the most primary and vital shield of the

body that protects the internal living tissues and organs against bleeding, invasion of microbial organisms, and dehydration (1). More specifically,

©2020 Journal of Surgery and Trauma

Tel: +985632381203

Fax: +985632440488

Po Box 97175-379

Email: jsurgery@bums.ac.ir

✉ **Correspondence to:**

Reza Ghaderi, Department of Dermatology, Faculty of Medicine, Birjand University of Medical Science, Birjand, Iran;

Telephone Number: +989155612135

Email Address: rezaghaderi@yahoo.com

this largest organ plays an essential role in several physiological processes, such as regulation of the peripheral circulation, body temperature, and synthesis of vitamin D (2).

Accordingly, tissue healing is a dynamic and complex reconstructive process requiring provisional fibrin formation and substitution of the lost dermis with novel matrix. Moreover, the speed of tissue healing is influenced by several factors, such as age, health status, wound location, and blood reserve in that region (1, 3, 4). The tissue healing process consists of four overlapping bio-physiological phases, namely hemostasis, inflammatory reaction, proliferation, and remodeling (5).

Erythropoietin (EPO) is a glycoprotein hormone that mediates the proliferation, maturation, and differentiation of erythroid precursor cells. It has various hematopoietic roles, such as increasing epithelialization by its cytoprotection, anti-apoptosis, and anti-inflammation properties (6). The EPO receptor (EpoR) is a specific cell surface cytokine receptor that induces the expression of several genes and also has biological effects on diverse non-hematopoietic cells (7). The studies have recently revealed that EPO-EpoR signaling has a critical effect on the muscle, kidney, and brain cell proliferation (8). Several studies have demonstrated that the recombinant human EPO (rhEPO) could promote proliferation, differentiation, and migration of endothelial cells by cell matrix breakdown (8). Angiogenesis, which is a physiologic mediator in tissue healing, intercedes by numerous cytokines and growth factors, such as vascular endothelial growth factor (VEGF), platelet, and fibroblast growth factors. This hormone stimulates the formation of new blood vessels in the proliferation phase (8).

Moreover, the interaction between EPO and VEGF for revascularization and remodeling accelerates the process of tissue repair (9). Some of the vascular endothelial cells could mediate angiogenesis for generating fresh blood vessels. In addition, EPO plays a critical role in the central nervous system, gastrointestinal system, muscle and renal cells in case of responding to injury by microvascular remodeling (8). It is assumed that EPO cytokine might be able to accelerate the process of tissue healing through changing the inducible physiological parameters. Therefore, the current study was conducted to compare the beneficial effects of the rhEPO on skin tissue healing in systemic and subcutaneous types of injection and to determine the physiological reaction to tissue damage in murine models.

Methods

Ethical Considerations

The present study was approved by the local animal research institute in Birjand University of Medical Science, Birjand, Iran. Moreover, all the procedures were performed under the supervision of this university and in accordance with the guide for the care and use of laboratory animals provided by the National Institutes of Health. This study was also approved by the research ethics committee (ethics code: REC.1395.221).

Animal Model

This research was performed on 30 male BALB/c mice with a mean weight of 25 ± 5 gr who were within the age range of 10-12 weeks (provided by Pastor Laboratory, Tehran, Iran). They were kept in standard and separate cages with a 12:12-hour light-dark cycle and were fed based on a standard protocol with bottled tap water and pellet food. The surrounding temperature was between 22°C and 24°C and relative humidity was between 45% and 50%.

All the mice were anesthetized intraperitoneally by 70mg per kg ketamine hydrochloride. Subsequently, the backs of the mice were shaved and 25-mm circular wounds were punched in them with 2 cm distance from each other.

The animals were randomly divided into three groups of 10. The first and second groups received 400 U per kg rhEPO (CinnaGen) on a daily basis through systemic and subcutaneous injections (injection into the veins), respectively. The third group which was the control group received a 0.9% sodium chloride solution. Moreover, in each group, three mice were sacrificed due to exposure to an overdose of anesthetic on days 4 and 7 of the research. Furthermore, two other mice were sacrificed after 10 and 14 days. The treatment was given through intraperitoneal injection of EPO and placebo once a day. Images were obtained from the wounds of all the rats in each group on days 4, 7, 10, and 14 of the experiment in order to determine the wound contraction. Furthermore, the biopsies were obtained from 4 mice who were randomly selected from all the groups after euthanization.

Histological Evaluation

The mice were euthanized by ether, in order to discontinue their cardiac and respiration function. Subsequently, the skin biopsies were fixed by 10% formalin solution and all the samples were subjected to standard histological procedures, including dehydration by alcohol which was followed by clearing with Xylene. Moreover, the

tissue samples were embedded in paraffin blocks that were trimmed into thin serial sections (5µm) using the RM2235 rotary microtome (LICA, Germany). In total, 10 slides were randomly chosen and stained by hematoxylin/eosin and Trichrome-Mallory dyes. The tissue-healing scores included the evaluation of variables, such as re-epithelialization, the density of fibroblast, inflammatory cells, and ulcer healing. Afterward, the slides were evaluated by two pathologists using Olympus SZX light microscope at a 400X magnification.

Statistical Analysis

The collected data were analyzed using Wilcoxon signed-rank and analysis of variance tests in SPSS software (version 18.0). Furthermore, all of the images were investigated in ImageJ software. A p-value of <0.05 was considered statistically significant.

Results

I) Microscopic Features of Wound on Day 4

On day 4, inflammation degree of the wound in the group treated with subcutaneous injection of EPO was more than that of the group treated with systemic injection of EPO. In addition, the number of inflammatory cells was significantly lower in both groups that were treated with systemic and subcutaneous injections of rhEPO in comparison with the control group. Moreover, there was no significant difference between other tissue-healing parameters ($P<0.05$) (Table1) (Figure 1).

II) Microscopic Features of Wound on Day 7

On day 7, the number of inflammatory cells was significantly lower in both EPO-treated groups, compared to the control group ($P<0.05$). Moreover, the density of fibroblast cells in EPO-treated groups was higher than the control group. In

Table 1: Microscopic features of the wound in recombinant erythropoietin (systemic and subcutaneous injection) and control group on different days

Days	Parameters	Systemic injection group	Subcutaneous injection group	Control group
Day 4	Inflammatory cells	99.23±8.86	113.60±5.03	136.07±5.0
Day 7	Inflammatory cells	74.73±3.98	97.83±6.20	114.90±5.17
	Fibroblast cells	17.20±1.73	14.43±1.97	13.13±1.89
	Blood vessels	10.77±1.77	7.60±1.30	8.30 ±2.07
Day 10	Inflammatory cells	35.75±4.15	57.45±5.68	65.25±5.41
	Fibroblast cells	20.20±2.01	14.00±1.52	10.95±2.06
	Blood vessels	8.10±1.41	6.10±1.33	3.60±1.14
	Epithelial thickness	85.90±9.35	51.26±7.61	53.85±4.82
Day14	Inflammatory cells	13.25±1.45	15.50±3.9	29.40±3.59
	Fibroblast cells	13.25±1.45	10.85±1.84	7.80±1.67
	Blood vessels	3.50±0.63	3.20±0.95	2.05±0.94
	Epithelial thickness	126.73±11.06	87.63±8.08	53.06±6.51

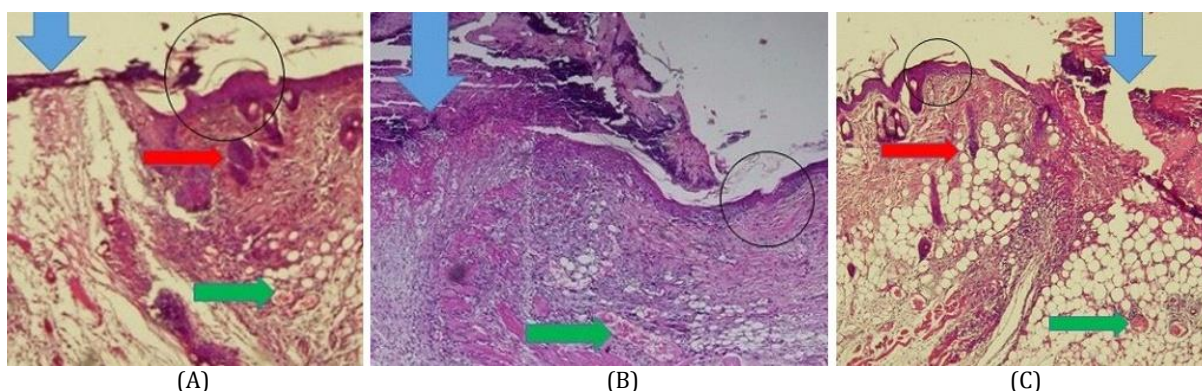


Figure 1: Photomicrograph of skin in control (A), systemic injection (B), and subcutaneous injection (C) groups on day 4 of research. Wound, epidermis, hair follicles, and blood vessels are demonstrated by a blue arrow, black circle, red arrow, and green arrow, respectively. Magnification: 4x. Density of inflammatory cells was higher in systemic injection and subcutaneous injection groups on day 4 of the research, compared to the control group.

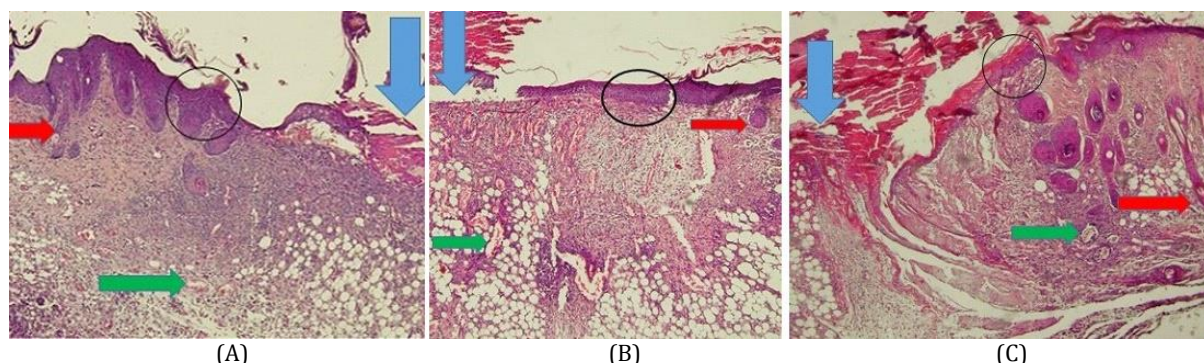


Figure 2: Photomicrograph of skin in control (A), systemic injection (B), and subcutaneous injection (C) groups on day 7 of research. Magnification: 4x. Photomicrograph of erythropoietin in the skin on day 7 of research. Density of inflammatory cells decreased in systemic injection and subcutaneous injection groups on day 7, unlike those in the control group

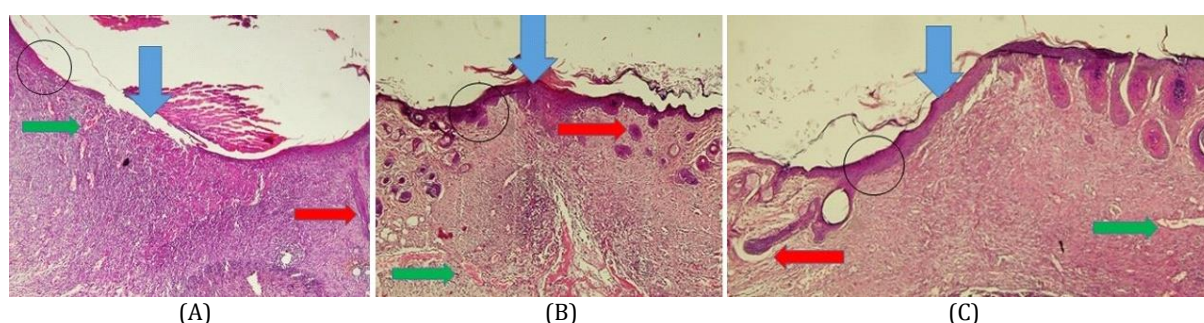


Figure 3: Photomicrograph of skin in control (A), systemic injection (B), and subcutaneous injection (C) groups on day 10 of research. Magnification: 4x. Photomicrograph of erythropoietin in the skin on day 10. Density of inflammatory cells decreased on day 10 while the number of fibroblast cells and epidermis thickness increased in systemic injection and subcutaneous injection groups on day 10, compared to the control group

addition, the number of fibroblast cells increased more in the group that received a systemic injection of EPO, compared to the group treated with subcutaneous injection of EPO. Furthermore, the number of blood vessels in the wound was found to be higher in the group that received a systemic injection of EPO, compared to the control group ($P < 0.05$). However, the number of blood vessels was not significantly lower in the group that received a subcutaneous injection of EPO in comparison to the control group ($P = 0.28$) (Table 1) (Figure 2).

III) Microscopic Features of Wound on Day 10

On day 10, the degree of wound inflammation was significantly lower in both experimental groups, compared to the control group ($P < 0.05$). Moreover, the density of fibroblast cells and new capillary formation was significantly higher in EPO-treated groups, compared to the control group ($P < 0.05$). In addition, the number of fibroblast cells and blood vessels underwent a more significant increase in the group that received a systemic injection of EPO, compared to the group that

received a subcutaneous injection of EPO. In addition, the epidermis thickness of the group treated with systemic injection of EPO was more than that of the control group. However, the epidermis thickness of the group treated with subcutaneous injection of EPO and that of the control group were approximately similar ($P = 0.52$) (Table 1) (Figure 3).

IV) Microscopic Features of Wound on Day 14

On day 14, the number of fibroblast cells and blood vessels, as well as the thickness of the wound marginal epidermis were higher in EPO-treated groups, compared to the control group. Moreover, the number of inflammatory cells was lower in experimental groups, compared to the control group. Furthermore, the number of fibroblast cells and the thickness of the wound marginal epidermis significantly increased in the group that received a systemic injection of EPO in comparison with the control group. Nevertheless, regarding the number of blood vessels, there was no significant difference between the EPO-treated groups ($P = 0.52$) (Table 1) (Figure 4).

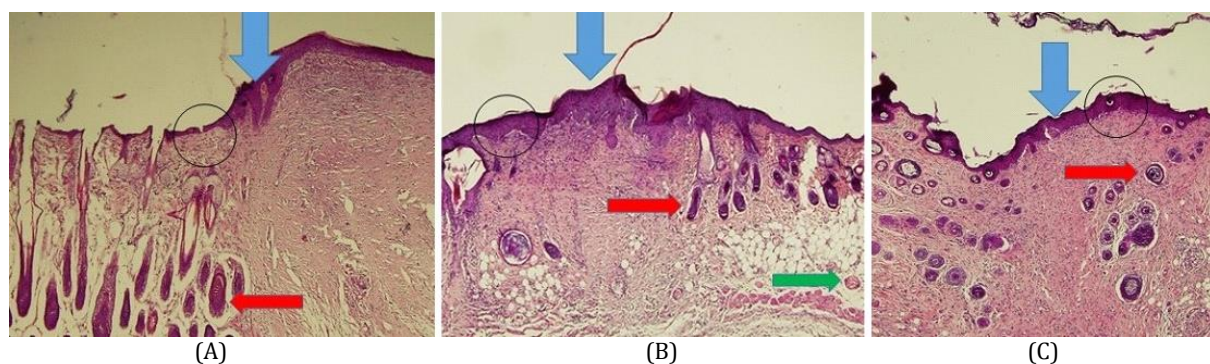


Figure 4: Photomicrograph of skin in control (A), systemic injection (B), and subcutaneous injection (C) groups on day 14 of research. Magnification: 4x. Photomicrograph of skin in erythropoietin on day 14 of research. Density of inflammatory cells was at its lowest level on day 14 and the high number of active fibroblast cells and epidermis thickness were in systemic injection and subcutaneous injection groups on day 14, compared to the control group. Moreover, all of the wounds were improved in all groups (blue arrow)

Increased number of inflammatory cells showed that the basal layer was completely destroyed on day 4. Afterward, reconstruction began on day 7 and reached its maximum level on day 10. Finally, the process of tissue-healing was completed on day 14.

Discussion

Process of tissue-healing consists of two major phases of angiogenesis mediated by growth factors, endothelial cells, and matrix formation by fibroblast and macrophage (8). The EPO is the main cytokine regulating the production of the red blood cells. Based on several previous studies, various biological effects of this glycoprotein hormone include anti-inflammation, generation of blood vessels, and anti-apoptosis (10). The EPO binds to EpoR in erythroid progenitor cells and mediates proliferation and anti-inflammatory effects. The current study aimed to investigate the role of rhEPO in skin tissue-healing and compare the results of systemic and subcutaneous injections in the study groups on different days of treatment.

The usage of EPO has various effects on tissue-healing. In the present in vivo study, the density of inflammatory cells was significantly lower in the EPO-treated groups, compared to the control group. Inflammatory cells had a higher density on day 4; however, the number of these cells decreased throughout the treatment. Moreover, the number of inflammatory cells was lower in the group that received a systemic injection of EPO compared to the group that received a subcutaneous injection of EPO. According to the results of a research performed by Hamed, et al., EPO and fibronectin treatment significantly increased tissue-healing in diabetic mice. In the

above-mentioned study, it was found that the rate of wound closure had a relationship with the reduction of inflammatory cytokines and angiogenesis (11). Furthermore, based on the findings of another study conducted by Harder, et al., the treatment of ischemia with EPO leads to the reduction of inflammatory responses and protects the tissues from apoptotic and necrotic cells. In the aforementioned study, a positive result was observed in tissue-healing 7 days after the systemic injection of EPO (12). This is consistent with the results of the present study which shows that the density of inflammatory cells decreased in both EPO-treated groups during the follow-up days.

According to the results of the previous studies and the present research, this reduction in density of the inflammatory cells in the recovery process is due to the administration of EPO, specifically the systemic injection of EPO, which is more effective than the subcutaneous injection (8).

In the present study, the number of fibroblast cells was higher in EPO-treated groups on all the follow-up days and reached its highest level on day 10. In addition, the highest density of fibroblast cells was observed in the group that received the systemic injection of EPO, compared to others ($P < 0.05$). Based on the findings of the study performed by Heiko, et al. on the effect of repetitive low and high doses of EPO on animal models, the epithelialization of skin wound depends on the basement membrane, keratinocytes, and fibroblast cells. In addition, the aforementioned study found that high doses of EPO could be used as a supplement for tissue-healing. Besides, EPO may reduce the expression of the Smad-2 in epithelialization and keratinocyte signaling (13). The EPO treatment has been

reported to accelerate wound epithelialization and lead to mRNA expression of Smad-dependent TGF- β , as a result of increased differentiation of myofibroblasts and induced wound closure (14). Galeano, et al. suggested that rhEPO is effective in tissue-healing by stimulating tissue formation and dermal repair (15).

Neovascularization and novel capillary formation, as critical phases of tissue-healing, were significantly improved in the EPO-treated groups. In the present study, the formation of blood vessels was higher in EPO-treated groups in comparison with the control group, and it reached its highest level on day 7 in both EPO-treated groups. According to the results of a study carried out by Buemi, et al., the rhEPO administration could increase the VEGF levels to generate new capillaries and angiogenesis. Moreover, it has been found that the presence of oxygen and nutrients are critical in the proliferation and activity of fibroblast cells (16).

In the present study, the epithelial cells were thicker in experimental groups on days 10 and 14, compared to the control group. Moreover, the greatest thickness of the epithelium was observed on day 14 of the experiment. According to Zisgan et al., rhEPO plays a physiological role in tissue-healing by the stimulation of therapeutic angiogenesis and macrophages. They suggested that EPO could provide novel insight in clinical practice through hematopoietic and non-hematopoietic signaling pathways. They also found that EPO may improve the formation of granulation tissues by its pro-angiogenic effects (8). Furthermore, Sayan, et al. in their study showed that rhEPO can be useful for tissue-healing treatment in re-epithelialization and VEGF expression (17).

Chaudhar et al. reported that the administration of Jamun honey is effective in tissue-healing, collagen deposition, and re-epithelialization (18). Moreover, Heidari et al. proposed *Tragopogon graminifolius* due to its antioxidant and anti-inflammatory characteristics and considered it as a herbal medicine for the treatment of burn wounds (19).

In the present study, parameters related to the skin repair process were determined, including the formation of inflammatory cells, proliferation of fibroblast cells, epithelial thickness, and generation of blood vessels. Galeano, et al. showed that EPO accelerated the healing process of burn wounds by stimulation of new capillary and fibroblast cell formation and reduction of inflammatory cell infiltration (20). According to the results of the present study, rhEPO can act as a stimulator for

therapeutic angiogenesis response and endothelial mitogenesis in neovascularization due to its physiological effects. Moreover, the reconstruction process in tissue-healing occurred faster in the group that received a systemic injection of EPO. The EPO could accelerate wound repair by the production of cytokines and necessary growth factors for the healing cascade.

Conclusions

Findings of the present study indicated that rhEPO could accelerate the tissue-healing process, especially in the form of systemic injection. Furthermore, it had a positive effect on the recovery parameters through the enhancement of fibroblast cell formation, as well as the elevation of novel capillary formation density, and epidermis regeneration in the margins of the wound. It is recommended for future studies to investigate the effect of EPO on different parameters related to skin wound repair.

Acknowledgments

The authors of the present study would like to thank the staff of the animal laboratory.

Funding

This research was funded by Birjand University of Medical Sciences, Birjand, Iran.

Conflict of Interest

There is no conflict of interest regarding the publication of this study.

References

1. Afshar M, Ghaderi R, Zardast M, Delshad P. Effects of topical emu oil on burn wounds in the skin of Balb/c mice. *Dermatol Res Pract*. 2016; 2016:6419216. PMID: 27069472 DOI: 10.1155/2016/6419216
2. Maver T, Maver U, Stana Kleinschek K, Smrke DM, Kreft S. A review of herbal medicines in wound healing. *Int J Dermatol*. 2015; 54(7):740-51. PMID: 25808157 DOI: 10.1111/ijd.12766
3. Ghaderi R, Afshar M, Akhbarie H, Gholipour MJ. Comparación de la Eficacia de la Miel y Aceite Animal en la Aceleración de Cicatrización de la Herida en Todo el Espesor de la Piel de Ratón. *Int J Morphol*. 2010; 28(1):193-8. DOI: 10.4067/S0717-95022010000100027
4. Schreml S, Szeimies RM, Prantl L, Landthaler M, Babilas P. Wound healing in the 21st century. *J Am Acad Dermatol*. 2010; 63(5):866-81. PMID: 20576319 DOI: 10.1016/j.jaad.2009.10.048

5. Guo Sa, DiPietro LA. Factors affecting wound healing. *J Dent Res.* 2010; 89(3):219-29. DOI: [10.1177/0022034509359125](https://doi.org/10.1177/0022034509359125)
6. Fatemi MJ, Emami AH, Ghiasi S, Seyed Jafari SM, Mohammadi AA. Effects of recombinant human erythropoietin on revascularization of full thickness skin grafts in rat. *Iran Red Crescent Med J.* 2014; 16(5):e8867. PMID: [25031867](https://pubmed.ncbi.nlm.nih.gov/25031867/) DOI: [10.5812/ircmj.8867](https://doi.org/10.5812/ircmj.8867)
7. Organisers L. 13th annual meeting on surgical research/13. Chirurgische forschungstage 10.-12. September 2009, Hörsaaltrakt Klinikum Großhadern, Munich, Germany. *Langenbecks Arch Surg.* 2009; 394:915-70. DOI: [10.1007/s00423-009-0539-z](https://doi.org/10.1007/s00423-009-0539-z)
8. Haroon ZA, Amin K, Jiang X, Arcasoy MO. A novel role for erythropoietin during fibrin-induced wound-healing response. *Am J Pathol.* 2003; 163(3):993-1000. PMID: [12937140](https://pubmed.ncbi.nlm.nih.gov/12937140/) DOI: [10.1016/S0002-9440\(10\)63459-1](https://doi.org/10.1016/S0002-9440(10)63459-1)
9. Sule Yaşar Bilge N, Dündar E, Mutlu FŞ, Gülbaş Z. Erythropoietin improves the healing of skin necrosis resulting from doxorubicin extravasation in a rat model. *Curr Ther Res Clin Exp.* 2011; 72(4):141-9. PMID: [24648584](https://pubmed.ncbi.nlm.nih.gov/24648584/) DOI: [10.1016/j.curtheres.2011.07.001](https://doi.org/10.1016/j.curtheres.2011.07.001)
10. Zhang W, Ding W, Lü D. Recombinant human erythropoietin promotes angiogenesis by activating SMAD3 and stimulating endothelial progenitor cells during wound healing. *Int J Clin Exp Med.* 2016; 9(2):2849-56.
11. Hamed S, Ullmann Y, Egozi D, Daod E, Hellou E, Ashkar M, et al. Fibronectin potentiates topical erythropoietin-induced wound repair in diabetic mice. *J Invest Dermatol.* 2011; 131(6):1365-74. PMID: [21326299](https://pubmed.ncbi.nlm.nih.gov/21326299/) DOI: [10.1038/jid.2011.15](https://doi.org/10.1038/jid.2011.15)
12. Harder Y, Amon M, Schramm R, Contaldo C, Metzkwow E, Matzen A, et al. Erythropoietin reduces necrosis in critically ischemic myocutaneous tissue by protecting nutritive perfusion in a dose-dependent manner. *Surgery.* 2009; 145(4):372-83. PMID: [19303985](https://pubmed.ncbi.nlm.nih.gov/19303985/) DOI: [10.1016/j.surg.2008.12.001](https://doi.org/10.1016/j.surg.2008.12.001)
13. Sorg H, Krueger C, Schulz T, Menger MD, Schmitz F, Vollmar B. Effects of erythropoietin in skin wound healing are dose related. *FASEB J.* 2009; 23(9):3049-58. PMID: [19403513](https://pubmed.ncbi.nlm.nih.gov/19403513/) DOI: [10.1096/fj.08-109991](https://doi.org/10.1096/fj.08-109991)
14. Siebert N, Xu W, Grambow E, Zechner D, Vollmar B. Erythropoietin improves skin wound healing and activates the TGF- β signaling pathway. *Lab Invest.* 2011; 91(12):1753-65. PMID: [21894148](https://pubmed.ncbi.nlm.nih.gov/21894148/) DOI: [10.1038/labinvest.2011.125](https://doi.org/10.1038/labinvest.2011.125)
15. Galeano M, Altavilla D, Cucinotta D, Russo GT, Calò M, Bitto A, et al. Recombinant human erythropoietin stimulates angiogenesis and wound healing in the genetically diabetic mouse. *Diabetes.* 2004; 53(9):2509-17. PMID: [15331568](https://pubmed.ncbi.nlm.nih.gov/15331568/) DOI: [10.2337/diabetes.53.9.2509](https://doi.org/10.2337/diabetes.53.9.2509)
16. Buemi M, Galeano M, Sturiale A, Ientile R, Crisafulli C, Parisi A, et al. Recombinant human erythropoietin stimulates angiogenesis and healing of ischemic skin wounds. *Shock.* 2004; 22(2):169-73. PMID: [15257091](https://pubmed.ncbi.nlm.nih.gov/15257091/) DOI: [10.1097/01.shk.0000133591.47776.bd](https://doi.org/10.1097/01.shk.0000133591.47776.bd)
17. Sayan H, Ozacmak VH, Guven A, Aktas RG, Ozacmak ID. Erythropoietin stimulates wound healing and angiogenesis in mice. *J Invest Surg.* 2006; 19(3):163-73. PMID: [16809226](https://pubmed.ncbi.nlm.nih.gov/16809226/) DOI: [10.1080/08941930600674694](https://doi.org/10.1080/08941930600674694)
18. Chaudhary A, Bag S, Banerjee P, Chatterjee J. Wound healing efficacy of Jamun honey in diabetic mice model through reepithelialization, collagen deposition and angiogenesis. *J Tradit Complement Med.* 2019; In Press. DOI: [10.1016/j.jtcme.2019.10.002](https://doi.org/10.1016/j.jtcme.2019.10.002)
19. Heidari M, Bahramsoltani R, Abdolghaffari AH, Rahimi R, Esfandyari M, Baeeri M, et al. Efficacy of topical application of standardized extract of *Tragopogon graminifolius* in the healing process of experimental burn wounds. *J Tradit Complement Med.* 2019; 9(1):54-9. PMID: [30671366](https://pubmed.ncbi.nlm.nih.gov/30671366/) DOI: [10.1016/j.jtcme.2018.02.002](https://doi.org/10.1016/j.jtcme.2018.02.002)
20. Galeano M, Altavilla D, Bitto A, Minutoli L, Calò M, Cascio PL, et al. Recombinant human erythropoietin improves angiogenesis and wound healing in experimental burn wounds. *Crit Care Med.* 2006; 34(4):1139-46. PMID: [16484928](https://pubmed.ncbi.nlm.nih.gov/16484928/) DOI: [10.1097/01.CCM.0000206468.18653.EC](https://doi.org/10.1097/01.CCM.0000206468.18653.EC)