




REVIEW ARTICLE

Utilization of the Cabrol shunt in aortic surgery-from the 'wrap technique' to veno-arterial extracorporeal membrane oxygenation setting :A narrative review

Ana Lopez-Marco¹ , Benjamin Adams² , Aung Y. Oo² 

¹PhD, Department of Cardiothoracic Surgery, Barts Heart Centre, St Bartholomew's Hospital, London, United Kingdom

²MD, Department of Cardiothoracic Surgery, Barts Heart Centre, St Bartholomew's Hospital, London, United Kingdom

Received: May 20, 2020

Revised: September 07, 2020

Accepted: October 28, 2020

Abstract

The Cabrol shunt has been broadly used to control postoperative haemorrhage in aortic surgery since its first description in 1981. The initial description and its modifications aim to divert the blood from within the aneurysm wrap and/or the periaortic space to the venous system. We describe a modification in the context of central veno-arterial extracorporeal membrane oxygenation (VA-ECMO) after complex aortic surgery.

A query on the PubMed was carried out using such keywords as 'Cabrol shunt', 'Cabrol fistula', 'Aorta-atrial shunt', 'Perigraft shunt', 'Periaortic baffle', and 'Left-to-right shunts'. Original articles and case reports in which patients had undergone a Cabrol shunt or a modification to divert aortic bleeding to the venous circulation in the context of aortic surgery were included in the study. All publications were limited to the English language. On the other hand, abstracts and conference presentations, editorials, and correspondence comments were excluded. Finally, 18 articles and case reports were retrieved.

A total of 392 cases of Cabrol shunt or a modification have been reported since 1987 with successful control of postoperative bleeding. Long-term results, when available, prove that the addition of a Cabrol shunt does not negatively affect mortality or postoperative complications, rather it decreases re-operation rates, blood transfusion, and hospital stay. Furthermore, the patency of the shunts beyond the immediate postoperative period has been described. The use of a modified Cabrol shunt in the setting of complex aortic surgery can effectively control peri-operative bleeding. Moreover, its application in other complex settings, such as central VA-ECMO, seems satisfactory.

Key words: Aorta, Arteriovenous shunt, Consumption coagulopathy, ECMO treatment, Surgical, Thoracic

Introduction

The Cabrol shunt was first described in 1981 as a technique used for the control of postoperative bleeding in aortic surgery (1). Over the years, the original technique has undergone several modifications, some due to the lack of redundant native aorta to wrap once the preservation of the aneurysmal wall was abandoned in favor to complete resection of the aneurysmal sac, and

others to adapt the technique to particular challenges of the case to repair (i.e., the presence of adhesions on the right atrium) (2-15). We conducted a literature review of the different uses and modifications of the Cabrol shunt through the years, as well as an analysis of the reported results and complications (Table 1). In addition, we report our experience of the Cabrol shunt in the setting of veno-arterial extracorporeal membrane oxygenation (VA-ECMO) following complex aortic surgery.

©2020 Journal of Surgery and Trauma

Tel: +985632381203

Fax: +985632440488

Po Box 97175-379

Email: jsurgery@bums.ac.ir

✉ Correspondence to:

Ana Lopez-Marco, Department of Cardiothoracic Department of Cardiothoracic Surgery, Barts Heart Centre, St Bartholomew's Hospital, London, United Kingdom;

Telephone Number: +440207377000

Email Address: ana.lopez-marco@nhs.net

Table 1: Summary of the case reports containing modifications of the Cabrol shunt, including the number of cases included in the report, aortic surgery procedure, used material, and configuration of the shunt and follow-up status of the patients (when available). AA: ascending aorta; AD: aortic dissection; ARR: aortic root replacement; AVR: aortic valve replacement, CABG: coronary artery bypass grafting, CHF: congestive heart failure, CT: computed tomography scan, Dx: postoperative day, FL: false lumen, IE: infective endocarditis, L-R: left to right, PE: pulmonary embolism, PTFE: polytetrafluoroethylene, RA: right atrium, TTE: trans-thoracic echocardiography

Group	Number	Setting	Modification	Follow-up
Hoover et al. (1987)	9	ARR		Two patent shunts One required closure due to CHF
Blum et al. (1989)	1	Type A AD	Autologous and bovine pericardium	No flow on D2 by TTE
Muehrcke et al. (1989)	1	Re-do ARR for IE	Autologous pericardial patch	Not available
Maisano et al. (1999)	2	Re-do ARR	6-mm PTFE graft between periprosthetic space and innominate vein	Complete occlusion at discharge by TTE
Mancini et al. (1999)	1	ARR with homograft	Hemashield on-lay patch to the aorta and 6-mm Goretex shunt to the RA	Spontaneous thrombosis after a week
Cabrol(1999)	260	Aortic surgery		3 patients with persistent L-R shunts, 2 of them required intervention
Vogt et al. (2001)	1	Aortic surgery	Xenopericardium over the anterior mediastinum draining to the innominate vein by an 8-mm PTFE shunt	
Posacioglu et al. (2002)	7	Type A AD	Pericardial patch over the perigraft space directing blood to the RA	All shunts occluded before discharge (by TTE) No pseudoaneurysms on CT
Kao et al.(2003)	2	1) Type-A AD 2) ARR+CABG	Pericardial patch over the perigraft space directing blood to the RA	Spontaneous closure of the shunts at 1 week and 3 months, respectively
Salerno et al. (2008)	1	Re-do AVR requiring AA replacement	Bovine pericardial patch and 6-mm Hemashield graft to the RA	Not available
Panos et al. (2009)	1		Remnant of the aneurysm diverted by a 6-mm Hemashield graft to the RA	Patency at discharge demonstrated by CT
Okumu et al. (2010)	1	Decompression of FL in iatrogenic AD	Not specified	Patency of the shunt confirmed by CT
von Knobelsdorff-Brenkenhoff et al. (2010)	1	Aortic dissection	8-mm shunt to connect the perigraft space and the RA	Patency of the shunt at 4 years causing severe right heart enlargement and dysfunction
Kitamura et al. (2012)	1	Complex reconstruction post-IE	2 aortic sheet grafts drained to the RA by 2-8mm tube grafts anastomosed side-to-side	Stable appearances of periaortic space at 1 year CT
Eleftheriades et al.(2012)	2	ARR	Contegra graft	No complications Spontaneous closure of the fistula at discharge
Yang et al.(2014)	1	Type A AD	Shunt from periaortic space to RA	D2 PE from the RA shunt treated medically No flow in the periaortic space D4
Toole at al. (2014)	23	Aortic surgery	Bovine pericardial patch	six patients with the patent shunt, one required reintervention for closure
Zhang et al. (2019)	76	Type A AD	Bovine pericardial patch aortic coverage	All fistulas closed spontaneously in a few days postoperation No shunt-related complications or mortality
Savic et al. (2019)	1	Perigraft infection		Patent fistula at reintervention



Methods

Literature search strategy

An electronic query was carried out on the PubMed database using 'Cabrol shunt', 'Cabrol fistula', 'Aorta-atrial shunt', 'Perigraft shunt', 'Periaortic baffle' and 'Left-to-right shunt' as keywords.

Inclusion and exclusion criteria

Original articles and case reports in which patients underwent a Cabrol shunt or a modification of the original technique to divert aortic bleeding to the venous circulation in the context of aortic surgery were included in the study. All publications were limited to the English language. On the other hand, abstracts and conference presentations were excluded.

Results

We identified 18 case reports or original articles that fulfilled the inclusion criteria. An editorial comment by Cabrol was also included in the analysis since it provided the largest number of reported patients (Table 1).

Modifications of the Cabrol shunt

The Cabrol shunt was first described in 1981 by Cabrol as the final step of the aortic root replacement with reimplantation of the coronary arteries procedure. It included leaving the native aortic aneurysm and wrapping it around the artificial aortic graft. It was considered an effective surgical maneuver to deal with uncontrollable aortic bleeding by creating a fistula between the aneurysm sac and the right atrial appendage. It combined the principles of autologous blood transfusion and the promotion of hemostasis by decompressing the periaortic graft space (1).

The original description implied suturing a 6-mm Dacron graft from an opening within the aneurysm sac to a created orifice in the right atrial appendage. Cabrol later abandoned the use of the Dacron graft and replaced it by connecting the tip of the right atrial appendage to the aneurysm sac (2) (Figures 1 and 2). Further modifications were described by connecting the 6-mm graft between the aneurysm sac and the innominate vein (3, 4). In other cases, when there was a fusion plane between the aneurysm and the right atrium, modifications

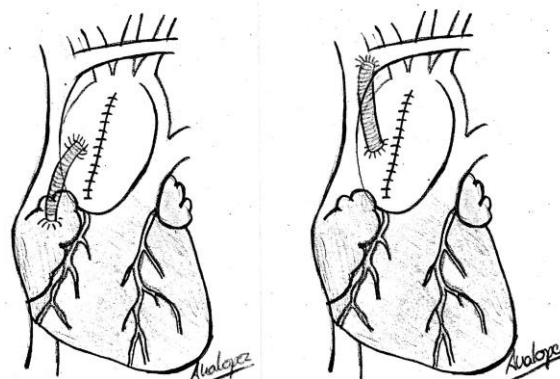


Figure 1: Original description of the Cabrol shunt, using a 6-mm graft connected from an opening in the aneurysm sac to the right atrial appendage (left) or to the innominate vein (right)

were made by creating an internal shunt from the aneurysm wall to the right atrium using a 6mm aortic punch (3) (Figures 1 and 2).

The inclusion technique (aneurysm wrap) was soon discontinued in favor of the open technique reported by Kouchoukous (5). It did allow the resection of the entire diseased aorta with more precise suturing and access to posterior aortic areas. Nevertheless, it eliminated the possibility of wrapping the graft with the excess tissue in the event of troublesome bleeding.

In 1989, Blum et al. reported an acute type A aortic dissection case treated with ascending aorta

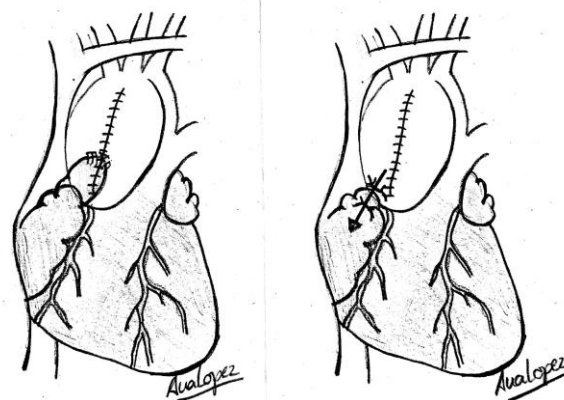


Figure 2: Modification of the Cabrol shunt, connecting the tip of the right atrial appendage to an opening in the aneurysm sac (left) or by creating an internal shunt from the aneurysm sac to the right atrial appendage using an aortic punch (right)

and arch replacement complicated by persistent bleeding. Their solution was to reinstitute cardiopulmonary bypass (CPB) and suture autologous pericardium to the proximal and distal aortic anastomosis on the posterior aspect of the graft. A bovine pericardium patch was then anastomosed to the distal anastomosis, the edge of the autologous pericardial patch, the conus, and the right atrium. The remaining edge was sutured over the atriotomy site after weaning from CPB and decannulation of the right atrium (6).

Muerhcke also described similar patch coverage on a patient who had a re-do root replacement due to infective endocarditis. They used a flap of autologous pericardium mobilized from the right lateral edge, sutured along the superior vena cava (SVC), the superior margin of the right atrium, the anterior aorta, and down to the left of the aortic root. Once the patch was nearly completed, a 1-cm fistula was made in the roof of the right atrium, and the proximal suture line was then completed to control the bleeding (7).

Ten years later, Mancini et al. described another modification following a homograft root replacement complicated by cardiac tamponade due to a persistent leak from the proximal anastomosis that was not amenable to stop by direct suture repair. They created a watertight seal around the homograft with a portion of a Hemashield tube graft fashioned as an on-lay patch to the native aorta. A 6-mm Goretex graft was anastomosed between the patch and the right atrium (8) (Figure 3).

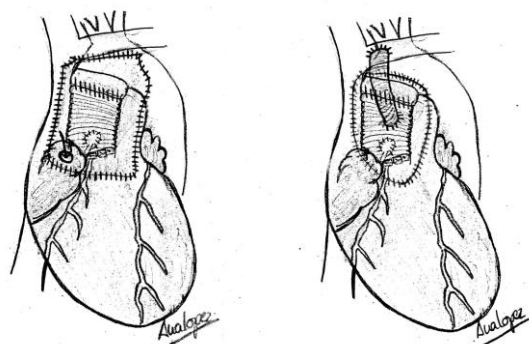


Figure 3: Modification of the Cabrol shunt using a pericardial patch to exclude the periaortic space by anastomosing it to the inferior border of the innominate vein, the medial aspect of the superior vena cava and right atrial appendage, the epicardium of the right ventricle, and the pulmonary artery. A small stab incision is made in the right atrial appendage before completing the inferior suture to divert the flow to the right atrium (left). Alternatively, the flow can be diverted by anastomosing a 6-8mm interposition graft into an opening of the patch and end-to-side to the right atrial appendage (right).

In 2001 and 2002, Vogt and Posacioglu teams described a very similar modification consisting of suturing either an autologous or a pericardial patch to the following boundaries: inferiorly at the epicardium of the right ventricular wall, laterally to the adventitia of the pulmonary artery, superiorly to the inferior border of the innominate vein or the Teflon felt at the distal suture, and medially to the lateral aspect of the SVC towards the base of the right atrial appendage. Before the completion of the suture line, a large stab wound was created on the medial aspect of the right atrium (Figure 3). The SVC is completely excluded from the periaortic space where higher pressure might persist despite an efficient shunt. Great care should be taken when closing the transverse sinus and suturing the proximal left-hand side of the pericardium to the proximal pulmonary trunk before suturing the patch to prevent posterior leakages of blood into the pericardium (9, 10).

In 2003, Kao reported two cases following the same modification; nonetheless, one of them required an elective saphenous vein graft to the left anterior descending artery. Thereafter, the pericardial patch had to be sutured to the neo-aorta medial to the vein graft. This modification enabled them to achieve hemostasis with the preservation of graft flow after coronary bypass grafting (11). In their study in 2008, Salerno et al. (12) reported the modification of their own previous technique (6) by combining the periaortic bovine pericardial graft with the 6-mm Hemashield graft to redirect the blood to the innominate vein. They argued that this modification made the technique more applicable to situations when the right atrium is stuck due to previous adhesions or is thin and friable. One year later, the same group (13) reported another case of root replacement with troubleshooting bleeding. At this point, they had preserved the aneurysm sac which allowed them to suture it circumferentially to the interposition graft line above the level of the Cabrol coronary shunt. It created a shell around the root, and the blood was diverted from there to the right atrium with a 6-mm Hemashield graft.

Along the same lines, Kitamura et al. (2012) presented another modification of the Cabrol shunt to control bleeding in infective endocarditis cases that required extensive reconstruction, including root and mitral valve replacement, as well as the combination of autologous and pericardial patches to reconstruct the left and right atrial wall. Despite three periods of aortic cross-clamp, the aortic bleeding was not controllable. They did wrap the distal aortic anastomosis with a Teflon felt strip that was then sutured with the surrounding tissue. The newly created perigraft space was then closed up

with a sheet of aortic graft and re-routed to the right atrium using an 8-mm tube graft. When CPB was discontinued, there was still active bleeding from underneath the aorta in the portion outside the patch. Another piece of the graft was then anastomosed to isolate the space, and another 8-mm graft re-routed the flow in the space to the previous 8-mm graft by side-to-side-anastomosis. One of the patients required associate coronary artery bypass graft, and the proximal anastomosis of the vein graft was performed to the brachiocephalic trunk (14). Another modification has been reported by Elefteriades. He favored the use of a valved bovine jugular graft (Contegra®) to ensure unidirectional flow and eliminate venous back bleeding into the perigraft space. (15)

As evidenced by the aforementioned reports, the Cabrol shunt is a very effective method to control bleeding after complex aortic surgery used in the event of failure of other methods and severe coagulopathy. The bleeding was immediately controlled in all cases after the construction of the shunt, and none of the patients was reported to require re-exploration for hemorrhage. The patency of the shunt has been evaluated by Doppler transthoracic echocardiography (4, 6, 10, 11, 15, 16), CT (10, 13, 14, 17), and/or MRI (18).

The CT scan is also useful to assess the appearance of the peri-aortic space and rule out Cabrol shunt complications, such as the development of pseudoaneurysms on the suture line. Shunt patency was reported in 15 patients at some point during the follow-up, out of whom only four cases required re-intervention due to associated symptoms. Toole et al. analyzed their experience of periaortic baffles (n=23) and compared their results to similar aortic cases that did not require the baffle construction. The use of a modified Cabrol shunt did not increase the mortality; nonetheless, prolonged ventilation was more common in those who received the shunt. They identified infective endocarditis, re-do sternotomy, and male gender as pre-operative predictors of intra-operative baffle placement (19).

Zhang et al. reported one of the largest series of Cabrol shunts (n=76) and made a comparison with equivalent aortic cases that did not receive the shunt. The use of a Cabrol shunt was associated with less amount of postoperative blood drainage, less rate of red cell transfusion, shorter chest closure time, and no need for re-explorations for bleeding. In terms of associated complications, the Cabrol shunt group had a shorter ventilator support period, less incidence of haemofiltration, shorter ICU and hospital stay, as well as lower 30-day mortality (20).

However, in certain cases, due to prolonged patency of the systemic-to-pulmonary shunt, the use of a Cabrol shunt led to some complications, such as right ventricular failure (18) and pulmonary embolism (16). Years after the operation, the patency of the shunt was not always associated with symptoms or right ventricular overload; therefore, elective closure should be evaluated individually (21) (Table 1).

Cabrol shunt has been recently used in the setting of VA-ECMO post aortic surgery, apart from uncontrollable bleeding following complex aortic cases. Three patients have required VA-ECMO at our institution since 2018. They underwent extensive type A aortic dissection repair requiring total arch replacement and frozen elephant trunk (FET) repair of the descending thoracic aorta. In all three cases, acute right ventricular failure occurred shortly after the discontinuation of CPB and the protamine and blood product administration.

Despite further resting on CPB and addition of a vein graft to the right coronary artery in two of the occasions, it was not possible to wean any of the cases from CPB. We escalated the circulatory support by inserting an intra-aortic balloon pump (IABP) and converting it to the VA-ECMO circuit. We routinely insert the IABP in these cases antegradely, introduce the balloon into the chest via the second intercostal space and then into the aortic arch by puncture of the graft of the Thoraflex hybrid prosthesis (Vascutek®) and use the introducer sheath to avoid kinks. By introducing IABP antegradely under epiaortic ultrasound and transoesophageal echocardiography, we avoid IABP insertion into the false lumen and maintain a satisfactory position within FET rather than retrograde insertion via the femoral artery (Figure 4).

The ECMO cannulation strategy consisted of central arterial cannulation through the sidearm of the aortic graft on the Thoraflex prosthesis and central or peripheral venous cannulation via the right atrium or right femoral vein, respectively, depending on the achievement of adequate flows. After the VA-ECMO institution, we leave the sternotomy opened and the mediastinum packed with swabs. These patients are already coagulopathic after such a lengthy and complex operation and require further anticoagulation for the ECMO circuit.

It is found that without the creation of the modified Cabrol shunt, these patients require frequent change of the mediastinal packs, as well as massive transfusion with subsequent complications. For the construction of the Cabrol shunt, we use a bovine pericardial patch and anastomose it with a continuous 5-0 Prolene suture to the following

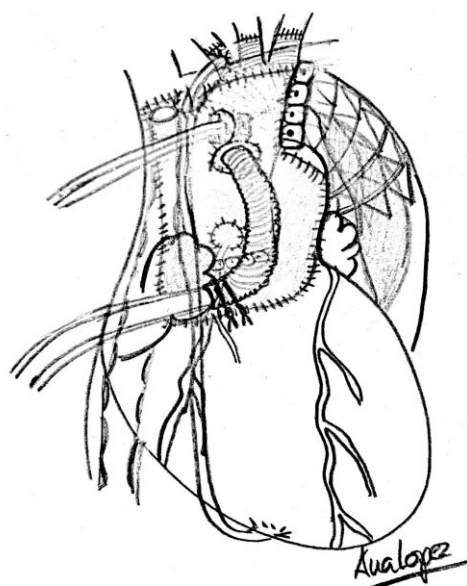


Figure 4: Modification of the Cabrol shunt used in patients with central venoarterial extracorporeal membrane oxygenation after complex aortic surgery, the figure represents a patient who had undergone aortic root, ascending, total arch, and frozen elephant trunk repair of the descending thoracic aorta. In an attempt to improve the impaired right ventricular function, an intra-aortic balloon pump (IABP) was antegradely inserted into the aortic graft using a sheath via the second intercostal space, and a saphenous vein graft was anastomosed to the right coronary artery (proximal anastomosis to the innominate artery). Note the central veno-arterial cannulation strategy: arterial cannula through the sidearm of the Thoraflex® prosthesis, and multistage venous cannula placed percutaneously from the femoral vein visible inside the vena cava and right atrium.

The pericardial patch used for the Cabrol shunt is anastomosed to the inferior border of the innominate vein, the medial aspect of the superior vena cava and right atrial appendage, the epicardium of the right ventricle, and the pulmonary artery, leaving small openings to accommodate the IABP, the aortic cannula, and the bypass graft.

landmarks: superiorly to the inferior border of the innominate vein; laterally to the adventitia of the main pulmonary artery, inferiorly to the epicardium of the right ventricle, and medially to the medial aspect of the SVC.

Our modification for the previously reported techniques consisted of accommodating the shape of the patch to the IABP and arterial ECMO cannula entries, as well as the saphenous vein graft (if exists). It has to be made sure that the patch creates a seal around them but not too tight to occlude or kink them (Figures 4 and 5). The shunt diverts the

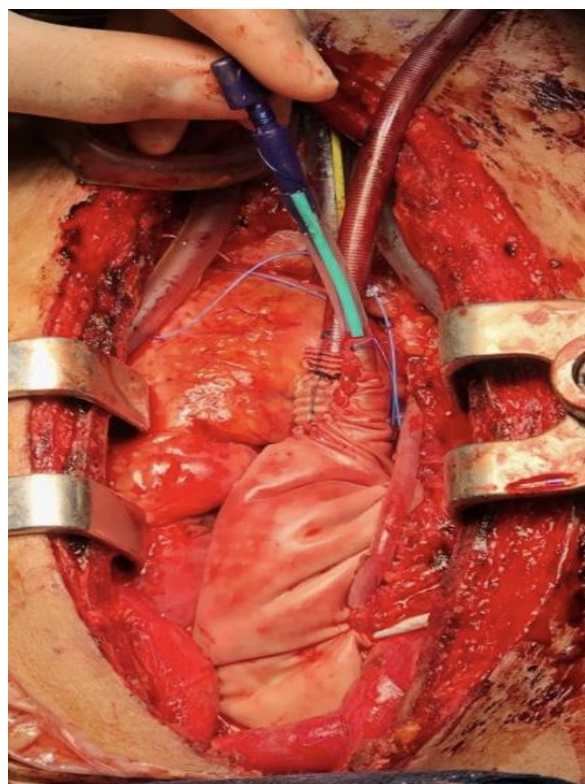


Figure 5: Operative picture of the Cabrol shunt used in a patient with central venoarterial extracorporeal membrane oxygenation. Note the arterial cannula inserted via the sidearm of the Thoraflex® graft and the intra-aortic balloon pump sheath visible entering the chest at the 2nd intercostal space level

blood collected in the created peri-aortic space to the right atrial appendage by creating a stab before suturing the last end of the patch.

We have also used the modification of diverting the blood to the innominate vein by the central venous cannula when the right atrium is occupied (Figure 5). In all our cases, we had to revisit the chest to change the packs and wean the ECMO if/when appropriately. In one of the cases, the suture line onto the SVC was placed too laterally, and the accumulation of blood in the Cabrol space compressed the SVC and negatively affected the ECMO flows. In this case, we had to reconstruct the Cabrol shunt and place it more medially onto the SVC. Moreover, we inserted a second venous cannula into the SVC to increase the venous return into the ECMO circuit.

Furthermore, where the reduced flow was explained by the external compression of the accumulating clot, we did not observe any negative impact of the left-to-right shunt on the VA-ECMO circuit. In all three cases, we have demonstrated that the periaortic space within the Cabrol shunt was already clotted within the first 24 hours. None

of the patients required re-exploration for bleeding, although after 24-48 hours, we routinely changed the mediastinal packs to avoid infection.

Discussion

The use of the Cabrol shunt should be considered when excessive bleeding occurs in an extensive aortic procedure. It is not a substitute for a meticulous surgical technique. Nevertheless, despite careful surgical hemostasis and the use of adjunct hemostatic agents, bleeding remains a problem after a lengthy complex aortic operation. The flow is low in the artificial fistula or periaortic space created. Therefore, it is a common finding of spontaneous closure of the shunt once the mediastinal bleed is controlled by the recovery of the clotting factors.

In certain circumstances, the shunt remains patent with the flow being determined by the peak systolic pressure. Based on the findings on congenital cardiac lesions involving left-to-right shunts, blood flows up to 1.5 times the systemic flow can be well tolerated. If the surgical technique has been appropriate, the leakage from the suture line has been reported ranging up to 350 ml/min, equivalent to the 8% of the cardiac output; therefore, it is hemodynamically and clinically insignificant (3).

Over the years, different materials have been used for the creation of the Cabrol shunt, including autologous or bovine pericardium, Hemashield, Goretex and Polytetrafluoroethylene (PTFE) grafts, as well as Contegra conduits. The advocates of the Hemashield graft justify their choice by the hemostatic properties of the graft and its pliability (8). We prefer the use of bovine pericardium since it has good sealing properties, is readily available, and easy to handle and adjust around the cannula and vein grafts if applicable. Those who prefer to use a side graft to divert the periaortic space to the venous system, advocate sizes between 6 and 8 mm to minimize the risk of cardiac failure from rapid shunt flow but still allowing adequate drainage (4, 8, 14, 18). The notable limitations of the present study include its mere descriptive design and the potential selection bias. Moreover, the reports available in the literature confirm the success of the technique but do not elaborate on the associated complications.

Conclusions

The use of the Cabrol shunt or any of the reported modifications is an effective method for the control of troublesome postoperative bleeding in aortic

surgery. The addition of this maneuver does not seem to increase mortality but associated complications to long-term patency have been reported. We have extended its use to more complex scenarios, including, central VA-ECMO setting following complex aortic surgery. In these situations, the patient requires further anticoagulation, and the chest has to be left open. In the current study, creating the Cabrol shunt ensured the maintenance of the ECMO flows by the elimination of probable cardiac tamponade scenarios.

Conflict of Interest

The authors declare that they have no conflict of interest regarding the publication of the current article.

References

1. Cabrol C, Pavie A, Gandjbakhch I, Villemot JP, Guiraudon G, Laughlin L et al. Complete replacement of ascending aorta with re-implantation of the coronary arteries: a new surgical approach. *J Thorac Cardiovasc Surg.* 1981;81:209-215.
2. Cabrol C. Invited commentary of Mancini MC, Cush EM. Shunt control of bleeding after homograft replacement of the ascending aorta. *Ann Thorac Surg.* 1999;67:1162-1163.
3. Hoover EL, Hsu HK, Ergin A, Ketosugbo A, Webb H, Kharmia B et al. Left-to-right shunts in control of bleeding following surgery for aneurysms of the ascending aorta. *Chest* 1987;91:844-849.
4. Maisano F, Lorusso R, Alfieri O. The periprosthetic sac-innominate vein shunt: An effective way to control bleeding after aortic root operations. *J Thorac Cardiovasc Surg.* 1995;109(2):396.
5. Kouchoykos NT. Inclusion (aneurysm wrap) technique for composite graft replacement of the ascending aorta and aortic valve [Letter]. *J Thorac Cardiovasc Surg.* 1988;96:967.
6. Blum M, Panos A, Lichtenstein SV, Salerno TA. Modified Cabrol shunt for control of haemorrhage in repair of type A dissection of the aorta. *Ann Thorac Surg.* 1989;43:709-711.
7. Muehrcke DD, Szarnicki RJ. Use of pericardium to control bleeding after ascending aortic graft replacement. *Ann Thorac Surg.* 1989;48:706-708.
8. Mancini MC, Cush EM. Shunt control of bleeding after homograft replacement of the ascending aorta. *Ann Thorac Surg.* 1999;67:1162-1163.
9. Vogt PR, Akinturk H, Bettex DA, Schmidlin D, Lachat ML, Turina MI. Modification of surgical aorta-atrial shunt for inaccessible bleeding in aortic surgery. *Thorac Cardiovasc Surg.* 2001;49:240-242.

10. Posacioglu H, Apaydin AZ, Calkavur T, Yagdi T, Islamoglu F. Perigraft to right atrial shunt by using autologous pericardium for control of bleeding in acute type A dissections. *Ann Thorac Surg.* 2002;74:1071-1074.
11. Kao CL, Chan JP. Perigraft-to-right atrial shunt for aortic root hemostasis. *Tex Heart Inst J.* 2003;30:205-207.
12. Salerno TA, Enisa MF, Panos AL, Ricci M. Modified Cabrol shunt after complex aortic surgery. *Ann ThoracSurg.* 2008;86:669-670.
13. Panos AL, Suarez M, Salerno TA, Ricci M. Unusual modification of the Cabrol shunt for control of haemorrhage in acute type A aortic dissection. *J Cardiac Surg.* 2009;24(5):544-546.
14. Kitamura T, Kinoshita O, Ono M. Radical surgery repair with stepwise Cabrol shunt for severe prosthetic valve endocarditis. *Interact Cardiovasc ThoracSurg.* 2012;14(5):689-691.
15. Elefteriades JA, Youssef S, Rousou L, Nazer R. Novel valved graft modification of Cabrol fistula for bleeding after aortic root surgery. *Ann ThoracSurg.* 2012; 94:1741-1743.
16. Yang WJ, Duan QJ, Chein HF, Dong AQ. A case study of pulmonary embolism from the right atrial shunt after acute type A aortic dissection surgery. *Journal of Cardiothoracic Surgery.* 2014;9:180.
17. Okumu RO, O'Donnell D, McCreery CJ, Luke D, Dodd JD. Cabrol shunt for iatrogenic aortic dissection: evaluation with cardiac 64-slice CT. *Eur Heart J.* 2008;29:617.
18. von Knobelsdorff-Brenkenhoff F, Buschmann EE, Pilz B, MD, Schulz-Menger J. Persistent Cabrol shunt causing severe right heart failure. *Ann Thorac Surg.* 2010;90:312.
19. Toole JM, Stroud MR, Ikonomidis JS. Salvage periaortic pericardial baffle equalizes mortality in bleeding patients undergoing aortic surgery. *J Thorac CardiovascSurg.* 2014;148:151-155.
20. Zhang H, Wu X, Fang G, Qiu Z, Chen L. Is it justified to apply a modified Cabrol fistula in surgical repair of acute type A aortic dissection? *J Thorac Cardiovasc Surg.* 2019;doi: 10.1016/j.jtcvs.2018.12.082.
21. Savic V, Schmiady MO, Khargi K, Maisano F, Mestres CA. How does a Cabrol fistula look at reoperation? *Ann ThoracSurg.* 2019; May 15.