

## Aggressive approach to complicated appendicitis in children

Ali Jangjoo<sup>1</sup>, Kamran Aminian<sup>2</sup>, Reza Shojaeian<sup>3</sup>✉

<sup>1</sup>Associate Professor, Surgical Oncology Research Center, Imam Reza Hospital, Faculty of Medicine, Mashhad University of Medical Sciences, Mashhad, Iran;

<sup>2</sup>General Surgeon, Department of General Surgery, Mashhad University of Medical Sciences, Mashhad, Iran;

<sup>3</sup>Assistant Professor, Department of Pediatric Surgery, Mashhad university of Medical Sciences, Mashhad, Iran.

Received: 19 July 2013

Revised: 22 October 2013

Accepted: 27 October 2013

### Abstract

**Objective(s):** Appendicitis remains the most common condition in the pediatric population requiring emergency abdominal operation. Management of acute simple appendicitis is well described but controversy remains as to the optimal treatment of complicated appendicitis. Common complications of acute appendicitis include: localized peritonitis and abscess formation, flegmon and general peritonitis.

**Methods:** In this prospective study we have evaluated the results of aggressive therapy in management of complicated appendicitis in children in Sarvar pediatric hospital of Mashhad, Iran.

**Results:** Among 60 children with acute complicated appendicitis male to female ratio was 4:1 and mean age was 7.18±2.17 years. 60% were operated via low mid line incision and 40% by Rocky Davis incision. The most common final diagnosis was appendicular abscess that was observed in 34 patients. Primary wound closure was performed in 96.7% and placement of drain in peritoneal cavity in right lower quadrant was done only in 13.3%. Safe appendectomy was performed in all 60 cases and post operative complications included two cases with wound infection and 4 cases with Chronic abdominal pain that were managed conservatively. Only one patient was readmitted and underwent re-laparotomy because of bowel obstruction.

**Conclusions:** according to our findings the current non operative approach to complicated appendicitis in children needs a revision.

**Key Words:** Pediatric; Appendicitis; Complicated; Management

### Introduction

Appendicitis is a common surgical disease that can present across a broad spectrum of symptoms and pathologies [1, 2]. An individual's lifetime risk for appendicitis is approximately 8% [3]. While adults are often able to give an accurate history of the prodrome of symptoms experienced, children are less likely to be reliable historians given their age. This is one reason that many younger children present with more advanced appendicitis involving perforation and possible abscess formation [4, 5].

Appendicitis remains the most common condition in the pediatric population requiring emergency abdominal operation; Those with acute suppurative appendicitis can expect an uneventful

recovery with a short hospital stay, while those with perforated or gangrenous appendicitis are fraught with

potential complications, primarily infectious in nature. While much has been written in the literature about appendicitis and the management of acute appendicitis is well described [6], controversy remains as to the optimal treatment of complicated appendicitis [7–9]. Common complications of acute appendicitis include: localized peritonitis and abscess formation, flegmon and general peritonitis [10].

Peritonitis mandates urgent surgery but flegmon is managed by conservative approach and antibiotic therapy for couple of day till clinical and

©2013 Journal of Surgery and Trauma

Tel: +985614443041 (636)

Fax: +985614440488

Po Bax 97175-379

Email: jsurgery@bums.ac.ir



✉ Correspondence to:

Reza Shojaeian, Department of pediatric Surgery, Mashhad university of Medical Sciences, Mashhad, Iran. Telephone

Number: +985117284448

Email Address: drshojaeian@ymail.com

Para clinical signs subside and they would underwent delay operation for appendectomy 2 months later. In this approach patients have to admit in hospi

tal again which is time and many consuming. Those who advocate this approach, suggest that appendectomy is not feasible in the presence of severe inflammation. So in this article we aimed to evaluate the results of aggressive approach in treatment of complicated appendicitis in children and tried to performed the curative final intervention in acute inflammatory phase at the time of admission and evaluate the complications in fallow up period.

## Methods

In this prospective study , the results of the new approach for complicated appendicitis in children was immediate laparotomy and Extracorporeal appendectomy and management of complicated situation by irrigation and lavage of peritoneal cavity or drainage was evaluated and special check lists were filled out for each case.

The advantages of this method include no need to further treatment and readmission ,time and cost saving, shorter hospital stay, fewer hospitalization induce complications such as nosocomial infections, prevent missing cases and performing final treatment in one stage and local control of infection and not to let the pus to spread in peritoneal cavity. Disadvantages of method include safe appendectomy may not be feasible, operation in inflamed and contaminate filed my lead to infectious complications such as intra abdominal abscess or wound infection, probability of bowel laceration, wound infection.

After clinical examination and primary assessment those children with proven diagnosis of complicated appendicitis who weren't high risk for operation were include in this trial. After admission in pediatric surgery ward and primary resuscitation, patients kept NPO at least for 6 hours and antibiotic therapy was initiated and laparotomy via a mid line or Rocky davice (for

ability of extending the incision if needed) incision was performed under general anesthesia.

First the infected and inflamed area was walled off by abdominal pads and if the inflammation was localized to the RLQ we didn't extend the incision and only local irrigation of RLQ and pelvic cavity was performed. Complete irrigation was done in the presence of generalized peritonitis. If there was a severe omental adhesion, partial omentectomy was done to prevent further deserosation. Tying the omentom was done by silk strings. Appendix and inflamed tissues were exteriorized in to the out of abdominal cavity if possible and in order to do this we opened the white line if needed and appendectomy was done out of the abdominal cavity . omental and visceral wall off were broken down gently by finger fracture method and a safe appendectomy was done and drain placement and primary wound closure was on the basis of surgeon judgment. If there was a fine deserosation it remained intact but large deserosations were repaired by Lambert sutures using 4-0 silk.

Finally patients were fallowed in the ward during post operative days and also as outpatients and they evaluated for early and late complications for at least one month. Information's were collected according to our check list and also by direct calling to the families by phone.

Data was collected in the form of special questionnaires and was analyzed by SPSS software (Ver 11.5) results were showed as tables and figures as needed.

## Results

Among 60 children with acute complicated appendicitis 48 patients were male and 12 patients were female. Mean age was  $7.18 \pm 2.17$  years (range from 3 to 13 years).

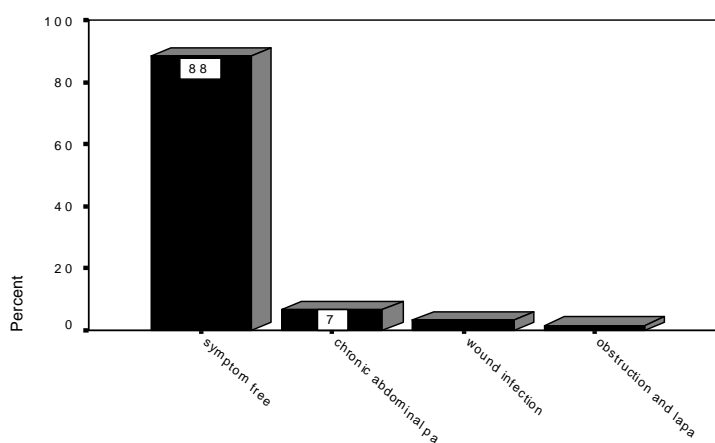
Sonographic evaluation was also performed in 34 cases out of 60 and reports in US evaluation were inflammatory mass (19), Collection (8), Gangrened appendicitis (7).

**Table 1: Clinical and paraclinical findings patients with acute complicated appendicitis who underwent surgery in Sarvar hospital**

Variable	Mean $\pm$ sd	Min-Mox
White blood cell count	15410.7 $\pm$ 4845.7	7700-31800
Polymorphonuclear cell (%)	81.75 $\pm$ 7.43 %.	51%-95%.
Temperature( $^{\circ}$ c)	37.91 $\pm$ 0.8 $^{\circ}$ c	36.5 $^{\circ}$ c-41 $^{\circ}$ c
Duration of pain(days)	3.73 $\pm$ 2.64	1-12 days

**Table 2: Frequency of different pre and post-operative diagnosis among patients with acute complicated appendicitis who underwent surgery in Dr Sheikh hospital**

diagnosis	Pre-operative	Post-operative
Abscess	32 (53.2%)	34 (56.7%)
Localized peritonitis	10 (16.7%)	11 (18.3%)
Flegmon	7 (11.7%)	11 (18.3%)
Gangranized Peritonitis	11 (18.4%)	4 (6.7%)
Total	60 (100.0%)	60 (100.0%)

**chart 1: Frequency post operative complications among patients with acute complicated appendicitis who underwent surgery in Sarvar hospital**

The most common pre-operative diagnosis at the time of admission according to clinical finding in physical examinations and paraclinical findings such as cell blood counts and sonography was appendicular abscess that was observed in 32 cases. Pre and Post operative diagnosis are shown in table 2.

Laparotomy was performed via a low mid line incision in 36 patients and by Rocky Davis incision in 24 patients. Primary wound closure was performed in 58 patients and delay closure by second intention was done only in 2 cases. Placement of drain in peritoneal cavity in right lower quadrant was done only in 8 cases. The most common antibiotic combination which was Prescribed in our patients was Keflin+ Amikacin +Metronidazole and besides Ceftriaxone, Ampicilin and Gentamicin were also used in occasions.

Mean post operative antibiotic therapy time was  $5.97 \pm 2.16$  days (range from 2 to 11 days). Mean time of hospital stay was  $6.08 \pm 2.14$ . (Range from 2 to 11 days). Safe appendectomy was performed in all 60 cases and Post operative complications were evaluated during few post operation days in the ward and also as outpatients in long term follow up. Early complications consist of two cases with

wound infection that were managed by drainage and irrigation. Chronic abdominal pain was reported in 4 cases during long term follow up that were managed conservatively and only one patient was re admitted and underwent re-laparotomy because of bowel obstruction (Figure 1).

## Discussion

The treatment of appendicitis has been continuously refined over the more than 100 years since the disease process was described by Fitz in 1886 [11]. The most significant advances are attributed to early diagnosis, antibiotics, and improvements in surgical and anesthetic techniques. The mortality has been reduced to nearly 0% in recent series of children [12-15].

The management of acute appendicitis with immediate appendectomy has been well established and is certainly an acceptable approach in all cases with a well-described and expected morbidity and mortality [16]. However, the operative procedure can be much more challenging and potentially dangerous when performed for advanced appendicitis when a large inflammatory mass or abscess cavity is present. In addition,

appendectomy as a primary approach in these complicated cases may limit the use of laparoscopic techniques, result in a larger open laparotomy incision, and lead to increased infectious morbidity.

While signs and symptoms such as peri-umbilical pain relocating to McBurney's point, point tenderness with peritoneal signs, and anorexia help make the diagnosis of acute appendicitis, children often cannot relate these symptoms accurately and their physical examination can be challenging and even misleading [17,18]. These difficulties can lead to appendicitis being misdiagnosed or simply overlooked and these children often present at a more advanced stage of disease with perforation. If the disease continues to progress a phlegmon or well-defined abscess can result. The optimal treatment of appendicitis at this advanced stage is not well established. Older reports can be found in the literature that advocated nonoperative therapy in children with delayed appendectomy [19, 20]. However, these studies suffered from a relatively high number of patients who failed nonoperative management, eventually requiring primary appendectomy. Comparing these studies, hospital stay and duration of antibiotic therapy are longer in these methods compare to our cases and according to the literature as children cannot localize infected process by omental and visceral wall off as good as adults, so non operative managements may lead to peritonitis in a greater portion.

More recently, some authors have advanced immediate appendectomy in cases of complicated appendicitis [21], although this approach can certainly be technically challenging in the presence of a large periappendiceal inflammatory mass or abscess cavity. Others have advocated delayed appendectomy in select populations [22, 23].

Among 60 children with acute complicated appendicitis male to female ratio was 4:1. Mean age was  $7.18 \pm 2.17$  years and minimum age was 3 years and maximum age was 13 years. The initial diagnosis according to clinical finding in physical examinations and paraclinical findings was appendicular abscess that was observed in 53.3%. In Roach study among 360 who had evidence of perforation, 92 had an intra-abdominal abscess or right lower quadrant phlegmon [10]

The most common final diagnosis was appendicular abscess that was observed in 56.7% of patients. The most common antibiotic combination before surgery which was Pre scribed

in our patients was Keflin+Amikasin + Metronidazole.

In Pearl study, the most common pre- and postoperative antibiotics in those with perforated appendicitis were ampicillin/gentamicin/clindamycin or Flagyl (41%), cefoxitim (34%), or Unasyn (15%).

Finally in our study, safe appendectomy was performed in all 60 cases and post operative complications included two cases with wound infection and 4 cases with Chronic abdominal pain that were managed conservatively.

Only one patient was re admitted and underwent re-laparotomy because of bowel obstruction. In one case there was a localized gangrene of small bowel that was walled off the gangrened appendicitis so segmental resection and end to end anastomosis was performed besides of appendectomy. Using the silk string for omentectomy was not accompanied by any complication although they were used in infected area.

In the Roach study [10] Children who underwent delayed appendectomy had a welldefined abscess or phlegmon on preoperative imaging 97% of the time (31/32), but only 52% (31/60) of children undergoing primary appendectomy had these findings. There were no readmissions for complications in the primary drainage followed by interval appendectomy group, while the group treated with initial appendectomy and abscess drainage had 6 (10%) readmissions for postoperative complications (5/6 for recurrent intra-abdominal abscess). comparing to these reports, readmissions in our article were significantly less than Roach reports for initial appendectomy. But long term complications due to adhesions need further studies. So as primary conservative treatment and delayed appendectomy needs at least two periods of hospital admission, longer anti biotic therapy and sometimes treatment failure that will lead to operative intervention, and as primary aggressive approach to complicated appendicitis which was accompanied with acceptable results and complications, we suggest primary operative approach and a safe appendectomy in complicated appendicitis in children.

## Conclusions

According to our findings the current non operative approach to complicated appendicitis in children needs a revision.

## References

- McClusky DA, Skandalakis JE. Skandalakis' Surgical Anatomy. New York: Mc Graw Hill; 2004.
- Morrow SE, Newman KD. Appendicitis In: Ashcraft K, Holcomb G, Murphy P. Pediatric surgery. 4th ed. Philadelphia: Elsevier Saunders; 2005.P.577-87.
- Oldham K, Colombani P, Foglia R, Skinner M. Principles and practice of pediatric surgery. Philadelphia: Lippincott Williams and Wilkins; 2005.
- Partrick D. Prospective evaluation of a primary laparoscopic approach for children presenting with simple or complicated appendicitis. American Journal of Surgery 2006; 192(10): 750-5.
- Becker T, Kharbanda A, Bachur R. Atypical clinical features of pediatric appendicitis. Academic Emergency Medicine Journal 2007; 14(2): 124-9.
- Hardin D. Acute appendicitis: review and update. American Family Physician 1999; 60(13): 2027-34.
- Brown CV, Abrishami M, Muller M, Velmahos GC. Appendiceal abscess: immediate operation or percutaneous drainage?. The American surgeon 2003; 69(10): 829-32.
- Henry M C, Gollin G, Islam S, Sylvester K, Walker A, Silverman BL, et al. Matched analysis of nonoperative management vs immediate appendectomy for perforated appendicitis. Journal of pediatric surgery 2007; 42(1): 19-24.
- Vane D, Fernandez N. Role of interval appendectomy in the Management of complicated appendicitis in children. World Journal of Surgery 2006; 30(1): 51-4.
- Roach JP, Partrick DA, Bruny JL, Allshouse MJ, Karrer FM, Ziegler MM. Complicated appendicitis in children: a clear role for drainage and delayed appendectomy. American Journal of Surgery 2007; 194(6): 769-72.
- Fitz RH. Perforating inflammation of the vermiform appendix: with special reference to its early diagnoses and treatment. American Journal of the Medical Sciences 1886; 92(5): 321-46.
- Karp MP, Caldarola VA, Cooney DR, Allen JE, Jewett TC. The avoidable excesses in the management of perforated appendicitis in children. Journal of pediatric surgery 1986; 21(6): 506-510.
- Neilson IR, Laberge JM, Nguyen LT, Moir C, Doody D, Sonnino RE, et al. Appendicitis in children: current therapeutic recommendations. Journal of pediatric surgery 1990; 25(11): 1113-6.
- Schwartz MZ, Tapper D, Solenberger R. Management of perforated appendicitis in children. Ann Surg 1983; 197(5):407-11.
- Putnam TC, Caldarola VA, Cooney DR. Appendicitis in children. SURGERY, GYNECOLOGY AND OBSTETRICS 1990; 170(8): 527-32.
- Stevenson R. Appendicitis. In: Ziegler M, Azizkhan R, Weber T, editors. Operative Pediatric Surgery. New York: McGraw-Hill; 2003:671-89.
- Morrow S, Newman K. Current management of appendicitis. Seminars in Pediatric Surgery 2007; 16(1): 34-4.
- Becker T, Kharbanda A, Bachur R. Atypical clinical features of pediatric appendicitis. Academy of Emergency Medicine 2007; 14(2): 124-9.
- Shipsey M, O'Donnell B. Conservative management of appendix mass in children. Annals of The Royal College of Surgeons of England 1985; 67(1): 23-4.
- Gierup J, Karpe B. Aspects on appendiceal abscess in children with special reference to delayed appendectomy. Acta chirurgica scandinavica 1975; 141(10): 801-3.
- Goh BK, Chui CH, Yap TL, Low Y, Lama TK, Alkouder G, et al. Is early laparoscopic appendectomy feasible in children with acute appendicitis presenting with an appendiceal mass? A prospective study. Journal of pediatric surgery 2005; 40(7): 1134-7.
- Weber TR, Keller MA, Bower RJ, Spinner G, Vierling K. Is delayed operative treatment worth the trouble with perforated appendicitis in children?. The American journal of surgery 2003; 186(6): 685-9.
- Gibeily GJ, Ross MN, Manning DB, Wherry DC, Kao TC. Late-presenting appendicitis. Surgical Endoscopy and Other Interventional Techniques 2003; 17(5): 725-9.