









Case Report

Hyalinizing clear cell carcinoma of parotid, intricacies of management: a rare case report

Rohit Bhardwaj¹ , Vikas Chauhan² , Rajni Prasad³ , Ankit Parasher⁴ , Ashwin N Tripathi⁴ ,
Prasann Rasania⁵ 

¹ Assistant Professor, Department of Otorhinolaryngology, Army College of Medical Sciences, Near Base Hospital, Delhi Cantt, India

² Chief Medical Officer, Department of Otorhinolaryngology, VMMC and Safdarjung Hospital, New Delhi, India

³ Director Professor, Department of Pathology, VMMC and Safdarjung Hospital, New Delhi, India

⁴ Senior Resident, Department of Otorhinolaryngology, VMMC and Safdarjung Hospital, New Delhi, India

⁵ Junior Resident, Department of Otorhinolaryngology, VMMC and Safdarjung Hospital, New Delhi, India

Corresponding Author:

Tel: +919871759227

Email: drrohitbhardwaj90@gmail.com

Abstract

Hyalinizing clear cell carcinoma (HCCC) usually affects minor salivary glands. It rarely occurs in major salivary glands. HCCC is difficult to diagnose in Fine Needle Aspiration cytology (FNAC). The possibility of metastasis from other primary sites should be rejected during the management of these tumors. An elderly man presented with insidious onset, and gradual progressive painless swelling arising from the deep lobe of the parotid gland. FNAC, which was performed twice with Ultrasound Guidance (USG), could not provide much detail about the type of tumor. Total conservative parotidectomy was conducted. These rare tumors cause significant challenges to physicians. The high index of suspicion and combined efforts of the multidisciplinary team are pivotal in management.

Keywords: Clear Cell Adenocarcinoma, Cytodiagnosis, Fine-Needle Biopsy, Parotid Neoplasms, Salivary Glands

Citation: Bhardwaj R, Chauhan V, Prasad R, Parasher A, Tripathi AN, Rasania P. Hyalinizing clear cell carcinoma of parotid, intricacies of management: a rare case report. J Surg Trauma. 2021; 9(4):171-175.

Received: August 16, 2021

Revised: August 26, 2021

Accepted: November 10, 2021

Introduction

HCCC was first described as a rare neoplasm of minor salivary glands in 1994 (1). After almost a decade later, this entity was introduced in the World Health Organization's Histological Classification of Salivary Gland Tumors (2). The rarity of the tumor can be understood by the fact that minor salivary gland tumors contribute up to 23% of all salivary gland neoplasms and HCCC accounts for less than 0.5% (3). It rarely occurs in major salivary glands. While this tumor affects sites of usual predilection such as minor salivary glands, this type of tumor affects the elderly age group (after forty) with a slight female predominance. Age and gender preference cannot be reliably commented upon due to the extreme scarcity of research literature dealing with its occurrence in major salivary glands. The tumor histopathologically shows clear cells forming nests and cords in a

hyalinized stroma. A similar histological structure can also be seen in many other salivary gland tumors such as clear cell oncocytoma, epithelial-myoepithelial carcinoma, mucoepidermoid carcinoma, clear cell myoepithelial carcinoma, acinic cell carcinoma, and myoepithelial carcinoma, which makes it a tedious diagnosis of exclusion (4). Metastatic renal cell carcinoma and balloon cell melanoma should also be excluded before confirming as a diagnosis in major salivary glands, as these also share somewhat similar histological findings (5).

In this report, we describe a case of parotid HCCC due to its rarity to sensitize the reader to potential challenges encountered in managing the case (such as diagnostic inaccuracies of "FNAC"). HCCC requires rejection of hidden primary malignancy, post-operative need for radiotherapy, and long-term follow-up to diagnose recurrence.

Case Report

A 44-year-old man was referred to our Outpatient Department (OPD) with insidious onset, and gradual progressive painless swelling below the right ear for the past one year (Figure 1: Preoperative [A] clinical photograph of the patient).

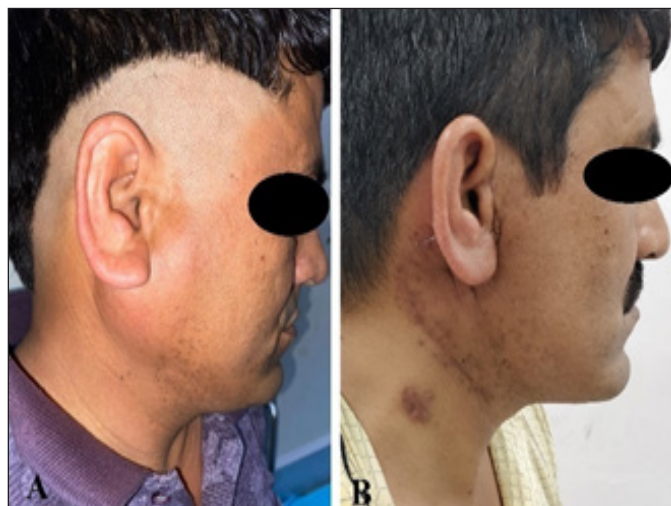

Figure 1: Preoperative (A) and Postoperative (B) clinical photograph of the patient.

The swelling was only aesthetically problematic and did not cause other symptoms such as fever, pain or restrictions in jaw movements, dryness of mouth, increased swelling after meals, weakness of facial muscle, or ear problems. He had no history

of trauma or surgery at the site. On examination, a firm, globular, non-tender swelling was palpated in the right parotid region. The swelling did not adhere to the underlying structures and the overlying skin. Intra-oral examination revealed the right tonsil with minimal medial displacement. Facial nerve function tests suggested no abnormality. Magnetic Resonance Imaging (MRI) showed a well-defined space-occupying lesion with altered signal intensity (iso-intense on T1w and hyperintense on Short-TI Inversion Recovery [STIR] images) in the right parotid gland which mainly involves the deep lobe (Figure 2: Preoperative MRI imaging of the lesion in axial incisions showing a hyperintense lesion). The lesion was extended to the right retro-mandibular region with effacement of retro-mandibular veins. However, no significant lymphadenopathy was observed in the neck and the contralateral parotid appeared normal.

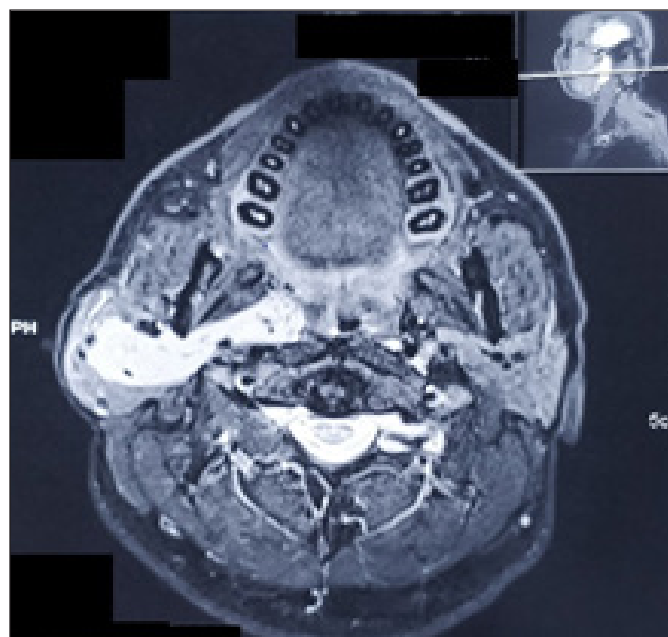


Figure 2: Preoperative MRI imaging of the lesion in axial incisions showing a hyperintense lesion.

Ultrasonography guided FNCA was then performed from the lesion, smears of which showed clusters of polygonal to spindle cells that present mild to moderate pleomorphism at sites arranged in nests, acinar and papillary pattern (Figure 3: FNAC image shows clusters of polygonal to spindle cells that present mild to moderate pleomorphism at sites arranged in nests, acinar and papillary pattern).

Similar results were obtained and the possibility of malignant salivary neoplasm was suggested by repeating the test. The patient was informed of the diagnosis and was recommended surgical treatment. Informed consent was obtained from the patient for conservative surgery to preserve the facial nerve since there was no clinical and radiological involvement of the facial nerve along with uncertainty about the histological subtype of tumor.

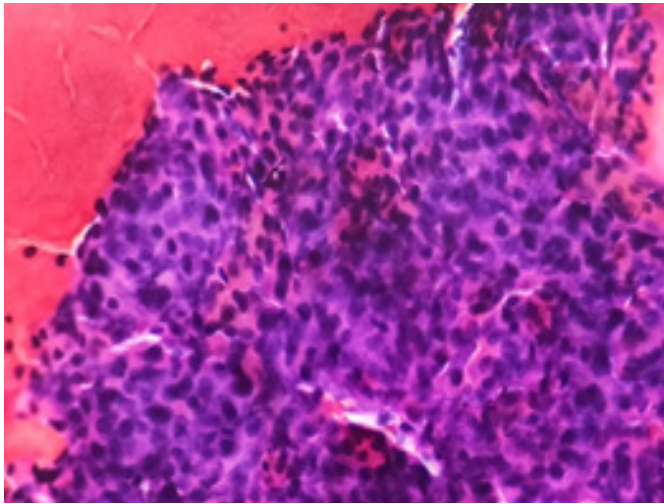


Figure 3: FNAC image shows clusters of polygonal to spindle cells that present mild to moderate pleomorphism at sites arranged in nests, acinar and papillary patterns.

Total conservative parotidectomy was performed to incise the lesion. Histopathological examination

(HPE) of the postoperative sample showed cords, trabeculae, sheets, nets of monomorphic clear epithelial cells, as well as cells with eosinophilic granular cytoplasm, foci of lymphocytic infiltrate and fibrous to hyalinized stroma at sites (Figure 4: HPE image showing cords, trabeculae, sheets, nests of monomorphic clear epithelial cells as well as the cell with eosinophilic granular cytoplasm with foci of lymphocytic infiltrate and fibrous to hyalinized stroma at places [A], Periodic Acid Schiff [PAS] staining [B] Immunohistochemical [IHC] images which present positivity of Cytokeratin [C] and Vimentin [D]). Cellular atypia was mild and mitotic figures were rare. No evidence of perineural or vascular invasion or necrosis was observed.

Immunohistochemical studies of the sample showed CK, Epithelial Membrane Antigen (EMA), Vimentin, and PAS positivity. Focal positivity was also reported for P63. Samples were negative for Carcinoembryonic Antigen (CEA), S-100, Glial fibrillary acidic protein (GFAP), Smooth Muscle Actin (SMA), CD10, and P16. The possibility of hyalinizing clear cell carcinoma of the deep lobe of parotid was suggested based on HPE and IHC findings. The patient was imaged using a contrast-enhanced computed tomography scan of the abdomen and pelvis to rule out the possibility of renal

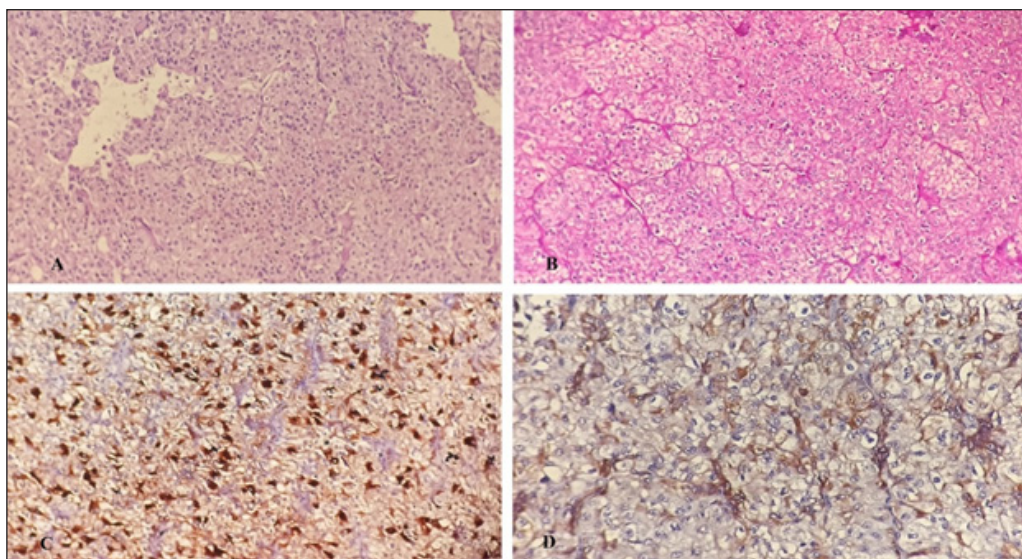


Figure 4: HPE image shows cords, trabeculae, sheets and nests of monomorphic clear epithelial cells, as well as cell with eosinophilic granular cytoplasm with foci of lymphocytic infiltrate and fibrous to hyalinized stroma at sites (A), PAS staining (B) IHC images which present positivity of CK (C) and Vimentin (D).

carcinoma metastasizing to the parotid. The patient underwent an MRI scan, 2 months postoperatively to check for the recurrent or residual lesion. Imaging reports were reassuring. Based on these findings, the multidisciplinary team meeting decided to keep the patient under close follow-up without radiotherapy (Figure 1: Post-operative [B] clinical photograph of the patient). The patient has been followed up for the past 14 months and the disease has not recurred.

Discussion

HCCC is a slowly progressive painless tumor of minor salivary glands which becomes symptomatic only after attaining a defined size in a particular site. This lesion usually affects the elderly with slight female preponderance (6). It rarely occurs in major salivary glands. This tumor indicates local aggressive behavior with the potential for local and distant metastases along with the possibility of recurrence (although not very common). Therefore, it has been mentioned as a low-grade malignancy of salivary glands (2-7). Trabeculae and islands of clear cells in a hyalinized stroma are characteristic appearances of HCCC. Smaller cells with eosinophilic cytoplasm and areas of squamous metaplasia can also be occasionally seen (8). Even though FNAC can accurately diagnose parotid lesions with a diagnostic accuracy of 94% (9), it is not applicable for HCCC as its cytomorphological features overlap with other parotid lesions, making it a tedious and indeterminate process. Acinic cell carcinoma, clear cell oncocytoma, epimyoepithelial carcinoma, sebaceous lymphadenoma, metastatic clear cell carcinoma of the kidney can all appear with somewhat similar cytomorphological findings. In this case, the tumor also caused a diagnostic challenge and despite conducting USG guided FNAC twice, we could not confirm the type of the tumor. This error is acceptable since the tumor tissue obtained by FNAC might not always have typical features. HPE of tumor tissue is also incapable of giving a definitive diagnosis by rejecting the aforementioned possibilities, therefore IHC studies are very important for this purpose. Expression of Cytokeratins, CEA, and EMA as IHC markers is common in "CCC"

(clear cell carcinoma) of salivary gland origin with simultaneous lack of expression of myoepithelial markers like S-100, glial fibrillary acid protein and Actin is necessary for diagnostic confirmation (10). As clear cell carcinoma in parotid can metastasize from kidneys, the immunoreactivity with CD10 (a membrane-associated marker, present in renal CCC and not in primary parotid CCC) is equally useful in ruling out this possibility (11). Expression of P63 is also more common in HCCC but it is never expressed by renal cell carcinoma (12-13). In this patient, IHC was positive for CK, EMA, Vimentin, and PAS, focal positivity for P63, and negative for CEA, S-100, GFAP, SMA, CD-10, and P16. The possibility of metastatic carcinomas should also be radiologically rejected (we also rejected in this case).

Although considered as a low-grade malignant neoplasm, it microscopically shows local infiltration. Perineural and vascular invasion is also commonly observed (1). The tumor also tends to recur along with the occasional possibility of lymph node and distant metastasis (1-14). Treatment with complete surgical excision is sufficient in most cases of HCCC, however, neck dissection and radiotherapy have also been used in managing this tumor (1-7). Histologic tumor grade, perineural and vascular invasion, positive surgical margins, and the presence of lymph node metastasis are the major determinants of neck dissection or postoperative radiotherapy (15). In our case, the patient had no lymph node metastasis as suggested by preoperative imaging. HPE assessment of the resected samples also showed no perineural or vascular invasion or positive resection margins which eliminates the need for neck dissection or radiotherapy.

Conclusion

HCCC of the parotid gland is a rare and distinct clinical entity that imposes many challenges to physicians as well as pathologists. Although FNAC has good diagnostic accuracy for parotid lesions, the clear diagnosis of this tumor is not always possible by needle aspiration cytology. Also, confirming the diagnosis of HPE is a complicated task and demands an evaluation by IHC studies. Elimination

of the possibility of other metastatic primary malignancies cannot be underestimated in management and requires the contribution of IHC and imaging studies. A high index of suspicion in diagnosis, meticulous surgery, and thorough follow-up is needed in the satisfactory management of these tumors.

Acknowledgment

The authors would like to express their sincere appreciation to Krishna Sarraf for her valuable technical support.

Conflict of interest

The authors declare that there is no conflict of interest regarding the publication of the present study.

References

- Weinreb I. Hyalinizing clear cell carcinoma of salivary gland: a review and update. *Head Neck Pathol.* 2013;7(Suppl 1(Suppl 1):20-29. doi:10.1007/s12105-013-0466-8
- Yang S, Zhang J, Chen X, Wang L, Xie F. Clear cell carcinoma, not otherwise specified, of salivary glands: a clinicopathologic study of 4 cases and review of the literature. *Oral Surg Oral Med Oral Pathol Oral Radiol Endod.* 2008;106(5):712-720.
- Agrawal J, Kumar Y, Damera D, Kumar S. Clear cell carcinoma of minor salivary gland: A case of clinical dilemma. *Contemp Clin Dent.* 2014;5(3):389-392.
- Rinaldo A, McLaren K, Boccato P, Maran A. Hyalinizing Clear Cell Carcinoma of the Oral Cavity and of the Parotid Gland. *ORL.* 1999;61(1):48-51.
- Solar A, Schmidt B, Jordan R. Hyalinizing clear cell carcinoma. *Cancer.* 2008;115(1):75-83.
- Rodriguez M, Reija M, Rodilla I. Primary clear cell carcinoma of parotid gland: Case report and review of literature. *J Oral Maxillofac Pathol.* 2013;17(1):101-105.
- Ponniah I, Lavanya N, Suresh Kumar P. Island of salivary gland in adipose tissue: a report of three cases. *J Oral Pathol.* 2007;36(9):558-562.
- Berho M, Huvos A. Central hyalinizing clear cell carcinoma of the mandible and the maxilla a clinicopathologic study of two cases with an analysis of the literature. *Human Pathology.* 1999;30(1):101-105.
- Ali N, Akhtar S, Junaid M, Awan S, Aftab K. Diagnostic Accuracy of Fine Needle Aspiration Cytology in Parotid Lesions. *ISRN Surgery.* 2011:1-5. doi:10.5402/2011/721525
- Seijas B, Franco F, Sastre R, García A, López-Cedrún C, Cembranos J. Metastatic renal cell carcinoma presenting as a parotid tumor. *Oral Surg Oral Med Oral Pathol Oral Radiol.* 2005;99(5):554-557.
- Yang B, Ali S, Rosenthal D. CD10 facilitates the diagnosis of metastatic renal cell carcinoma from primary adrenal cortical neoplasm in adrenal fine-needle aspiration. *Diagn Pathol.* 2002;27(3):149-152.
- Antonescu C, Katabi N, Zhang L, Sung Y, Seethala R, Jordan R et al. EWSR1-ATF1 fusion is a novel and consistent finding in hyalinizing clear-cell carcinoma of salivary gland. *Genes Chromosomes Cancer.* 2011;50(7):559-570.
- McHugh J, Hoschar A, Dvorakova M, Parwani A, Barnes E, Seethala R. p63 Immunohistochemistry Differentiates Salivary Gland Oncocytoma and Oncocytic Carcinoma from Metastatic Renal Cell Carcinoma. *Head Neck Pathol.* 2007;1(2):123-131.
- Wang B, Brandwein M, Gordon R, Robinson R, Urken M, Zarbo R. Primary Salivary Clear Cell Tumors—A Diagnostic Approach. *Arch Pathol Lab Med.* 2002;126(6):676-685.
- Vander Poorten V, Balm A, Hilgers F, Tan I, Keus R, Hart A. Stage as major long term outcome predictor in minor salivary gland carcinoma. *Cancer.* 2000;89(6):1195-1204.