



Case Report

Management of a case of dirty traumatic scalp lacerations and multiple skull fractures and exposure to Dura matter

Mohammad Reza Fathi¹  

¹ Assistant Professor of Neurology, Clinical Research Development Unit of Emam Reza Hospital, Birjand University of Medical Sciences, Birjand, Iran

Corresponding Author:

Tel: +989128453562

Email: mrezaafathi@gamil.com

Abstract

In traumatic brain injury many objects may enter the cranium, if these injuries are associated with the entry of contaminated foreign bodies into the brain; they can cause more damage and complications. This is a case report of such patients with different aspects of treatment.

We reported a case followed motor accident suffered dirty large scalp lacerations, multiple linear and depressed skull fractures, and exposure to dura matter, pneumocephalus, and many sands and soil under the cranium. Several therapeutic actions were done including adequate irrigation, administration of Prophylactic antimicrobial and anticonvulsant therapy, and early surgical intervention. The Patient did not show any signs or symptoms of infections or other complications during the hospitalization period and he had a favorable 10-month follow-up period. We concluded in penetrating brain injury with contaminated foreign bodies, adequate irrigation and early administration of prophylactic antibiotic therapy and antiepileptic agents associated with early neurosurgical intervention can be helpful in complications prevention.

Keywords: Traumatic Brain Injury, Head Injuries, Penetrating, Skull Fractures, Antibiotic Prophylaxis, Anticonvulsant

Citation: Fathi M.R. Management of a case of dirty traumatic scalp lacerations and multiple skull fractures and exposure to Dura matter. *J Surg Trauma.* 2022;10(4):160-166.

Received: October 28, 2021

Revised: November 27, 2021

Accepted: November 29, 2021

Introduction

In traumatic brain injury (TBI), too much energy is released into the brain suddenly. This can cause sudden damages to the brain. If these injuries are associated with the entry of contaminated foreign bodies into the brain, they can cause more damage (1). Acute traumatic brain injury is seen in every adult or children, and penetrating cranial injuries are a small proportion of these (1). Many kinds of foreign objects may enter the cranium cavity, leading to intraparenchymal penetrating injuries. The most frequently encountered cranial injuries in adults are due to armed weapons (2). When children are concerned, household items such as forks, buckles, hairclips, pencils, and pens may become injurious materials (1). Intracranial penetrating injuries and dirty wounds may lead to severe complications such as cerebral hemorrhages, neurological deficits, and various cerebral infections that may be life-threatening. In the present study, we report a case of a head injury after a motor vehicle collision that caused very dirty

traumatic scalp lacerations and multiple skull fractures, and exposure to Dura matter. Our purpose in this case report is to point out that a very large and dirty scalp lacerations and ruptured and damaged Dura and brain didn't show always infection or other complications.

Case

A 9 years old boy was admitted to the emergency ward in Birjand Imam Reza hospital, Iran, following a motor vehicle collision. The accident mechanism was car roll over and the patient fell out of the car on the wet and dusty ground. In this accident mother of the patient suffered vertebral column fracture dislocation and complete spinal cord injury.

His evaluated initial Glasgow Coma Scale (GCS) was 8 out of 15.

There were extensive scalp lacerations and lameness. In his neurological examinations, we detected a right-side hemiparesis. Also, he had unilateral left mydriasis and Marcus gun reflex. The patient became intubated at the entry into

the emergency ward and 2 intravenous lines were fixed. Because of the very dirty appearance of lacerations a prophylactic fourth generation of cephalosporin (intravenous cefepime) was administered.

Initial irrigation with 2-liter normal saline serum was done and a lot of foreign bodies consisting of sand pieces and soil was removed there were seen multiple linear and depressed skull fractures. In the left parietal region, there was a defect of skull bone and Dura matter was exposed. Prophylactic anticonvulsant agent (intravenous phenytoin) was administered.

Brain and cervical Computed Tomography (CT) scans were done (Fig.1) that revealed: a temporoparietal depressed fracture, multiple linear fractures, a large hyper-dense object under the skull in the left parietal region (bone density: +845 Hounsfield (HU), foreign body density: +1,825 HU), fractures of left sphenoid ridge and superior orbital fissure area, the left blow out fracture, multiple facial fractures. Pneumocephalus and scattered contusion areas.

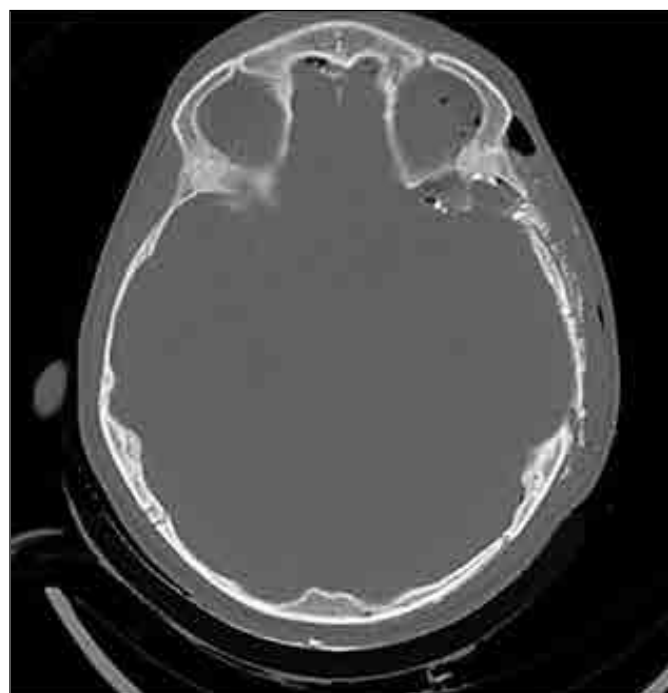
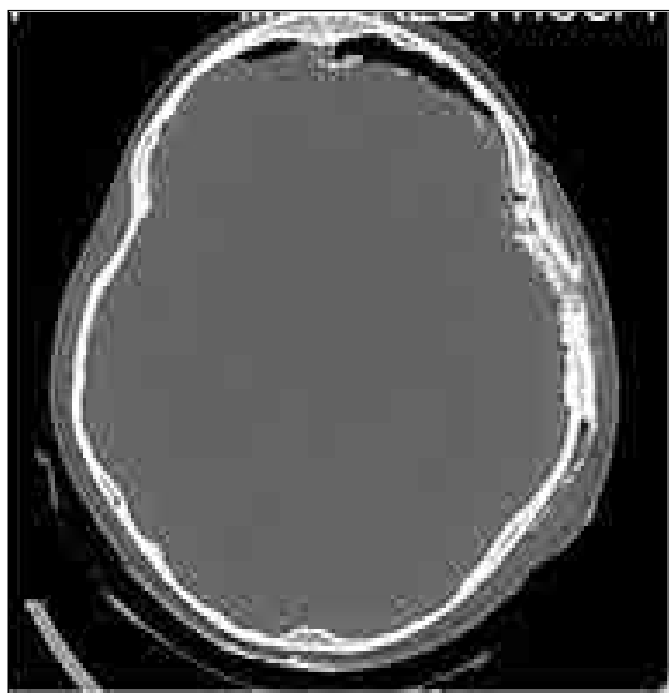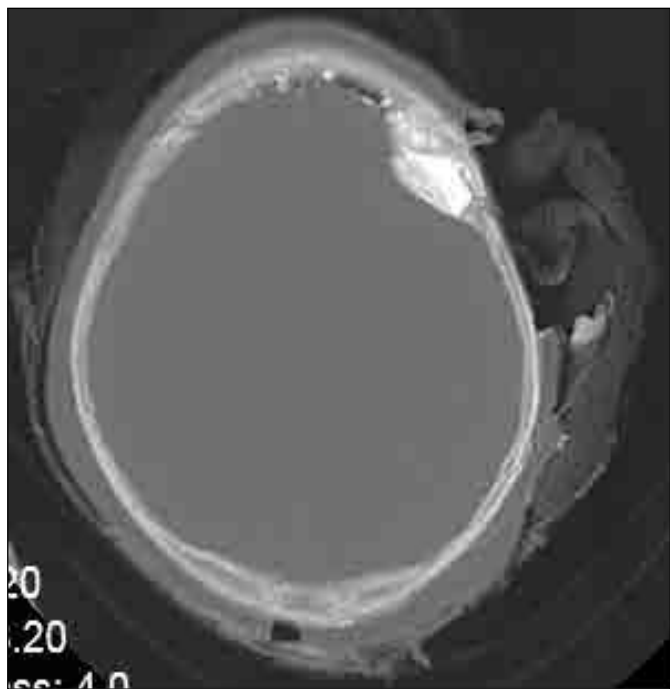


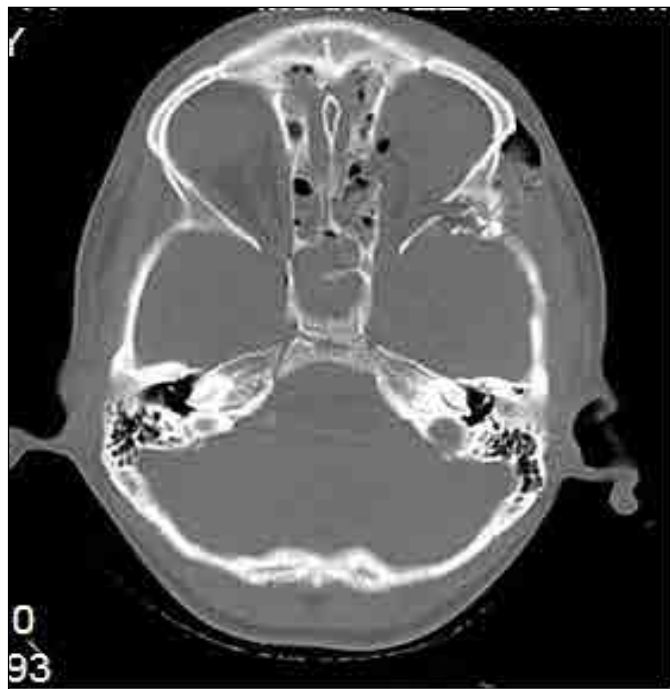Fig 1. Preoperative skull CT scans.

A: Multiple skull fractures, several intracranial and intraparenchymal foreign bodies and pneumocephalus

B: Multiple skull fractures, several intracranial and intraparenchymal foreign bodies and pneumocephalus.

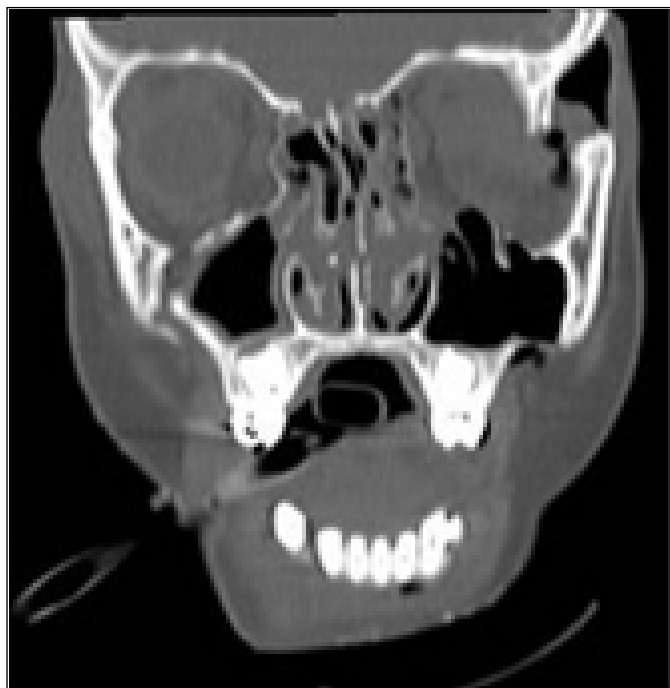

C: A depressed skull fracture and a large stone among bone fragments and another one under the scalp.



D: Left posterior orbital wall fracture and superior orbital fissure region fractures.

The patient was transferred immediately to the operating room. After general anesthesia and positioning, the scalp was irrigated with 2 liters of normal saline serum, and a lot of sands and fine sands which had hardly stuck the galea and pericranium were removed. Prep and drep were done and the scalp was irrigated again with 1-liter normal saline serum (Fig.2).



E: Fracture of the left lateral orbital wall and the left blow out Fracture.

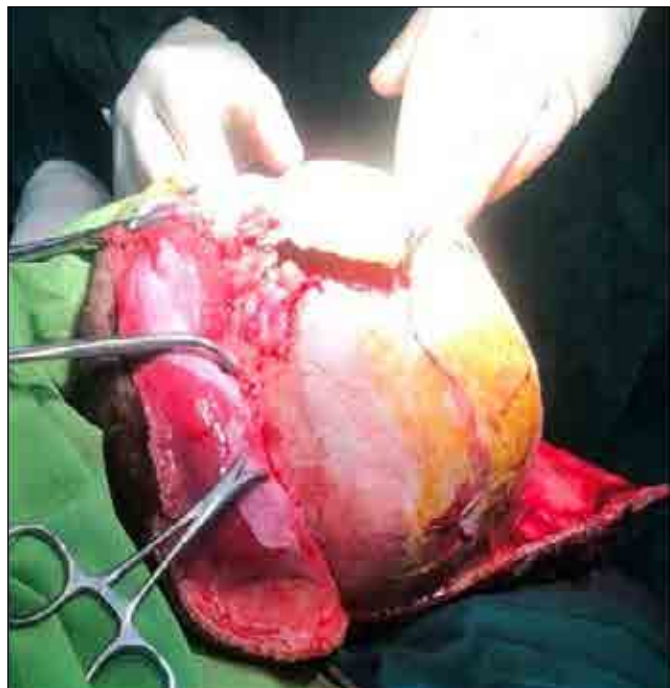


Fig 2. A photograph captured during the operation, show wide scalp lacerations and multiple skull fractures.

Then left front oparietotemporal craniectomy was performed. The traumatic scalp lacerations and lameness were so large and extensive that allowed surgery without incising the scalp. Dura matter was ruptured and a lot of bone fragments and fine sand pieces were seen under the Dura and within the brain. Also a large stone piece with approximately 3 cm diameter among bone pieces was found and exited from the left parietal area. The Dura matter had been separated from the skull even in the superior sagittal sinus region. Fortunately, this Venous sinus was intact. Grains sands had gone to the other side over the Dura. The contralateral side was not adequately available so we decided to do a smaller craniotomy on the right side and then removed a lot of foreign bodies. Finally, the Dura was restored and scalp lacerations were sutured. We used monofilament suture threads in all restorations. The bone flaps were washed and placed under the abdominal skin.

The Patient was transferred in the intubated state to the intensive care unit. Administration of antibiotics continued. He became conscious 2 days after surgery and became extubated. The patient did not become febrile and the antibiotic was discontinued on the third day. He was aphasic and there was left unilateral eye ptosis and mydriasis. Ophthalmologic consultation was done after the patient awakened was revealed left retina injury and blindness. The patient left eye had complete ophthalmoplegia. So was performed another operation and was approached the Superior Orbital Fissure (SOF) area and the fractured bone fragments removed and was explored and decompressed by the ophthalmic nerves. Then the zygomatic process attached the orbital wall with a small titanium plate. The Antiepileptic drug continued for one week.

Hemiparesis was recovered and the patient was discharged on his foot. During the hospitalization period, he did not show any signs or symptoms of meningitis or any infectious complications. His aphasia recovered one month later. Three months later the patient's ptosis improved slightly. Cranioplasty was done 3 months after the first

surgery and blow-out fracture was also operated. The patient was discharged after cranioplasty without any complication except left eye blindness due to direct trauma. Hemiparesis and aphasia recovered completely and he had a favorable 10-month follow-up period.

Discussion

We want to talk about if a contaminated injury and wound are managed properly, it will not always lead to cause an infection. Many traumatic intracranial foreign objects have been reported in the literature. Ozkan U et al., commented penetrating cranial traumas in adults usually occur due to weapons and shrapnel fragments (2). In children, these traumas may occur due to household objects such as kitchen utensils, toys, hair pins and pencils (1).

In the present study, a 9 years old boy following motor vehicle collision jumped out of the car in a dusty and rainy area and occurred extensive scalp lacerations from the frontal to the occipital region and multiple skull fractures. The patient's wound was completely contaminated with a lot of foreign objects on both sides of the scalp and cranium. For managing these situations, simple and complex therapies are needed. The most important complication in these cases is cerebral infections like meningitis, encephalitis, and cerebral abscesses that have early or late onset.

After resuscitation, the wounds were washed with normal saline serum. Imaging procedures are usually used to detect penetrating foreign bodies. In the cranial CT, we found many small and large foreign objects with a density higher than the normal bone density (3). CT assessment showed a piece of wood (-310 HU). Contaminated penetrating objects may have many complications. Rahman N.U et al., said intracranial foreign objects may cause brain hemorrhages and contusions at early stage and seizures and infections at later (4).

These complications may occur in every patient but usually, all of them don't occur in all patients. Our art is to prevent these complications through proper and rapid interventions. The issue of antibiotic resistance is a real problem and every

physician should consider it when deciding to prescribe an antibiotic. We found that authors use prophylactic antibiotics in cases of contaminated penetrating cranium wounds that here are mentioned some of them.

The risk of infection in cranial traumas in pediatric have been mentioned even over 40% but the risk in dirty wounds is not noted (5, 6). For surgical wounds, skin pathogens including *Staphylococcus* and gram negative bacillus are more common(7). If the situation is convenient, contaminated foreign objects must be extracted as soon as possible.

In our patient, the risk of polymicrobial infection including gram-negative and gram-positive, and anaerobic pathogens was high due to heavy high contamination with wet sand and soil. During surgery, we recognized that the mentioned large intraparenchymal foreign object was a large stone, which was compatible with the preoperative imaging. In addition, there were a lot of fine sands under the cranial cavity and Dura that were removed.

Hemant Singhal et al, commented on some criteria for the use of systemic preventive antibiotics as follows: a high risk of infection is associated with the procedure, should be administered close to the time of the incision, should have activity against the pathogens likely to be encountered and not administration beyond 24 hours (8).

They recommended administration of a cephalosporin in such situations (8). In traumatic brain injuries if the antibiotics supposed to administrated, they should be imitated as soon as possible (7).

In a systematic review study by Daniele Poole et al, they concluded that many authors have used a three-days course of intravenous Ceftriaxone for prevention of cerebral infections in skull fractures or pneumocephalus and satisfactory results was achieved(9, 10) .

In A study, Mendeleev et al., recommends the use of the combination of ampicillin and sulfonamide with adequate surgical debridement in the treatment of compound depressed skull fractures (11). A Cephalosporin with or without Gentamycin

for a period of 4 to 10 days was with satisfactory results (7).

In another study, the patients were randomly divided into case and control groups and was concluded that giving a 5 day course of prophylactic antibiotic of ceftriaxone had no effect on the prevention of meningitis (12).

In a study by Adomas Bunevicius et al was reported the cow horn caused skull and brain injury and cerebrospinal fluid (CSF) leakage, that improved with surgical treatment and administration of prophylactic antibiotic of Ceftriaxone. (13). Leach P.J et al, has concluded that if the patients receive prophylactic antibiotic including oral penicillin 500 mg four times a day (QID) and oral sulfonamide 500 mg QID, until one week after the cessation of CSF leakage, it will significantly prevent meningitis (14). In another study, Ignelzi R.J .et al said in both retrospective and prospective sections the administration of prophylactic antibiotics in traumatic cerebrospinal fluid leakage has no role in preventing cerebral infections and in some cases it is harmful (15) .

According to our abovementioned descriptions and wound appearance, the risk of infectious complications was in high probability. We administered a fourth-generation drug of cephalosporin in the emergency unit. After doing imaging and finding the foreign bodies in the cranium continued until 3 days.

Another important complication in penetrating brain injury is seizure attacks. The prevalence of posttraumatic epilepsy in children has been estimated at around 9 to 22 percent in various studies (16-24). Prophylactic administration of antiepileptic therapy in traumas from practical guideline is as follows: in adults with impaired consciousness, amnesia, brain penetrating injuries or pathology in CT scans such as depressed skull fractures or cerebral hemorrhages, phenytoin administration prevents seizures for up to one week (25-28).

The efficacy of other drugs has not been evaluated as well as phenytoin. There are two randomized controlled trials studies on the efficacy of

antiepileptic prophylactics in pediatric trauma (29, 30). The first study evaluate the effect of phenytoin on the prevention of late onset posttraumatic seizures (29) And The second, examined its effect on the prevention of early onset seizures within 48 hours (30). The Results of these two researches showed no significant differences between the drug and control groups (29,30) .

But still antiepileptic medication such as phenytoin is prescribed, in severe or penetrating pediatric traumas(30,31). In our patient, intravenous phenytoin was used until one week. Complementary operations for restoring left orbit were done and the patient experienced a favorable recovery.

Conclusion

In penetrating brain traumatic injury with contaminated foreign bodies, initial resuscitation and adequate irrigation and foreign objects clearance with emergent neurosurgical intervention and early administration of prophylactic antibiotic therapy and antiepileptic agents can be helpful in complications prevention.

Conflicts of interest

The author has no conflicts of interest to declare.

References:

1. Koestler J, Keshavarz R. Penetrating head injury in children: a case report and review of the literature. *J Emerg Med.*2001;21(2):145-150.
2. Özkan Ü, Kemaloğlu M, Özateş M, Aydın M. Analysis of 107 civilian craniocerebral gunshot wounds. *Neurosurg Rev.*2002;25(4):231-236.
3. Jooma R, Bradshaw JR, Coakham HB. Computed tomography in penetrating cranial injury by a wooden foreign body. *Surg Neurol.*1984;21(3):236-238.
4. Rahman N-U, Jamjoom A, Jamjoom ZAB, El-Asrar AA. Orbito-cranial injury caused by penetrating metallic foreign bodies: report of two cases. *International ophthalmology.*1997;21(1):13-17.
5. Domingo Z, Peter JC, de Villiers JC. Low-velocity penetrating craniocerebral injury in

- childhood. *Pediatr Neurosurg.*1994;21(1):45-49.
6. Kaufman HH, Schwab K, Salazar AM. A national survey of neurosurgical care for penetrating head injury. *Surg Neurol.*1991;36(5):370-377.
7. Bayston R, De Louvois J, Brown E, Johnston R, Lees P, Pople I. Use of antibiotics in penetrating craniocerebral injuries. *The Lancet.*2000;355(9217):1813-1817.
8. Singhal H, Kaur K, Zammit C. Wound infection. *3E*[accessed on 15 September 2009]. Available from: <http://emedicinecom/med/topic2422htm%>
9. Poole D, Chieragato A, Langer M, Viaggi B, Cingolani E, Malacarne P, et al. Systematic review of the literature and evidence-based recommendations for antibiotic prophylaxis in trauma: results from an Italian consensus of experts. *PloS one.*2014;9(11). <https://doi.org/10.1371/journal.pone.0113676>
10. Dagi TF, Meyer FB, Poletti CA. The incidence and prevention of meningitis after basilar skull fracture. *Am J Emerg Med.*1983;1(3):295-298.
11. Mendelow A, Campbell D, Tsementzis S, Cowie R, Harris P, Durie T, et al. Prophylactic antimicrobial management of compound depressed skull fracture. *J R Coll Surg Edinb.* 1983;28(2):80-83.
12. Eftekhari B, Ghodsi M, Nejat F, Ketabchi E, Esmaeeli B. Prophylactic administration of ceftriaxone for the prevention of meningitis after traumatic pneumocephalus: results of a clinical trial. *Journal of neurosurgery.* 2004;101(5):757-761.
13. Bunevicius A, Bareikis K, Kalasauskas L, Tamasauskas A. Penetrating anterior skull base fracture inflicted by a cow's horn. *J Neurosci Rural Pract.*2016;7(S 01):106-108.
14. Leech P, Paterson A. Conservative and operative management for cerebrospinal-fluid leakage after closed head injury. *The Lancet.*1973;301(7811):1013-1016.
15. Ignelzi RJ, VanderArk GD. Analysis of the treatment of basilar skull fractures with and without antibiotics. *Journal of neurosurgery.*1975;43(6):721-726.
16. Appleton R, Demellweek C. Post-traumatic

epilepsy in children requiring inpatient rehabilitation following head injury. *Journal of Neurology, Neurosurgery & Psychiatry*. 2002;72(5):669-672.

17. Hahn YS, Fuchs S, Flannery AM, Barthel MJ, McLone DG. Factors influencing posttraumatic seizures in children. *Neurosurgery*. 1988;22(5):864-867.

18. Lewis RJ, Yee L, Inkelis SH, Gilmore D. Clinical predictors of post-traumatic seizures in children with head trauma. *Ann Emerg Med*. 1993;22(7):1114-1118.

19. Yablon SA, Dostrow VG. Post-traumatic seizures and epilepsy. *Brain injury medicine: principles and practice*. 2007.

20. Agrawal A, Timothy J, Pandit L, Manju M. Post-traumatic epilepsy: an overview. *Clin Neurol Neurosurg*. 2006;108(5):433-439.

21. Bushnik T, Englander J, Wright J, Kolakowsky-Hayner SA. Traumatic Brain Injury With and Without Late Posttraumatic Seizures: What Are the Impacts in the Post-Acute Phase A NIDRR Traumatic Brain Injury Model Systems Study. *J Head Trauma Rehabil*. 2012;27(6):36-44.

22. Herman ST. Epilepsy after brain insult: targeting epileptogenesis. *Neurology*. 2002;59(5):21-26.

23. Annegers JF, Hauser WA, Coan SP, Rocca WA. A population-based study of seizures after traumatic brain injuries. *N Engl J Med*. 1998;338(1):20-24.

24. Rao VR, Parko KL, editors. Clinical approach to posttraumatic epilepsy. *Semin Neurol*. 2015;35:57-63.

25. Chang BS, Lowenstein DH. Practice parameter:

antiepileptic drug prophylaxis in severe traumatic brain injury: report of the Quality Standards Subcommittee of the American Academy of Neurology. *Neurology*. 2003;60(1):10-16.

26. Zafar SN, Khan AA, Ghauri AA, Shamim MS. Phenytoin versus levetiracetam for seizure prophylaxis after brain injury—a meta analysis. *BMC neurology*. 2012;12(1):1-8.

27. Cotton BA, Kao LS, Kozar R, Holcomb JB. Cost-utility analysis of levetiracetam and phenytoin for posttraumatic seizure prophylaxis. *J Trauma Acute Care Surg*. 2011;71(2):375-379.

28. Debenham S, Sabit B, Saluja RS, Lamoureux J, Bajsarowicz P, Maleki M, et al. A critical look at phenytoin use for early post-traumatic seizure prophylaxis. *Canadian journal of neurological sciences*. 2011;38(6):896-901. doi:10.1017/S031716710001249X

29. Young B, Rapp RP, Norton J, Haack D, Walsh JW. Failure of prophylactically administered phenytoin to prevent post-traumatic seizures in children. *Pediatr Neurosurg*. 1983;10(3):185-192.

30. Young KD, Okada PJ, Sokolove PE, Palchak MJ, Panacek EA, Baren JM, et al. A randomized, double-blinded, placebo-controlled trial of phenytoin for the prevention of early posttraumatic seizures in children with moderate to severe blunt head injury. *Ann Emerg Med*. 2004;43(4):435-46.

31. Teasell R, Bayona N, Lippert C, Villamere J, Hellings C. Post-traumatic seizure disorder following acquired brain injury. *Brain injury*. 2007;21(2):201-214.