



Case Report

Preservation of second molar tooth with extensive distal root resorption due to third molar tooth pressure: a case report

Maryam Dalaei Moghadam ¹  , Najmeh Ebadi ² 

¹ Assistant Professor of Endodontic, Razi Herbal Medicines Research Center, Department of Endodontic, Faculty of Dentistry, Khorramabad University of Medical Science, Khorramabad, Iran

² Post Graduate Endodontic Student, Department of Endodontic, School of Dentistry, Zahedan University of Medical Science, Zahedan, Iran

Corresponding Author:

Tel: +989120407133

Email: maryam.dalaei@yahoo.com

Abstract

This article presents a case of extensive External Root Resorption involving the distal root of the left mandibular second molar due to the pressure of wisdom tooth in its neighborhood in a 32 year-old female patient. Clinical and radiographic examination revealed no pulp in respond to the vitality test, periapical radiolucency in the apical of the mesial root, and root resorption of the distal root. A definite diagnosis of pulpal necrosis with chronic apical periodontitis and ERR of the distal root was made. The tooth was managed by nonsurgical endodontic treatment. One-year follow-up revealed satisfactory results clinically and radiographically.

Keywords: Tooth Resorption, Therapy, Complications, Cone Beam Computed Tomography

Citation: Dalaei Moghadam M, Ebadi N. Preservation of second molar tooth with extensive distal root resorption due to third molar tooth Pressure: a case report. J Surg Trauma.2023;11(1): 39-44.

Received: March 29, 2022

Revised: November 12, 2022

Accepted: November 26, 2022

Introduction

External Root Resorption (ERR) occurs when the cementoblastic layer or other tooth tissue on the root surface are either damaged or removed (1). Root Resorption (RR) can be classified into physiologic and pathologic resorption, the former of which generally refers to root resorption during the exfoliation of deciduous teeth (2). ERR has several reasons (3-7). One of the factors that are frequently associated with ERR of second molars is the presence of an impacted third molar in close proximity to the root of the second molar which could indicate that the pressure exerted by the impacted tooth participates in the resorption process. Although this mechanism of resorption is not yet entirely clear, some investigators consider it similar to the mechanism involved in the resorption of deciduous teeth (8).

RR is clinically asymptomatic, difficult to identify, and most difficult to treat. Since RR lacks symptoms, it tends to be diagnosed late (9).

ERR may seriously compromise the longevity of a tooth to such an extent that it may result in its early loss. It is, therefore, important that diagnosis and treatment occur at an early stage (1).

With using of cone beam computed tomography CBCT, the diagnosis of RR has improved significantly. This can be attributed to the sensitivity and accuracy of CBCT in its ability to detect RR.

This article describes a case of ERR of the distal root of the mandibular second molar with the mesial root intact.

Case

A 32-year-old female patient was referred to the Department of Endodontic for evaluation and treatment of the distal RR of the left mandibular second molar. The medical history was unremarkable. Extraction of his left lower third molar had been performed 1 month previously at the Department of Oral and Maxillofacial Surgery because of the discomfort of the tooth.

According to the surgeon's records, external RR on the distal root surface of tooth #18 was observed, caused by the impacted neighboring tooth at the time

of the surgical extraction. The periapical radiograph showed that there was extensive resorption of the distal root of tooth #18 (Figure 1. A), but the patient had no pain and discomfort associated with tooth #18 at the first visit to the Endodontic department. She felt only slight pain and dullness when chewing. CBCT images confirmed the extensive external RR in distal root of tooth#18 (Figure 1. B).

Clinical examination revealed that the mobility of tooth #18 was not within normal limits (> 1 mm labio-lingually), negative responses to cold tests with Endo Ice (Hygenic-Akron OH, USA), and Electric Pulp Test (EPT), and sensitivity to percussion. Given the results of our clinical and radiographic examination, the concluding diagnosis of the tooth was necrotic pulp and chronic apical periodontitis with external root resorption. The treatment options presented to the patient were Root Canal Treatment (RCT), and extraction (with/without replacement). In accordance with the patient's preferences, the possibility of saving the tooth via RCT was chosen. The patient signed informed consent.

After administration of local anesthesia (2% lidocaine with 1:80,000 adrenaline), access opening was done under rubber dam isolation. Three root canal orifices were located (mesiobuccal [MB], mesiolingual [ML], and distal [D]).

A #15 H-file (Dentsply/Maillefer, Ballaigues, Switzerland) was then introduced into the MB and ML canals, and the working length was determined by an apex locator (ROOT ZX; J. Morita, Tokyo, Japan) and confirmed radiographically (Figure 1. C). Distal canal were measuring only 3 mm. Cleaning and shaping was done for distal root with ISO 2% taper files up to size 35 (Dentsply/Maillefer, Ballaigues, Switzerland). The mesial root canals were prepared with 25/8% Reciproc file (VDW, Munich, Germany) along with Reciproc Silver electric motor. Also, 2.5% sodium hypochlorite (NaOCl) and 17% ethylenediaminetetraacetic acid (EDTA) (Aria Dent, Tehran, Iran) were used for root canal irrigation. The first 3 mm of the distal canal was irrigated with 0.5% NaOCL.

Then, the canals were dried with paper points, and a mixture of calcium hydroxide and saline was

delivered into the canals by a Lentulo spinal as medicament and temporarily restored with Cavit (Golchay, Tehran, Iran) between the treatment sessions. After 1 week, temporary restoration was removed and MB and ML canals were cleaned and dried. And were obturated by lateral compaction of guttapercha (Maillefer, Dentsply) and AH Plus resin sealer (Maillefer, Dentsply). The mineral trioxide aggregate (MTA) cement (Pro-Root MTA; Dentsply Tulsa Dental, Tulsa, OK) was mixed according to the manufacturer's instructions and placed into the distal orifice canal using an amalgam carrier and condensed vertically with hand pluggers (Maillefer, Dentsply). The tooth was then restored with an amalgam. After 1 year follow-up, clinical examinations showed that the tooth was functional with no signs of mobility or sensitivity to percussion, and had a normal periodontal condition (Figure 1. D).

Discussion

ERR on the second molar is one of the complications associated with an unerupted third molar (5, 10, 11). One study showed that horizontal and mesioangular impacted third molars may inflict damage to the roots of adjacent teeth (12). Nemcovsky et al. evaluated the apical position of impacted third molars and concluded that mesioinclinations of 60° or more relative to the D root of the second molar were significantly associated with RR (13).

A study showed that once ERR occurs, its severity increases with age because RR induced by mechanical pressure from impacted teeth may be progressive over time. From this viewpoint, early removal of the impacted third molar was highly suggested to prevent further damage to the second molar once ERR was detected (14). Conventional radiographic images are frequently used to detect (RR). However, these modalities have drawbacks such as superimposition of the adjacent structures, distortion, and magnification, which can compromise the correct detection of ERR (15, 16).

Studies have shown that CBCT scans were better for detecting (RR) than periapical radiographs (17-20). Oenning et al. concluded that the diagnostic

accuracy of CBCT was higher than panoramic radiography for detection of ERR, and its frequency in the mandible was higher than that in the maxilla (8).

In the present case, the prognosis of the severely resorbed tooth #18 was undesirable and extraction of the tooth was considered at first because about half of the distal root of tooth #18 was affected, as seen in the computed tomography scans (Fig 1. B). However, the asymptomatic subject, clinical findings, and patient demand led to a decision to the preservation of the tooth. When the diagnosis of ERR has been confirmed, especially from CBCT images, the oral surgeon should carefully evaluate the case and consider extraction of the third molar, followed by restoration, RCT of the second molar, or even resection of the affected root, if necessary there are some case report studies that evaluate or treat such cases (8).

Aravelli et al. treated an unusual case of localized idiopathic extensive external RR in involving the whole mesial root of the right mandibular first molar. The tooth was managed by nonsurgical endodontic treatment using MTA to seal resorbed canals which is similar to the present case that the coronal part of the distal canal filled using MTA (21).

However, teeth with severe resorption that do not involve the root canals and pulp are vital do not require endodontic treatment, and orthodontic treatment or tooth extraction in the neighborhood tooth is sufficient (7,22). Sometimes extraction of these teeth is inevitable due to severe RR and the impossibility of proper restoration (23).

In the present case, calcium hydroxide was used as an intracanal medicament for disinfection of the root canal system due to its antimicrobial property and inducing hard tissue formation (24). Also, MTA was the choice of material to obturate the D canal. One-year follow-up of the present case shows that the patient was asymptomatic, and there was no progression of resorption. In the treatment of such cases, all the therapeutic aspects should be weighed, and with timely therapeutic intervention and using all the appropriate therapeutic aspects, these teeth should be given a chance to survive. The limitation

of the present report is the lack of long-term valuation to come to a generalized conclusion. This

case series was prepared according to the PRICE 2020 Guidelines (25).

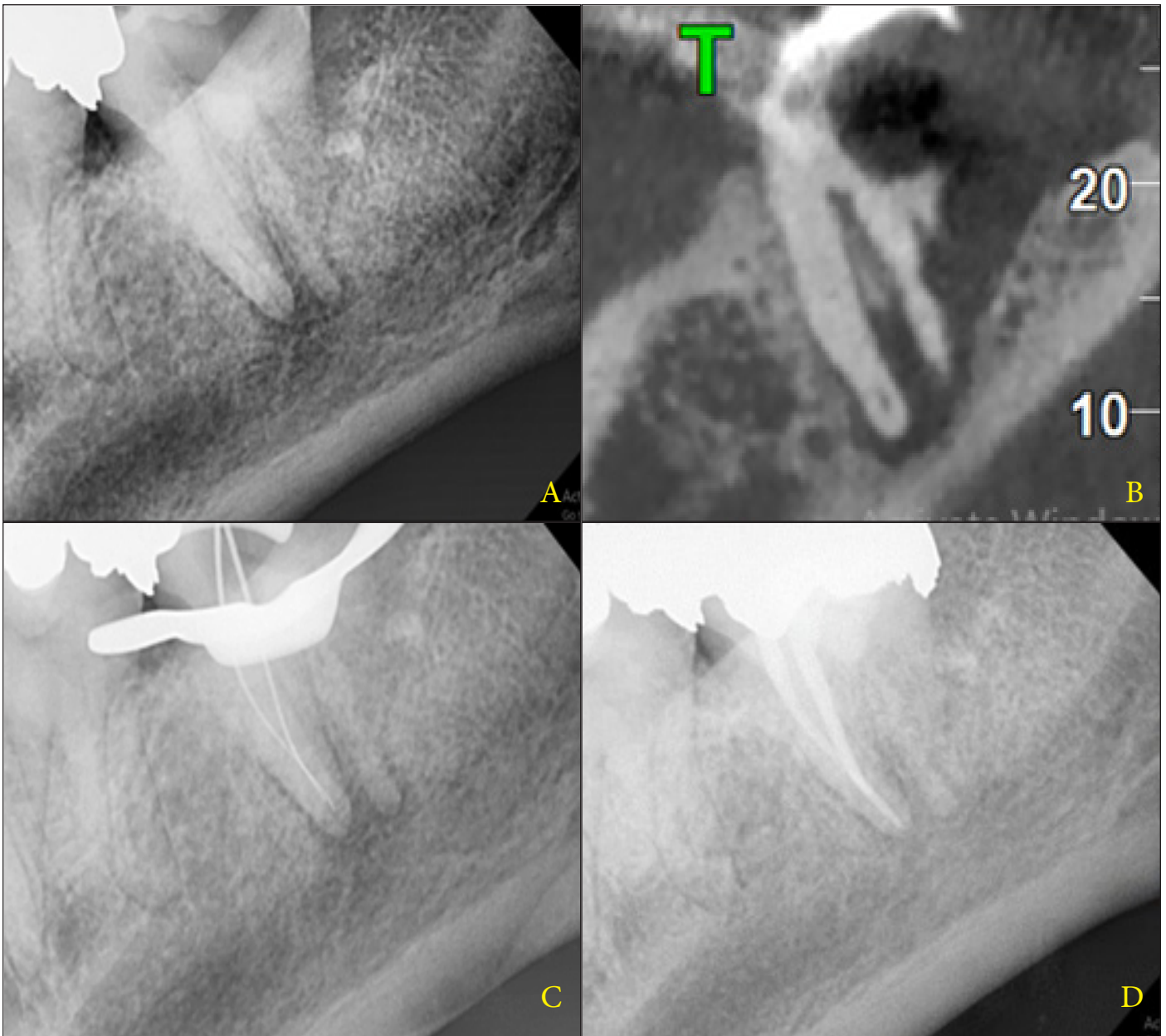


Fig. 1. A) Periapical radiograph of tooth #18 showing extensive root resorption around the distal root of the tooth following extraction of tooth #17. B) Computed tomography images show that about half of the distal root of tooth #18 was affected by tooth #17. C) Initial file was placed in mesial canals. D) One year follow-up radiograph

Conclusion

The present case demonstrates the successful RCT of the second molar with severe distal root resorption caused by the pressure of a neighboring wisdom tooth. CBCT should be used to provide better evaluation of these cases. And with proper

disinfection protocols and proper endodontic plan and treatment, such teeth can be given a chance to survive.

Conflict of Interest

The authors declare that there is no conflict of interest.

References

- Ahangari Z, Nasser M, Mahdian M, Fedorowicz Z, Marchesan MA. Interventions for the management of external root resorption. *Cochrane Database Syst Rev.* 2015;(11):1-11.
- Chen Y, Huang Y, Deng X. External cervical resorption—a review of pathogenesis and potential predisposing factors. *Int J Oral Sci.* 2021;13(1):1-10.
- Ericson S, Bjerklín K, Falahat B. Does the canine dental follicle cause resorption of permanent incisor roots? A computed tomographic study of erupting maxillary canines. *Angle Orthod.* 2002;72(2):95-104.
- Yamaoka M, Furusawa K, Ikeda M, Hasegawa T. Root resorption of mandibular second molar teeth associated with the presence of the third molars. *Aust Dent J.* 1999;44(2):112-116.
- Oenning ACC, Melo SLS, Groppo FC, Haiter-Neto F. Mesial inclination of impacted third molars and its propensity to stimulate external root resorption in second molars—a cone-beam computed tomographic evaluation. *J Maxillofac Oral Surg.* 2015;73(3):379-386.
- Creanga AG, Geha H, Sankar V, Teixeira FB, McMahan CA, Noujeim M. Accuracy of digital periapical radiography and cone-beam computed tomography in detecting external rootresorption. *Imaging Sci Dent.* 2015;45(3):153-158.
- Chen P-Y, Peng C-Y, Chen Y-T, Chiu Y-W, Lu M-Y. External Root Resorption Caused by Completely Impacted Teeth-Report of Three Cases. *Journal of Taiwan Society of Oral and Maxillofacial Surgery.* 2019;30(3):198-207.
- Oenning ACC, Neves FS, Alencar PNB, Prado RF, Groppo FC, Haiter-Neto F. External root resorption of the second molar associated with third molar impaction: comparison of panoramic radiography and cone beam computed tomography. *J Maxillofac Surg.* 2014;72(8):1444-1455.
- Alassiry AM, Hakami Z. Root Resorption of Adjacent Teeth Associated with Maxillary Canine Impaction in the Saudi Arabian Population: A Cross-Sectional Cone-Beam Computed Tomography Study. *Appl. Sci.* 2021;12(1):334.
- Wang D, He X, Wang Y, Li Z, Zhu Y, Sun C, et al. External root resorption of the second molar associated with mesially and horizontally impacted mandibular third molar: evidence from cone beam computed tomography. *Clin Oral Investig.* 2017;21(4):1335-1342.
- Sakhdari S, Farahani S, Asnaashari E, Marjani S. Frequency and Severity of Second Molar External Root Resorption Due to the Adjacent Third Molar and Related Factors: A Cone-Beam Computed Tomography Study. *Frontiers in Dentistry.* 2021;18(36):1-7.
- Mercier P, Precious D. Risks and benefits of removal of impacted third molars: a critical review of the literature. *Int J Oral Maxillofac Surg.* 1992;21(1):17-27.
- Nemcovsky CE, Libfeld H, Zubery Y. Effect of non erupted 3rd molars on distal roots and supporting structures of approximal teeth A radiographic survey of 202 cases. *J Clin Periodontol.* 1996;23(9):810-815.
- Li D, Tao Y, Cui M, Zhang W, Zhang X, Hu X. External root resorption in maxillary and mandibular second molars associated with impacted third molars: a cone-beam computed tomographic study. *Clin Oral Investig.* 2019;23(12):4195-4203.
- Dogramaci EJ, Sherriff M, Rossi-Fedele G, McDonald F. Location and severity of root resorption related to impacted maxillary canines: a cone beam computed tomography (CBCT) evaluation. *Aust Orthod J.* 2015;31(1):49-58.
- Almuhtaseb E, Mao J, Mahony D, Bader R, Zhang Z-x. Three-dimensional localization of impacted canines and root resorption assessment using cone beam computed tomography. *J Huazhong Univ Sci Technolog Med Sci.* 2014;34(3):425-430.
- Estrela C, Bueno MR, De Alencar AHG, Mattar R, Neto JV, Azevedo BC, et al. Method to evaluate inflammatory root resorption by using cone beam computed tomography. *J Endod.* 2009;35(11):1491-1497.
- Walker L, Enciso R, Mah J. Three-dimensional localization of maxillary canines with cone-beam computed tomography. *Am J Orthod Dentofacial Orthop.* 2005;128(4):418-423.

19. Strobel S, Lenhart E, Woelber JP, Fleiner J, Hannig C, Wrbas K-T. Comparison of two cone-beam computed tomography systems in the visualization of endodontic structures. *Swiss Dent J*. 2017;127(3):221-229.
20. Kang F, Huang C, Sah MK, Jiang B. Effect of eruption status of the mandibular third molar on distal caries in the adjacent second molar. *J Maxillofac Oral Surg*. 2016;74(4):684-692.
21. Aravelli S, Soujanya E, Chandrasekhar V. Extensive external localized idiopathic root resorption—An unusual case report. *J Conserv Dent*. 2019;22(5):500-502.
22. Kang S, Kim E. Pressure Root Resorption of the Second Molar Caused by Third Molar Impaction: A Case Report of Severely Resorbed Root with Vital Pulp. *Journal of Korean Dental Science*. 2016;9(2):63-68.
23. Bolhari B, Meraji N, Nosrat A. Extensive idiopathic external root resorption in first maxillary molar: a case report. *Iran Endod J*. 2013;8(2):72-74.
24. Moghadam MD, Saberi EA, Molashahi NF, Ebrahimi HS. Comparative efficacy of Depotphoresis and diode laser for reduction of microbial load and postoperative pain, and healing of periapical lesions: a randomized clinical trial. *G Ital Endod*. 2021;35(2):75-87.
25. Nagendrababu V, Chong B, McCabe P, Shah P, Priya E, Jayaraman J, et al. PRICE 2020 guidelines for reporting case reports in Endodontics: a consensus based development. *Int Endod J*. 2020;53(5):619-626.